

The Liver

Prof. Oluwadiya KS

www.oluwadiya.com

Introduction

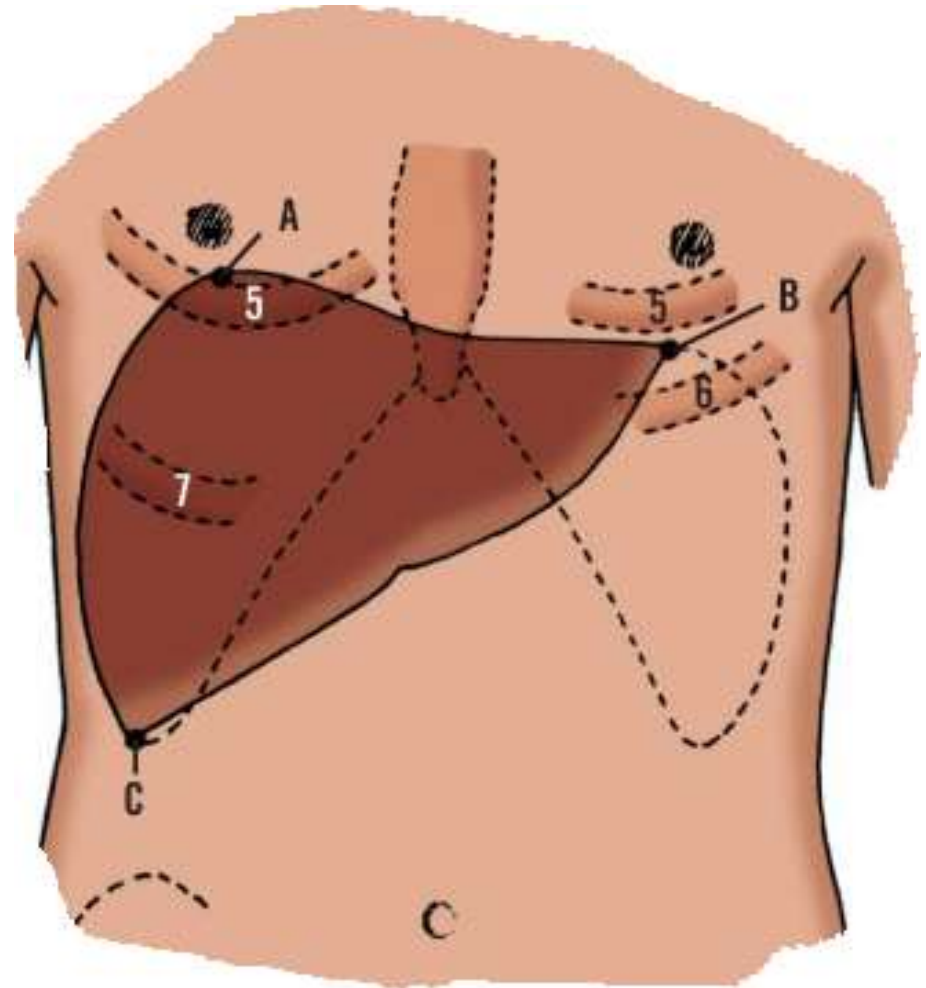
- The human liver is the largest solid organ in the body.
- The weight of the liver of the adult male ranges from 1.4 kg to 1.8 kg
- The weight in adult females ranged from 1.2 kg to 1.4 kg.
- Average is about 1.5 kg
- Its average transverse diameter is 20 cm to 23 cm (right-left)
- Its anteroposterior diameter is 10 cm to 12.5 cm

The Liver: Location and Extent

- The liver fills the right hypochondrium and most of the epigastric regions.
- It extends inferiorly into the right lumbar region and occupies part of the left hypochondrium
- The liver is covered by ribs and costal cartilages, except in the epigastric region where it reaches the anterior abdominal wall just below the infrasternal notch

The Liver: Surface marking

- **Point A** is 1 cm below the right nipple at the level of the fifth rib
- **Point B** is located approximately 2 cm inferior to and medial to the left nipple, at the level of the left fifth intercostal space
- **Point C** is in the right costal margin at the anterior axillary line



The liver and the gall bladder

- The gallbladder attaches to the visceral surface of the liver and moves with it.
- The fundus usually projects below the liver margin and lies in contact with the anterior abdominal wall near the intersection of the ninth costal cartilage and the lateral border of the rectus sheath

The Shape and Surfaces of the liver

- The liver is wedge-shaped.

It has two surfaces:

- **Diaphragmatic surface** in the anterior, superior, and posterior direction. It is smooth, rounded and generally convex in shape
- **Visceral surface** in the inferior direction. It is concave in shape
- The liver is closely applied to the surrounding viscera:
 - The diaphragmatic surface is molded by the diaphragm.
 - The visceral surface bears impressions from the stomach, duodenum, transverse colon, and the right kidney.

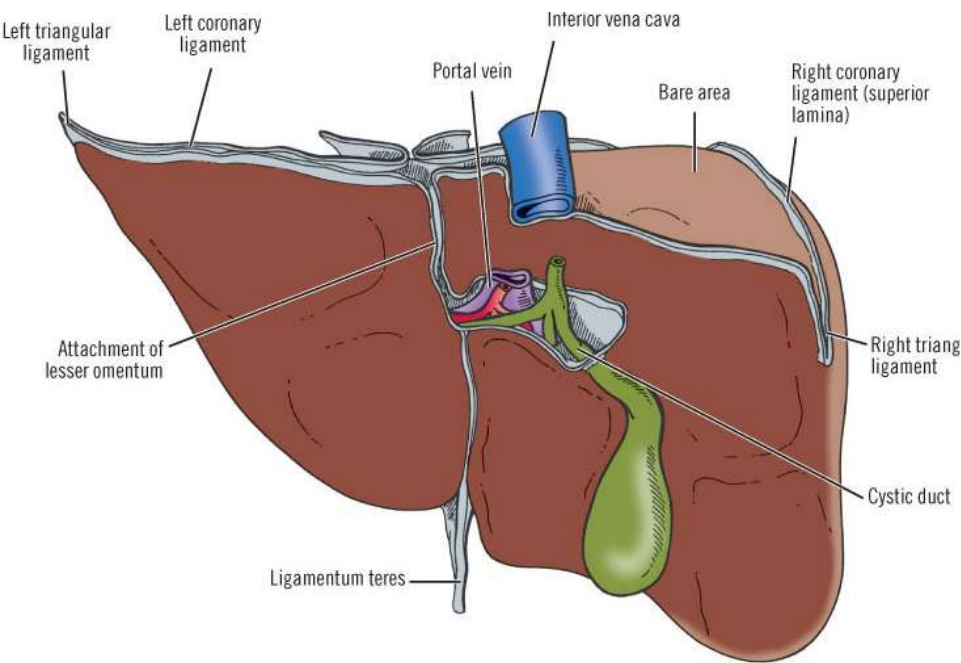
Diaphragmatic Surface

- The diaphragmatic surface may be divided into four parts:
 - i. **Superior:** related to the diaphragm
 - ii. **Posterior:** related to the diaphragm and lower ribs
 - iii. **Anterior:** related to the diaphragm and costal margin, xiphoid process, the abdominal wall, and the sixth to tenth ribs on the right.
 - iv. **Right :**diaphragm and the seventh to eleventh ribs. It is a lateral continuation of the posterior portion

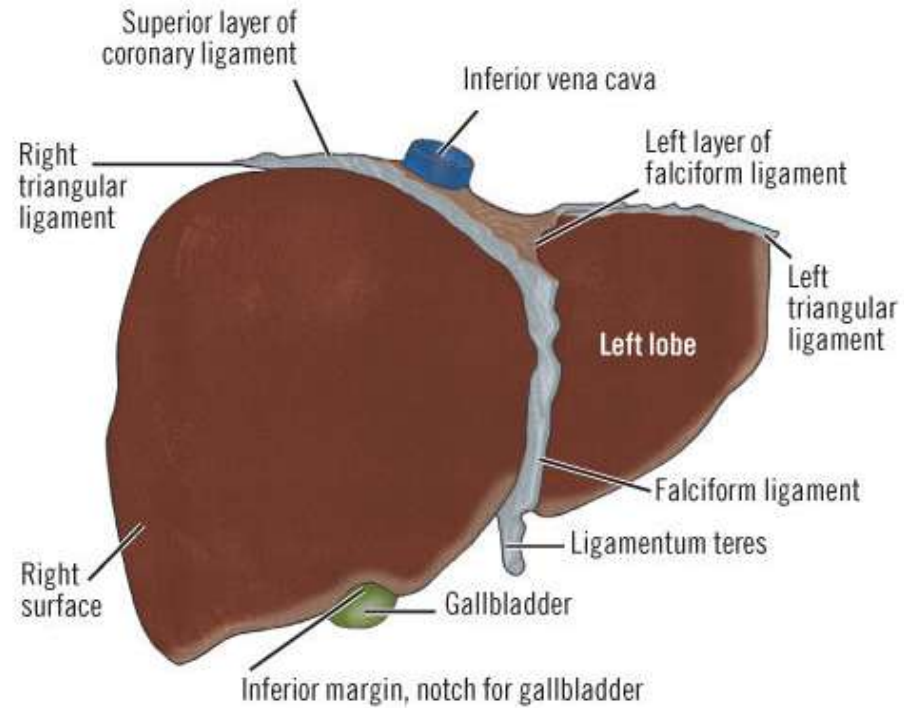
Inferior Border

- This separates the diaphragmatic surface from the visceral surface
- The border is blunt, rounded, and unmarked posteriorly but sharp anteriorly.
- Anteriorly, the inferior border of the liver is marked by two notches to the right of the median plane. These are:
 - i. Deep notch accommodating the ligamentum teres
 - ii. Shallow notch allowing space for the gallbladder

Visceral surface

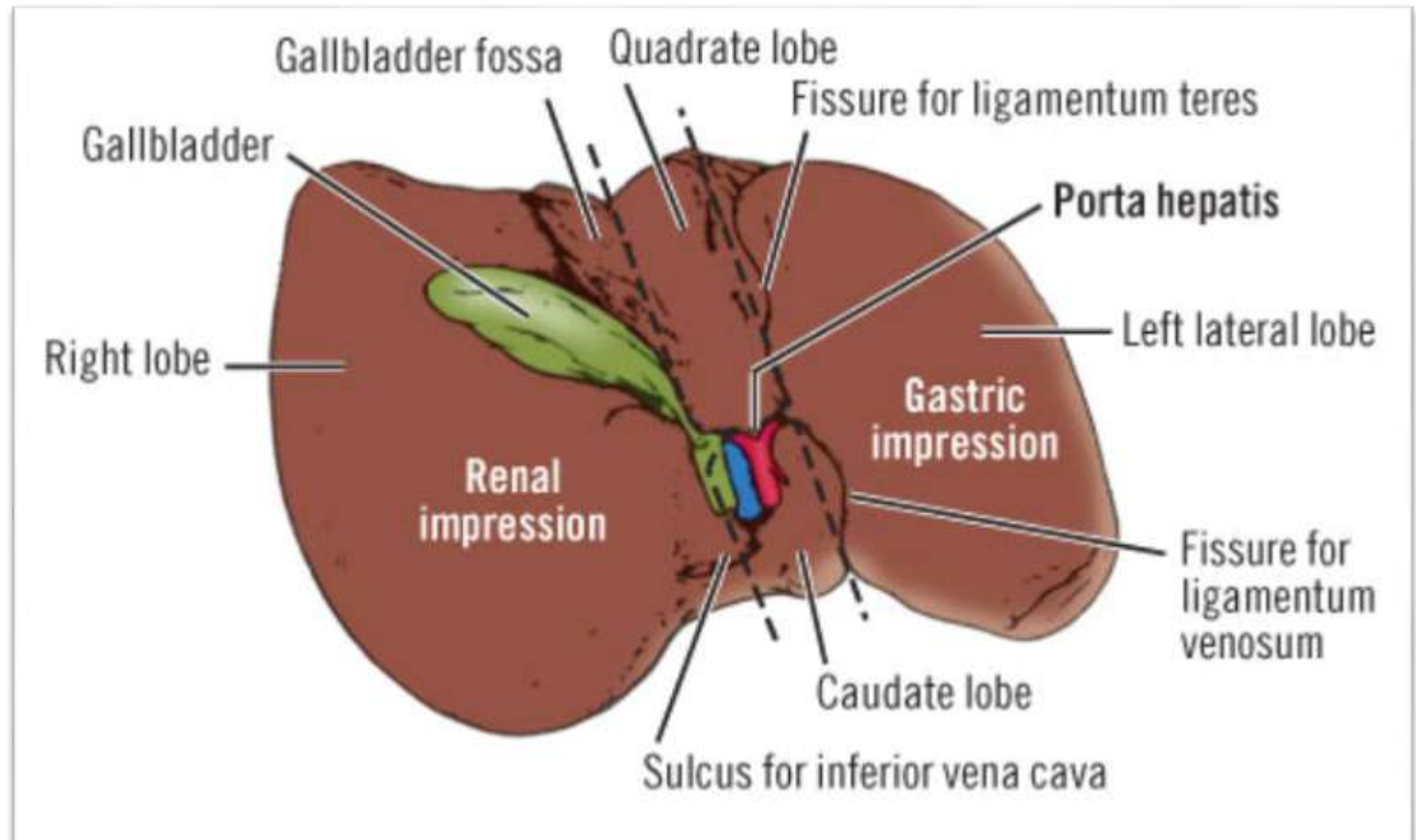


Diaphragmatic surface



Visceral surface of the liver

- Concave in form
- Has distinct impressions from adjacent organs
- Also contains the porta hepatis; the gateway to the liver.



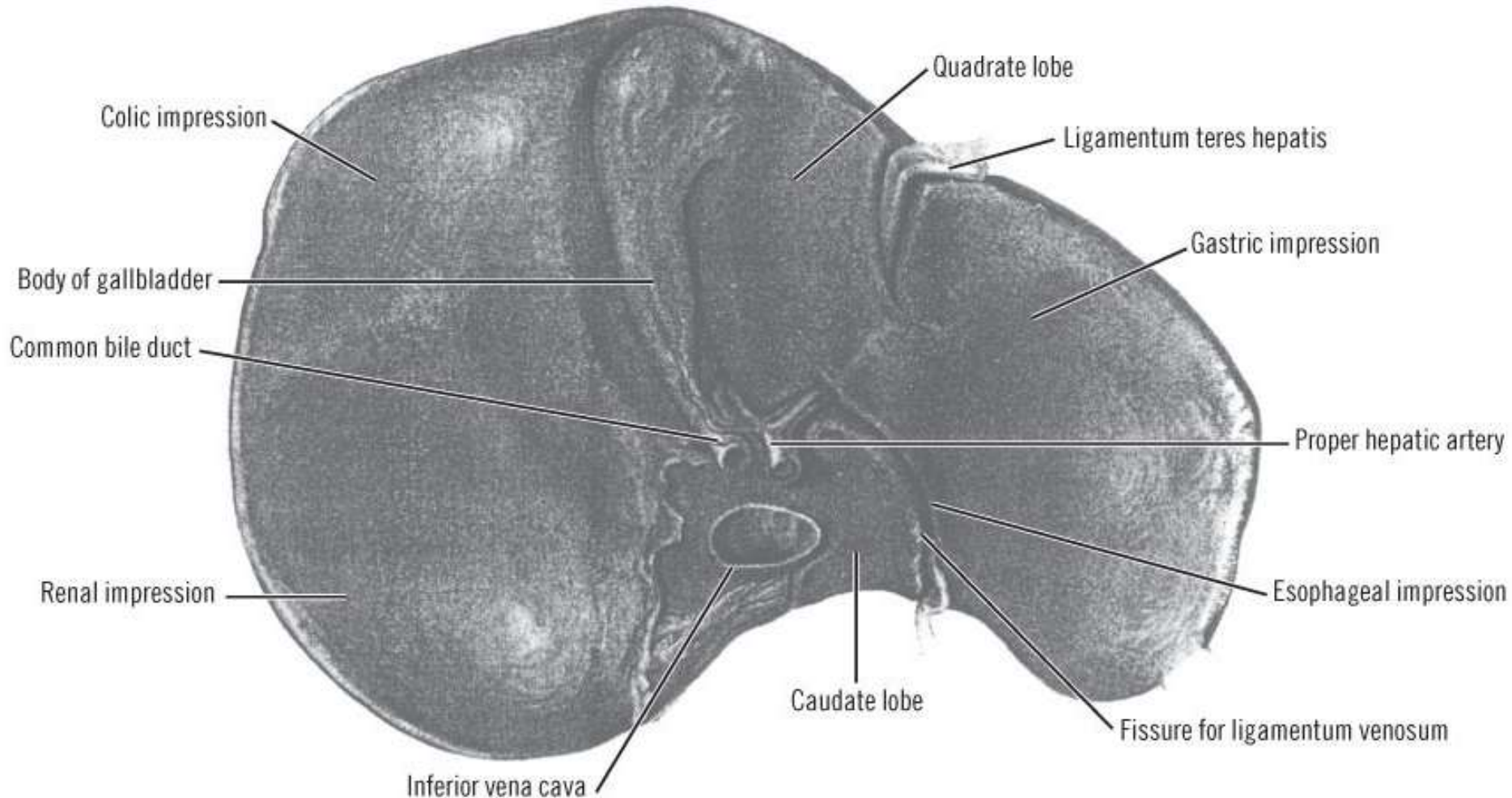
Visceral surface: Borders of the Porta

- The porta hepatis and its borders are roughly H-shaped
- The **right limb** of the "H" is formed anteriorly by the fossa for the gallbladder and posteriorly by the fossa for the inferior vena cava.
- The **left limb** is formed anteriorly by the fissure for the round ligament and posteriorly by the fissure for the ligamentum venosum.
- The **crossbar** of the "H" is the porta hepatis
- Posterior to the crossbar is the caudate lobe
- Anterior to the crossbar is the quadrate lobe.

Visceral surface: Related organs

- i. The right anterior part of the stomach
- ii. The superior part of the duodenum
- iii. The lesser omentum
- iv. The gallbladder
- v. The right colic flexure
- vi. The right part of the transverse colon
- vii. The right kidney
- viii. The right suprarenal gland.

Visceral surface: Impressions



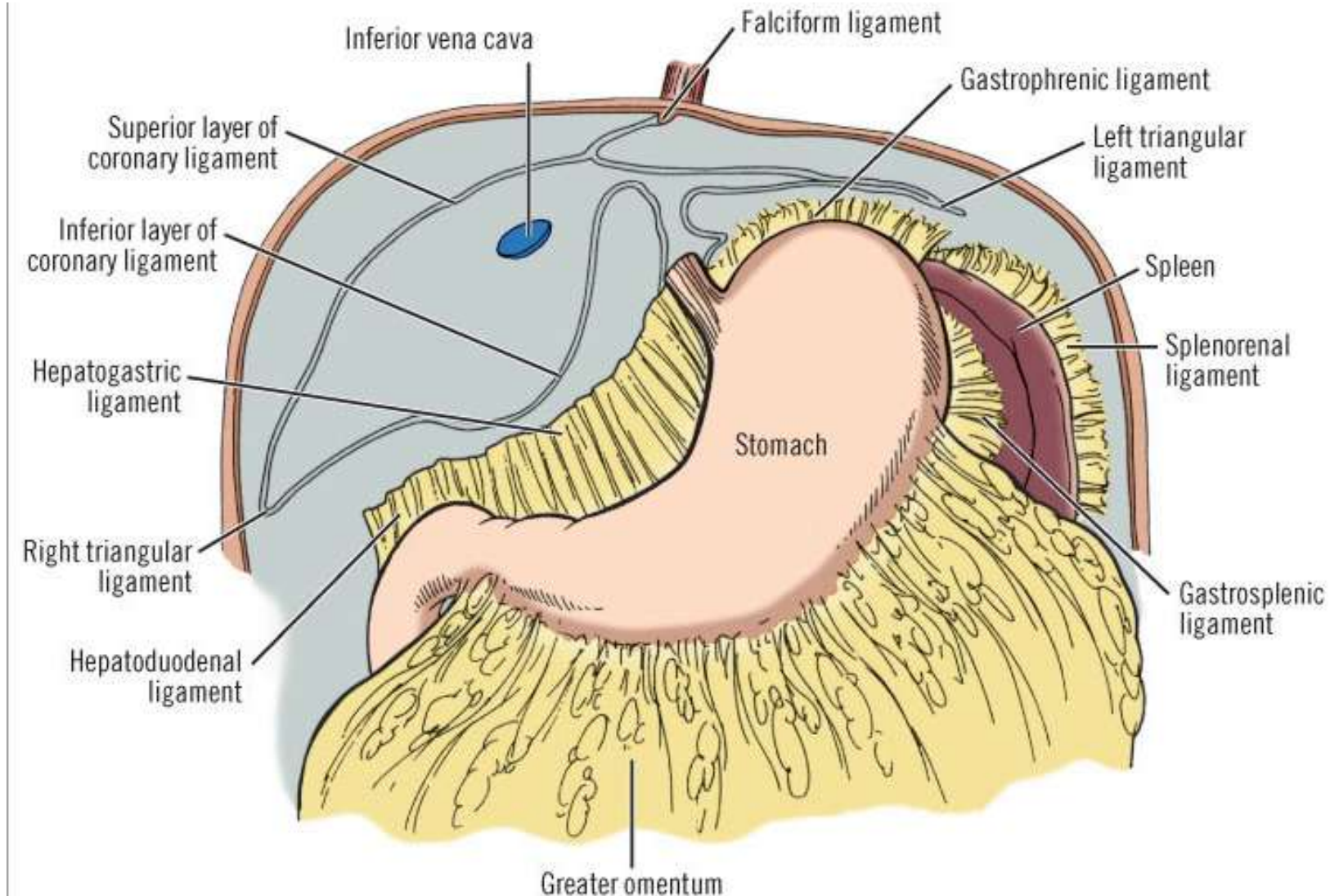
Ligaments of the liver

- These are not really ligaments, but are reflections of peritoneum between the liver and surrounding organs especially the diaphragm, the stomach and the duodenum.
 - **Stomach** : Hepatogastric ligament
 - **Duodenum**: Hepatoduodenal ligament
 - **The Diaphragm**:
 - i. Falciform ligament
 - ii. Left triangular ligament
 - iii. Right triangular ligament &
 - iv. Coronary ligaments which is only found on the right
- These four peritoneal reflections (ligaments) surround the **bare area** of the diaphragm

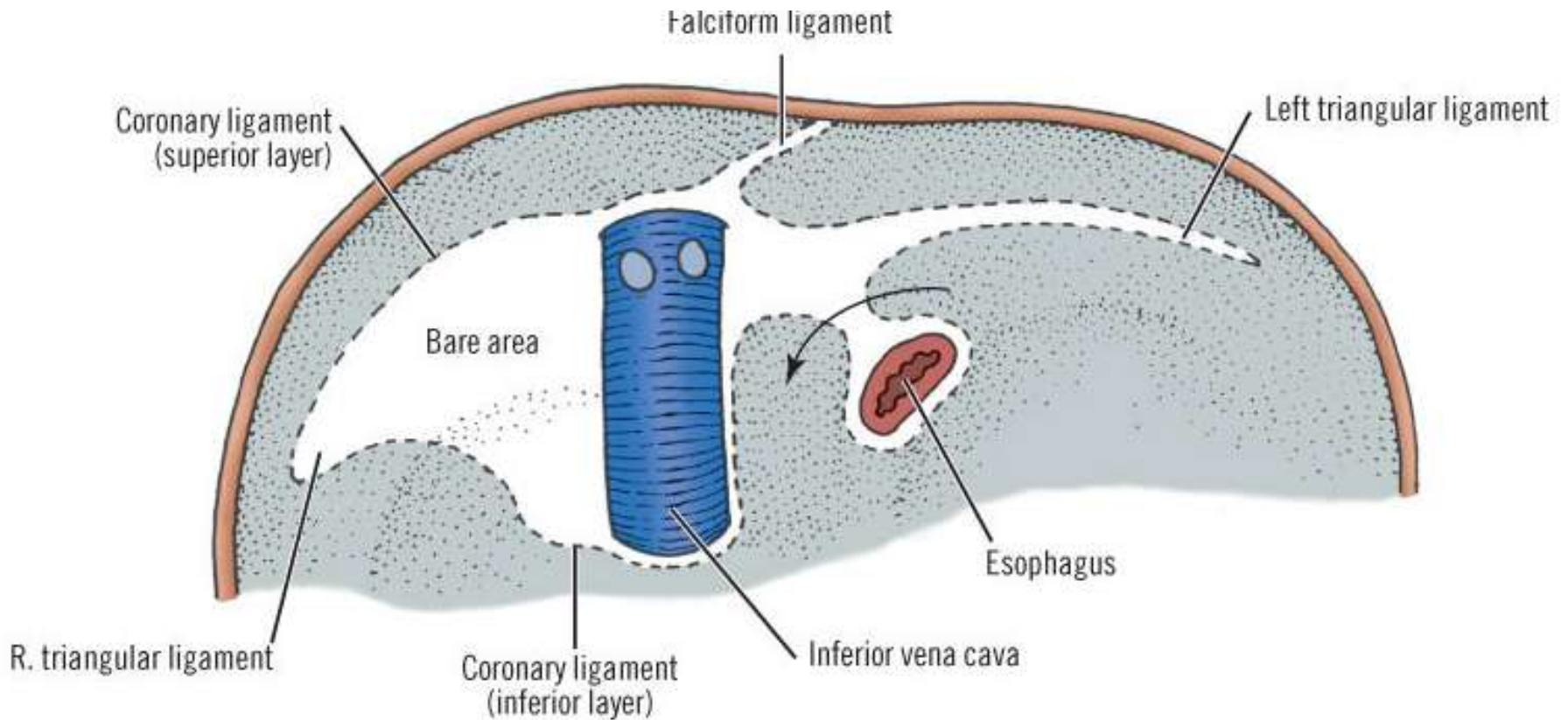
Ligaments of the liver

- The bare area of the liver is a part of the liver on the diaphragmatic surface where there is no intervening peritoneum between the liver and the diaphragm
- The **anterior** boundary of the bare area is the superior layer of the coronary ligament
- The **posterior** boundary of the bare area is the inferior coronary ligament
- Where the coronary ligaments come together laterally, they form the right and left triangular ligaments.

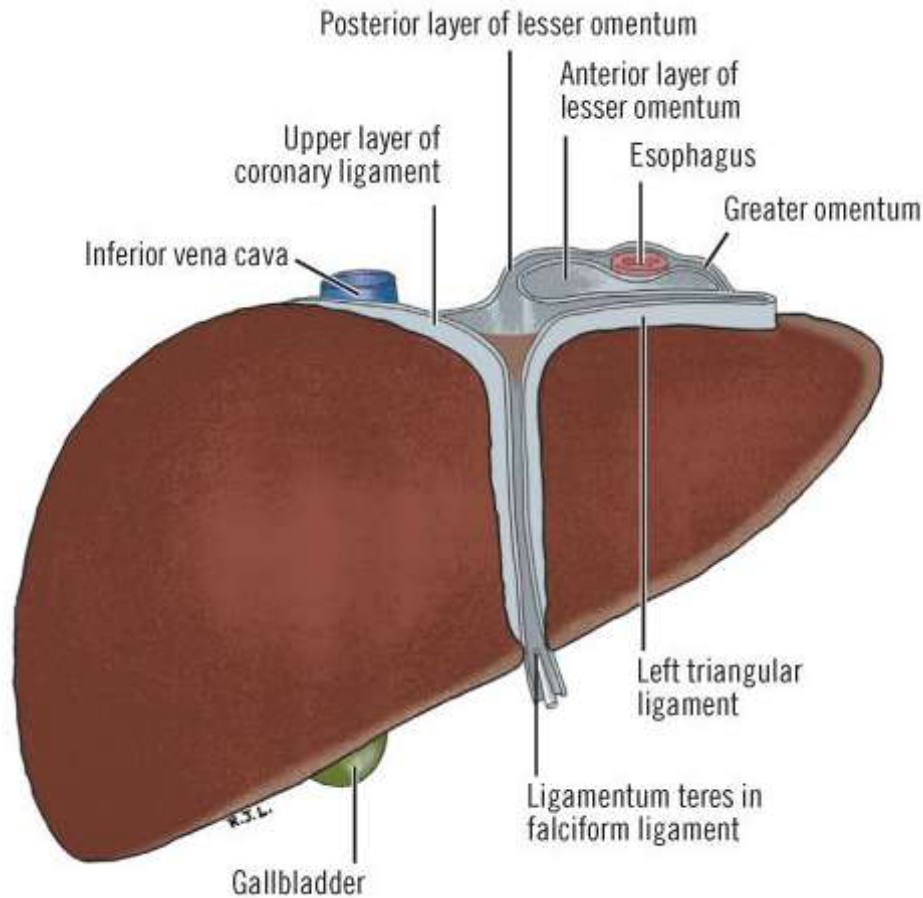
The bare area of the diaphragm



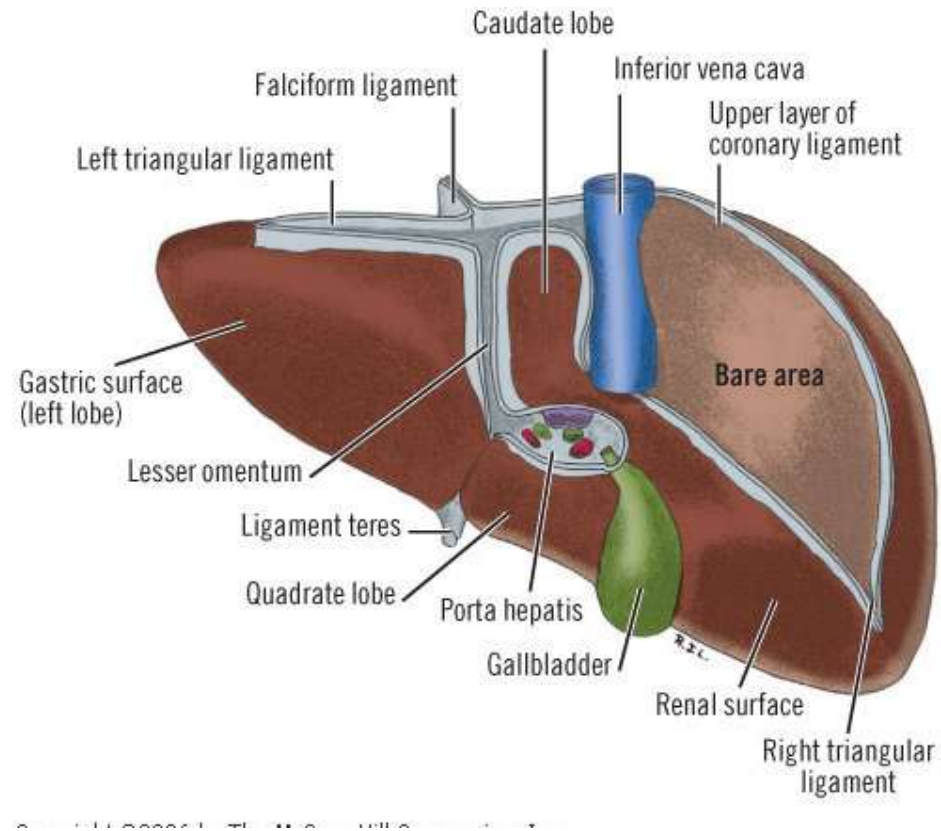
The bare area of the diaphragm



Liver: Anterior & Posterior views



Anterior View



Posterior View

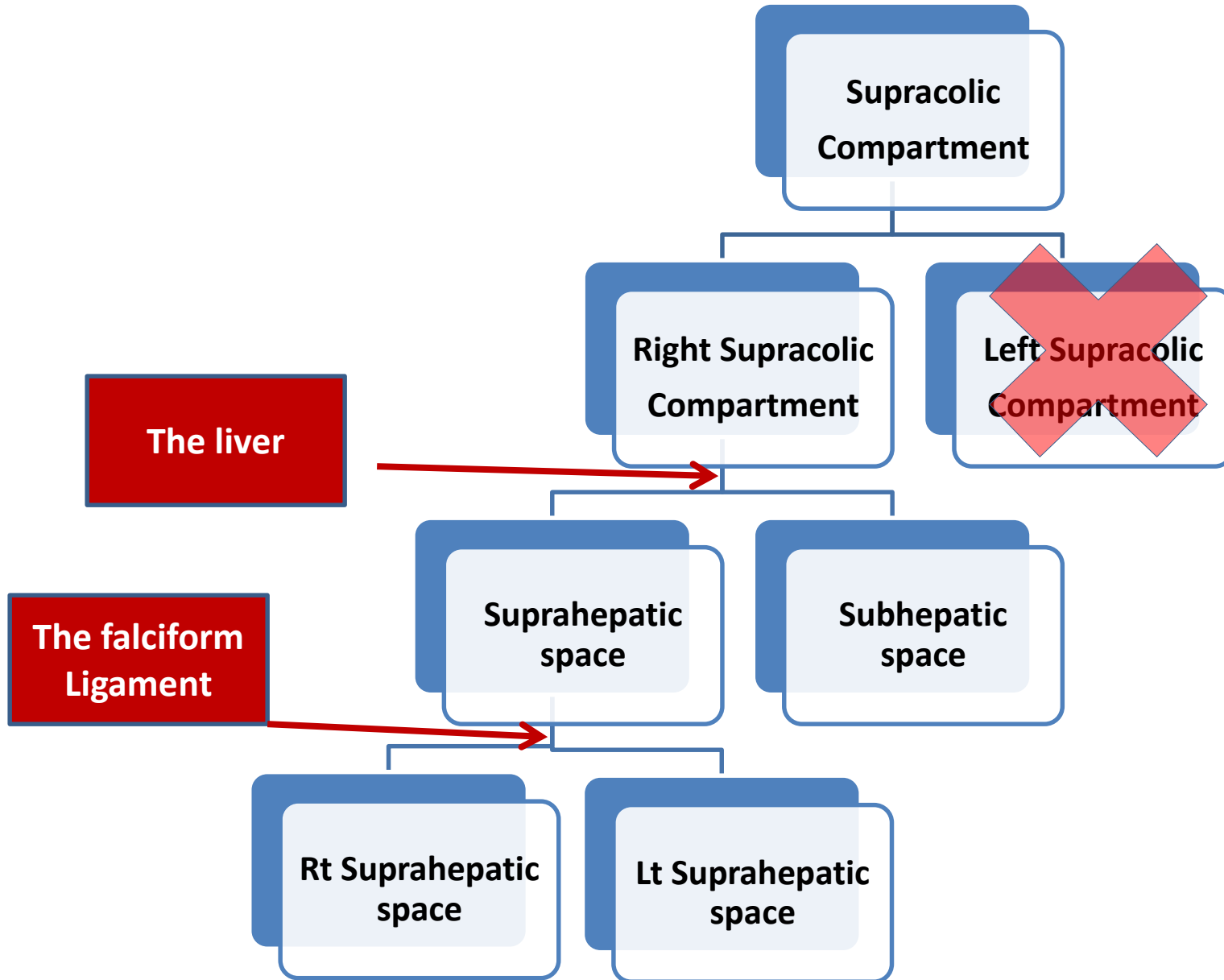
Falciform Ligament

- The anterior surface of the liver is covered entirely by peritoneum except at attachment of the falciform ligament
- It extends from the anterior surface of the liver to the diaphragm and the anterior abdominal wall and is at a variable distance to the right of the midline.
- It contains the ligamentum teres which is the obliterated left umbilical vein.
- The ligamentum teres may be accompanied by one or more paraumbilical veins in the adult.

Falciform Ligament

- The left leaf of the falciform ligament continues laterally where, superiorly, it becomes the left triangular ligament
- The right leaf of the falciform ligament diverges at the superior aspect of the liver successively forming
 - i. the anterior (superior) layer of the coronary ligament
 - ii. right triangular ligament, and
 - iii. Posterior (inferior) layer of the coronary ligament

Perihepatic spaces

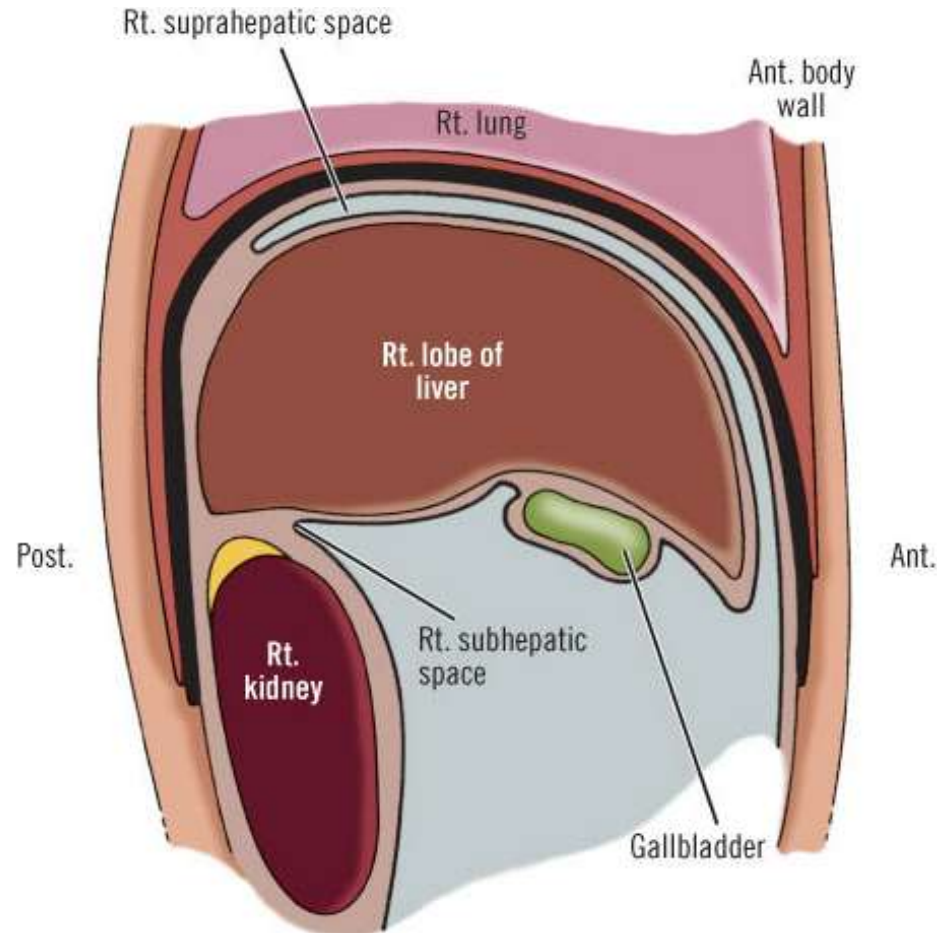


Suprahepatic space

- Also known as subphrenic space
- This is the potential space between the diaphragm and the liver
- Divided into right and left suprahepatic spaces by the falciform ligament

- Lies between the diaphragm and the anterosuperior surface of the right lobe and the medial segment of the left lobe of the liver.
- The boundaries are:
 - **Left** — falciform ligament
 - **Posterior** —superior (anterior) coronary and right triangular ligaments
 - **Inferior (Floor)**— right lobe and medial segment of the left lobe of the liver
 - The space opens into the general peritoneal cavity anteriorly

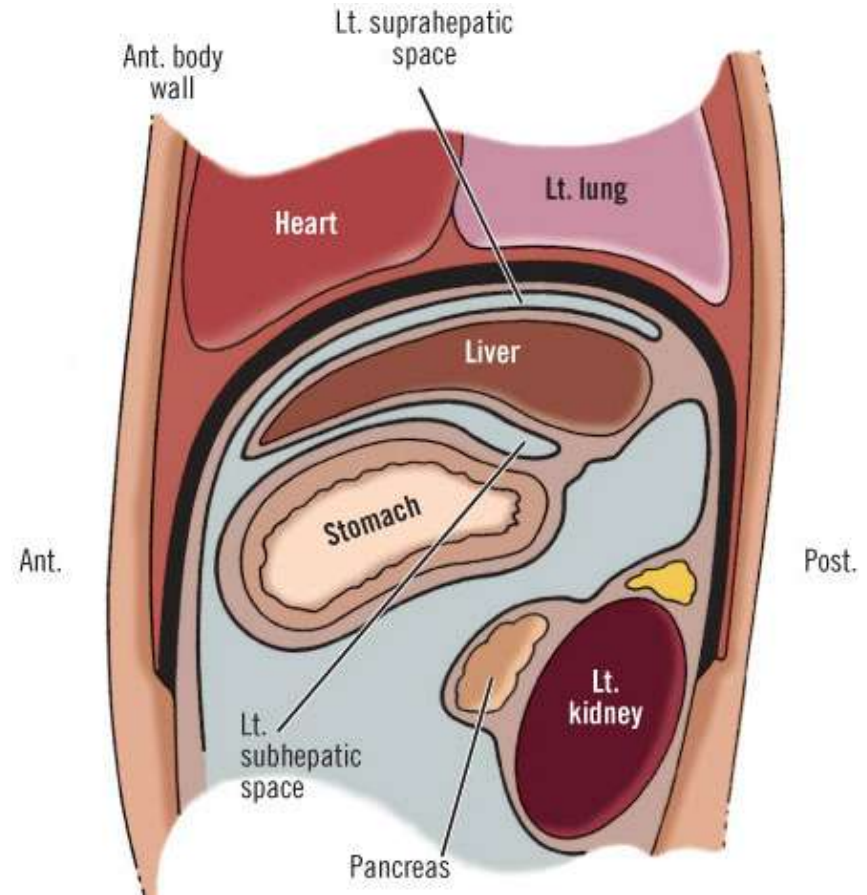
The right suprahepatic space



- Between the diaphragm and the superior surface of the lateral segment of the left lobe of the liver and the fundus of the stomach.

The left suprahepatic space

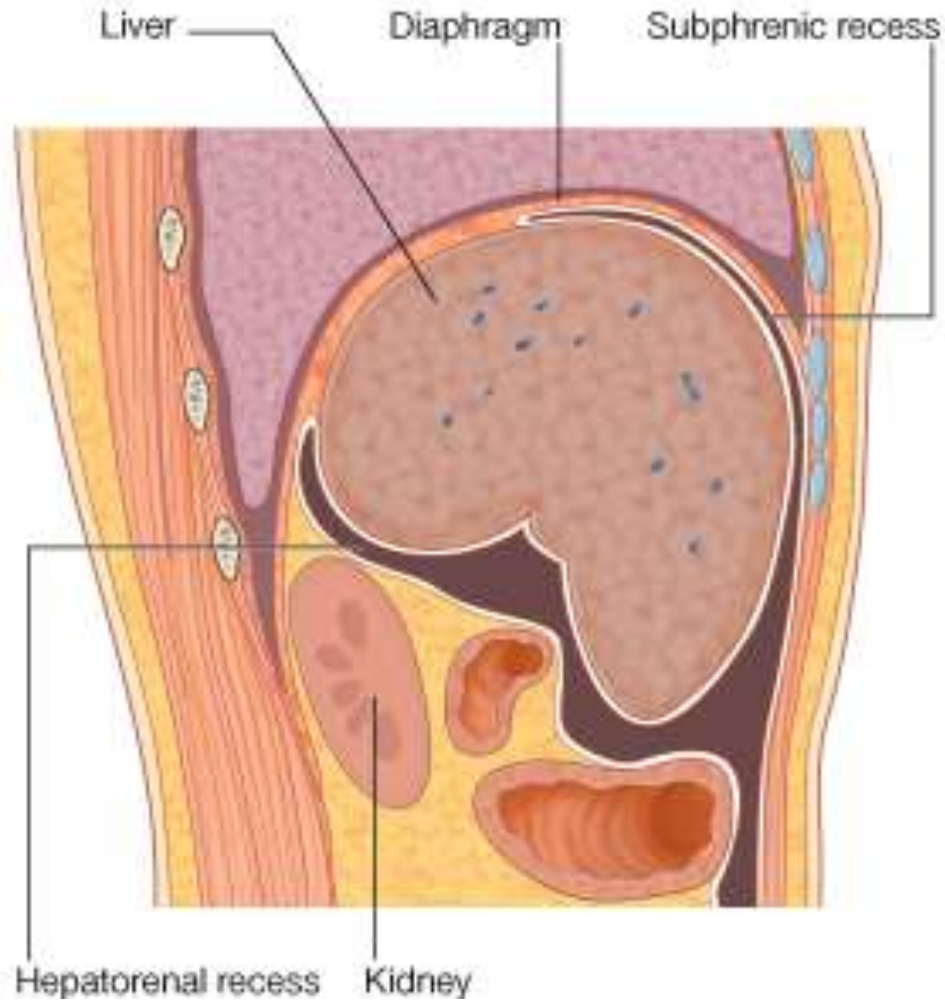
- The boundaries are:
 - **Right:** falciform ligament
 - **Posterior:** left triangular ligament.
 - Anteriorly and laterally the space communicates with the infrahepatic space and the general peritoneal cavity



The subhepatic space

- Also called infrahepatic space, hepatorenal space, pouch of Morison
- Bounded superiorly and anteriorly by
 - The right lobe
 - Medial segment of the left lobe of the liver and
 - The gallbladder
- It is limited superiorly and posteriorly by the posterior (inferior) layer of the coronary ligament and the right triangular ligament
- Inferiorly, the space opens into the general peritoneal cavity
- Communicates with right suprahepatic (subphrenic) space around the margin of the right lobe of the liver

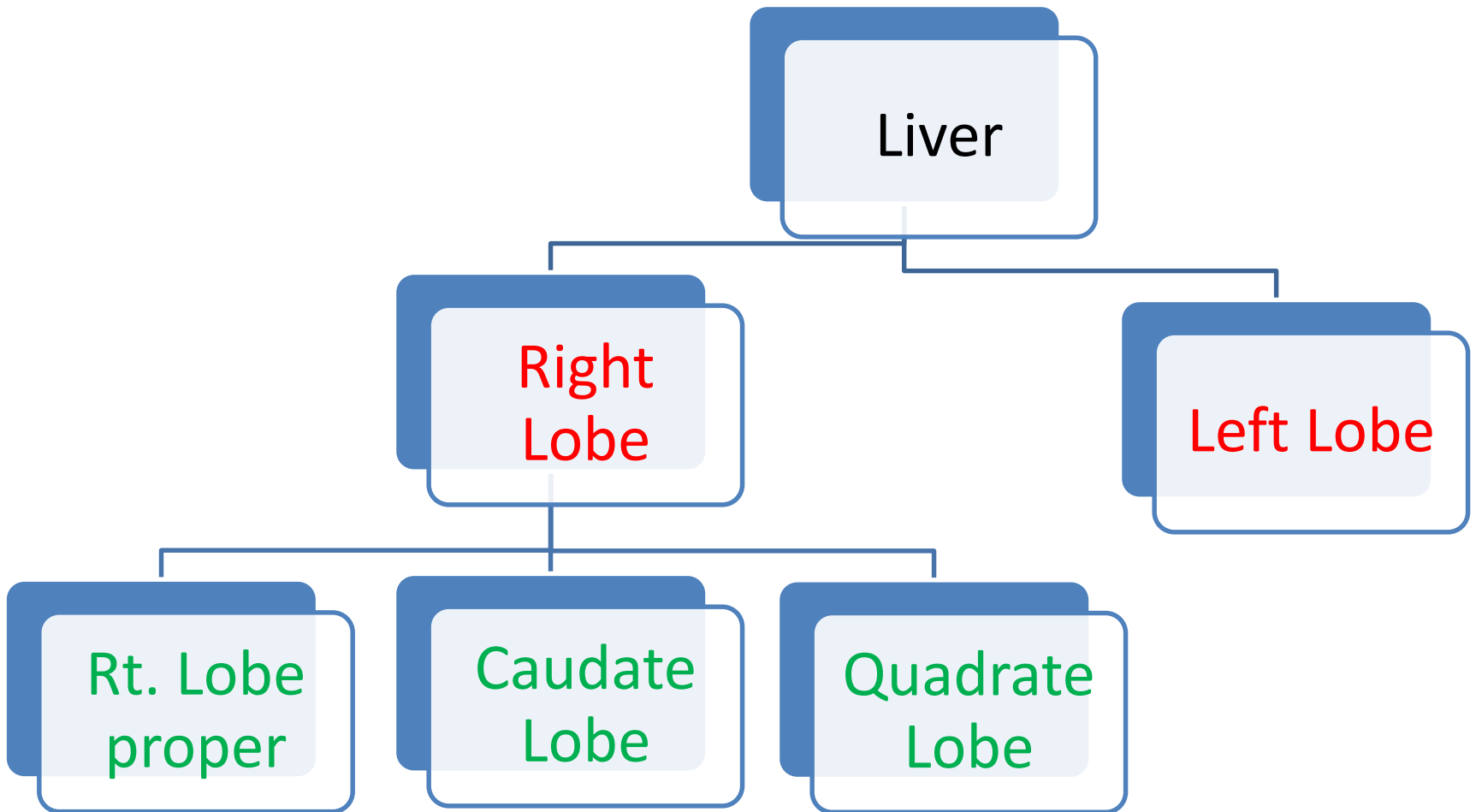
The subhepatic space



Lobes of the liver

- There are two major ways by which the liver is divided into lobes:
- **Anatomical Division:** 4 lobes made of two major lobes (right and left) and 2 accessory lobes (Quadrante and Caudate)
- **Functional Division:** This division is based on the distribution of the branches of the portal vein, hepatic artery and the bile duct. There are eight such hepatic segments or lobules

Anatomical lobes



Anatomical lobes

- On first inspection, the liver appears to be divided into a large right portion and a much smaller left portion.
- The apparent plane of division (left fissure) passes through the falciform ligament, the round ligament, and the ligamentum venosum.
- Unfortunately, this apparent division does not correspond to the internal distribution of bile ducts and blood vessels and is functionally useless

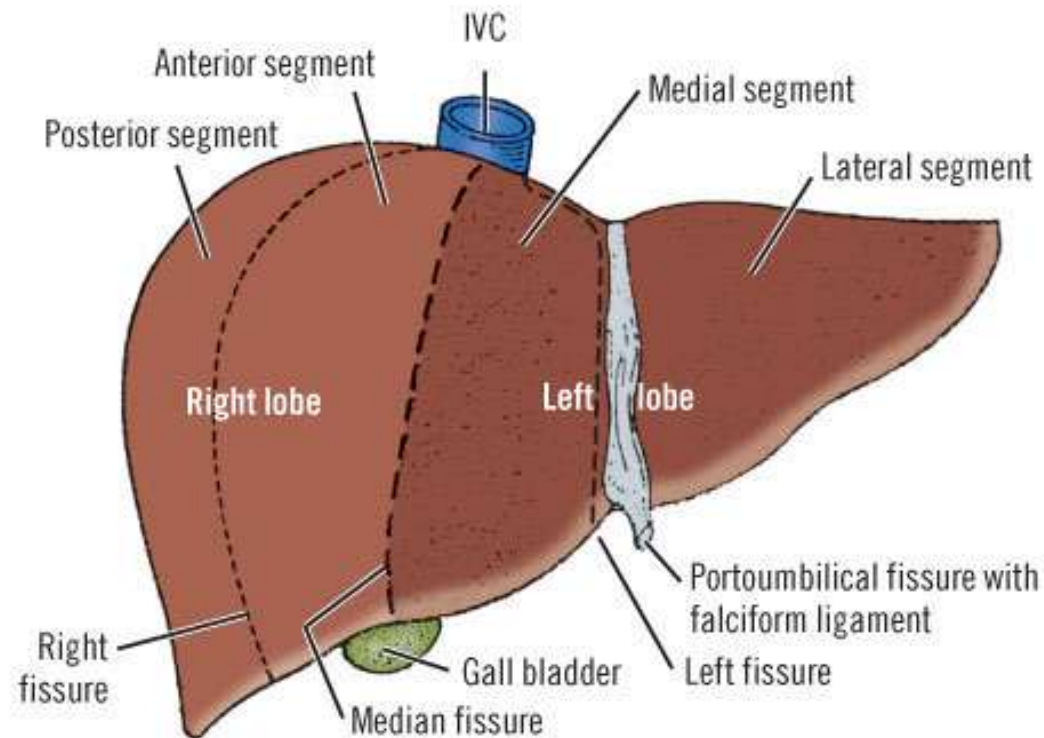
Anatomical lobes

- The **quadrate lobe** is visible on the anterior part of the visceral surface of the liver and is bounded on the left by the fissure for ligamentum teres and on the right by the fossa for the gallbladder. Functionally it is related to the left lobe of the liver:
- the **caudate lobe** is visible on the posterior part of the visceral surface of the liver and is bounded on the left by the fissure for the ligamentum venosum and on the right by the groove for the inferior vena cava. Functionally, it is separate from the right and the left lobes of the liver.

Bases for divisions into functional lobes:

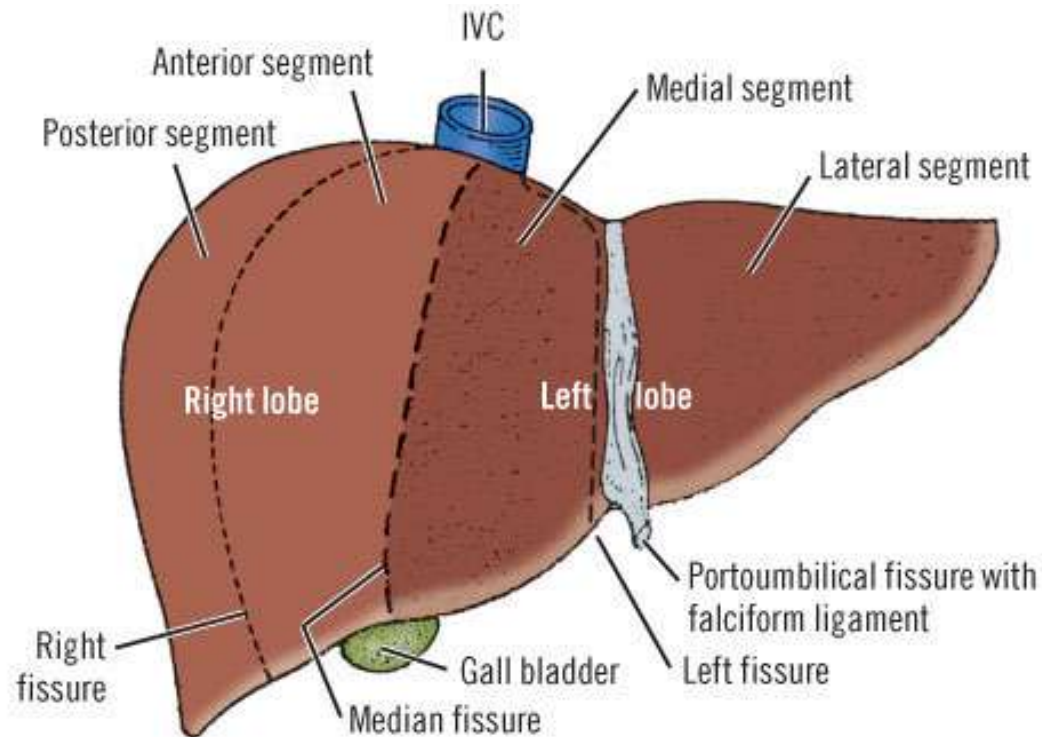
- Each functional lobe receives its own primary branch of the hepatic artery and portal vein and is drained by its own hepatic duct
- The presence of 3 fissures:
 - i. the **right**,
 - ii. **median** and
 - iii. **left** fissures
- Each segment is then divided into a superior and inferior subsegment

Functional lobes



Functional lobes

- The true right and left lobes of the liver are about the same size.
- These true lobes are separated by the median fissure that passes through the bed of the gallbladder below and the fossa of the inferior vena cava above



True Left Lobe

True left lobe

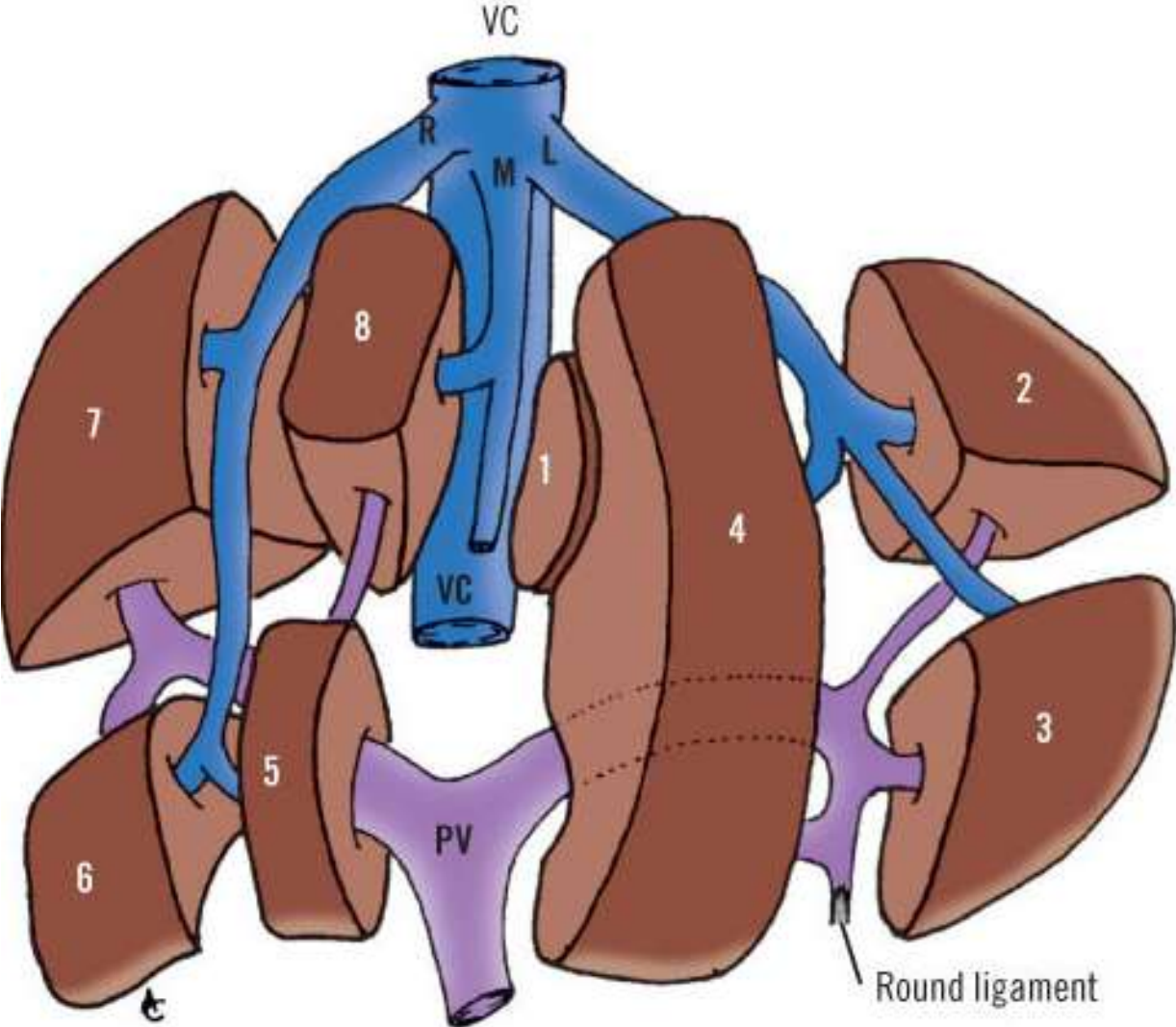
- Consists of a left medial segment and a left lateral segment . The two are separated by the left fissure
- The left lateral segment is the "left lobe" of anatomical description.
- The left medial segment consists of the quadrate and caudate lobes of the old anatomical description.
- Each of these two segments can be further divided into superior and inferior subsegments on the basis of the distribution of the bile ducts, hepatic arteries, and portal veins.

True Right Lobe

True Right lobe

- The true right lobe is divided by the right fissure into anterior (medial) and posterior (lateral) segments.
- The plane of this fissure corresponds to the line of the eighth intercostal space.
- Each segment of the right lobe can be subdivided into superior and inferior subsegments

Exploded diagram of the lobes

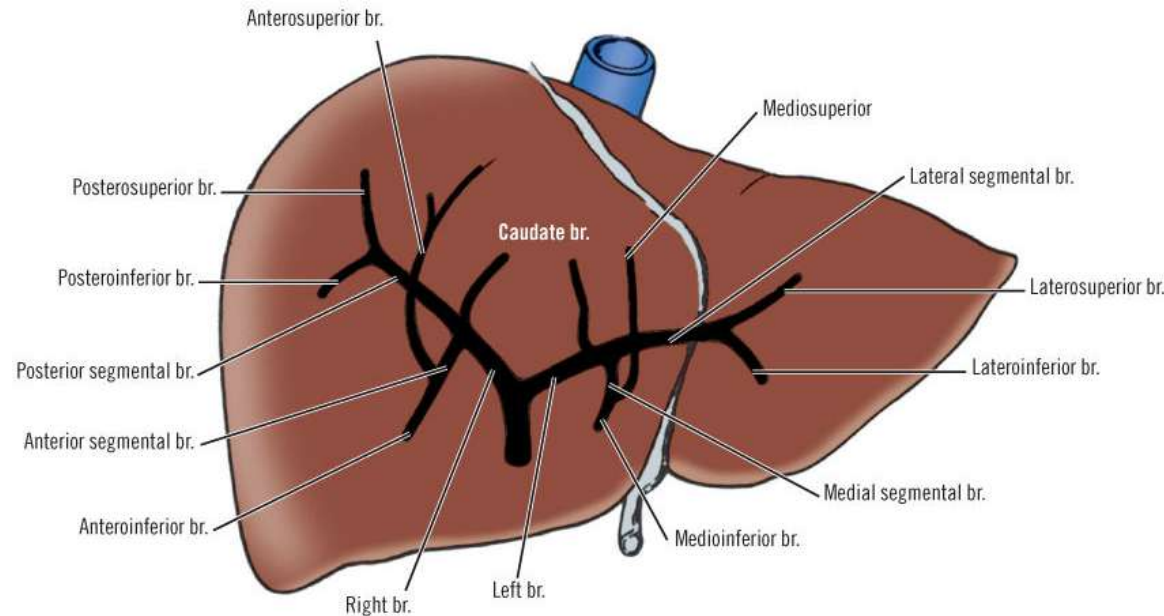


Liver blood supply

- The liver has dual blood supply:
 - i. Hepatic artery: supplies 25% of hepatic blood supply and is systemic
 - ii. Portal Vein: supplies the remaining 75%.
- Blood from these two sources mingles in the blood sinusoids of the liver parenchyma and is drained by tributaries of the hepatic veins. These veins open into the inferior vena cava.

Arterial supply

- This is the **Proper Hepatic Artery**, which is the continuation of the Common Hepatic Artery, after the latter has given off the gastroduodenal artery
- It divides into the **Rt & Lt Hepatic Arteries** which supply the right and left lobes respectively



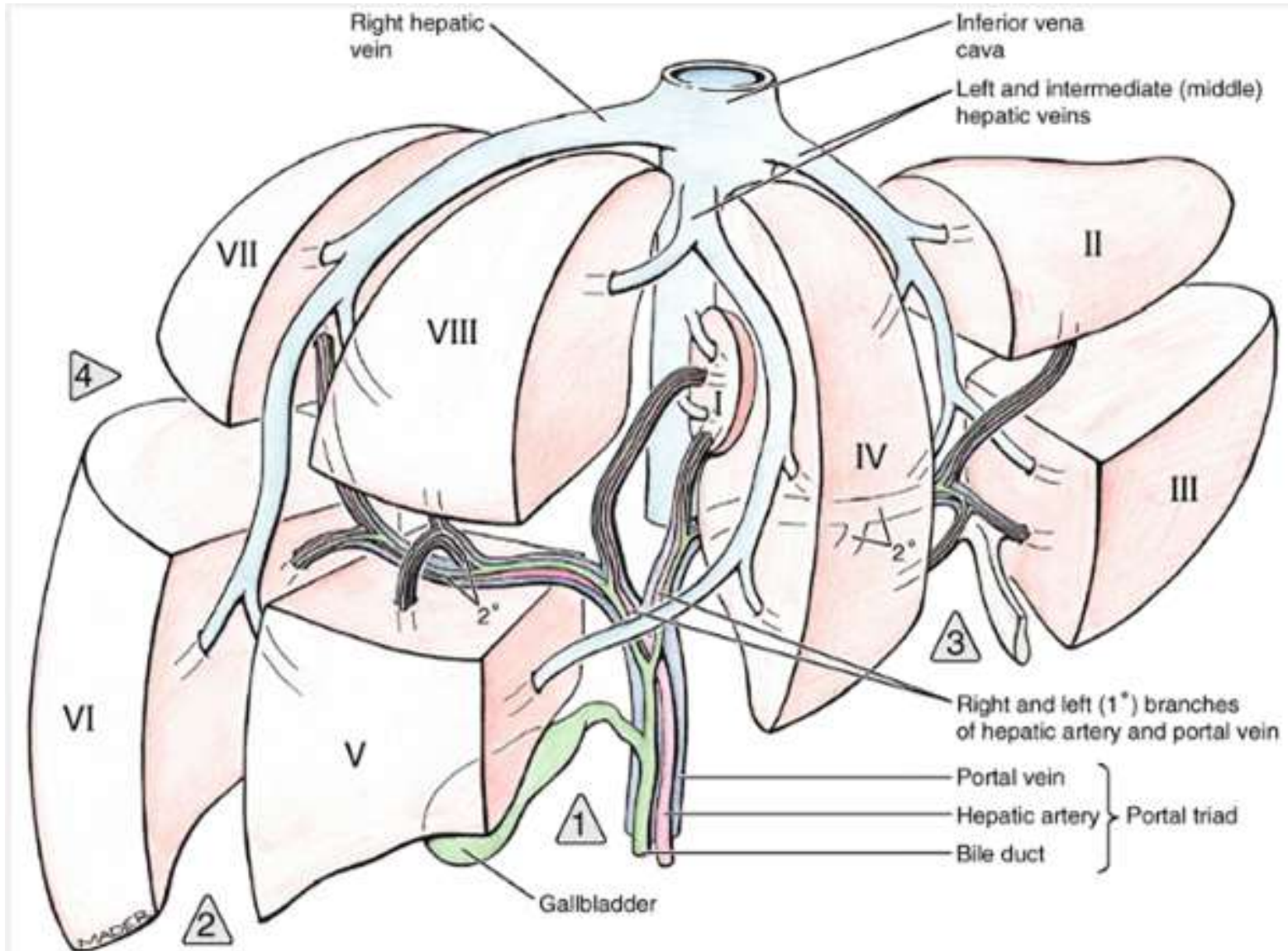
Portal Vein

- Formed by the superior mesenteric and splenic veins posterior to the neck of the pancreas and ascends anterior to the inferior vena cava as part of the portal triad in the hepatoduodenal ligament
- Divides into left and right lobar branches at the porta before entering the liver.
- Each lobar branch supplies its corresponding lobe

Hepatic Vein

- Formed by:
 - i. Right
 - ii. Intermediate (middle) and
 - iii. left hepatic veins
- Drains into the Inferior Vena Cava

Arrangement of blood supply



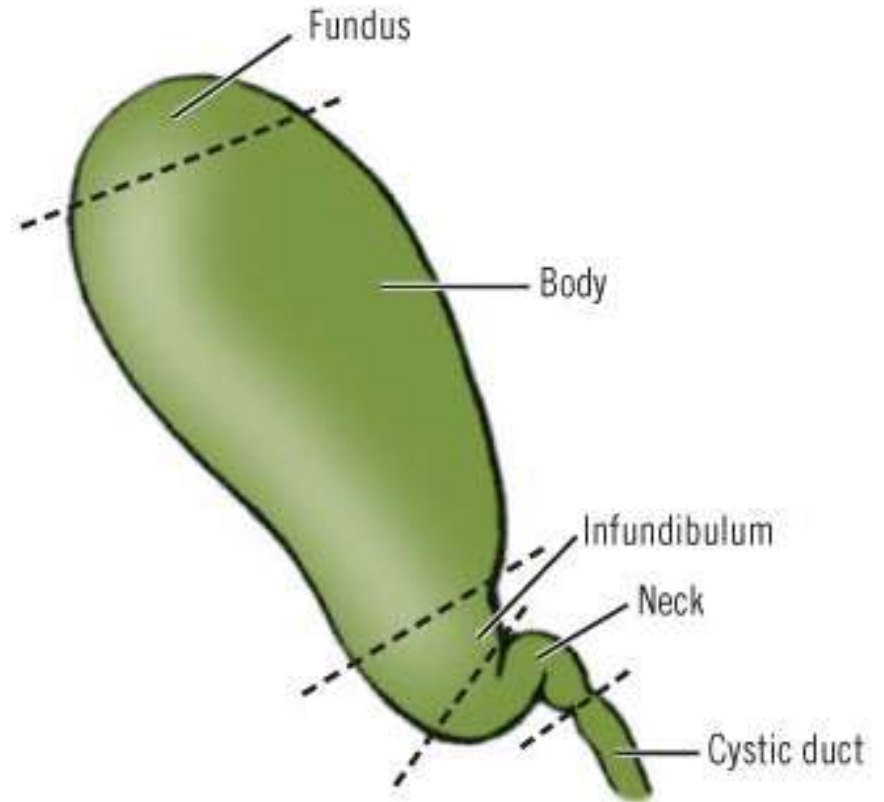
THE GALLBLADDER

I. Introduction/General Information

- Location:
 1. Epigastric region
 2. Right hypochondriac region
 3. On inferior surface of liver
 4. Between quadrate and right lobes
- Pear-shaped, hollow structure

Divisions of the Gall Bladder

- This is entirely arbitrary



The fundus

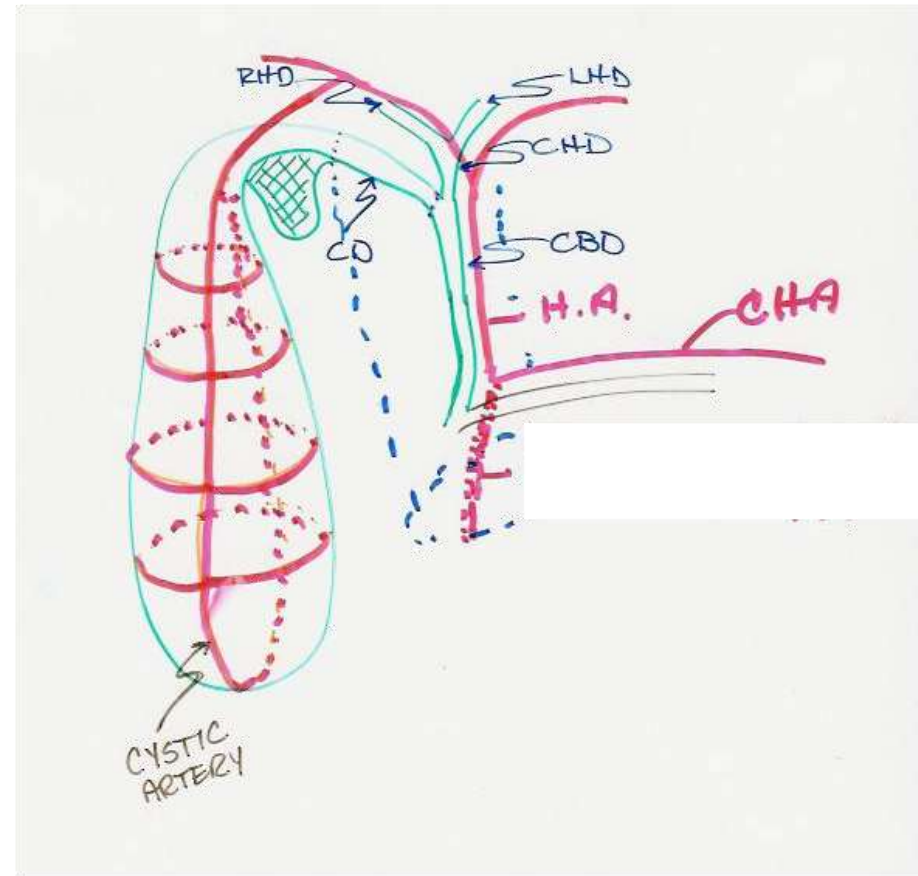
- Located at the angle of the ninth costal cartilage with the right border of the rectus sheath and to the left of the hepatic flexure of the colon.
- Slants inferiorly, to the right and projects beyond the liver
- Attached to liver by loose (areolar) connective tissue
- Peritoneum covers free surfaces
- may be palpated in angle between lateral border of right rectus abdominis and costal margin

Gallbladder: Body

- Occupies the gallbladder fossa of the liver.
- In contact with the first and second portions of the duodenum
- Also related to the transverse colon
- Partially covered with peritoneum

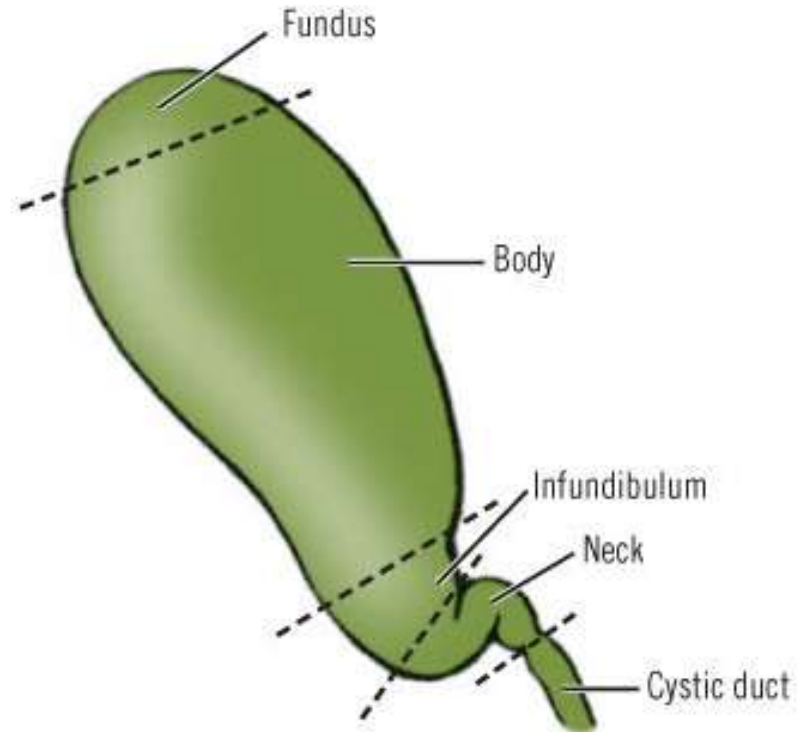
Gallbladder: Infundibulum

- The angulated posterior portion of the body between the neck and the point of entrance of the cystic artery
- Commonly has a bulging, dilated part called it is called a Hartmann's pouch.
- Hartmann's pouch is a normal variation



Gallbladder: Neck

- Curves up and forward and then sharply back and downward forming an S to become the cystic duct.
- The cystic artery is found in this region coursing in the loose connective tissue that attaches the neck of the gallbladder to the liver.



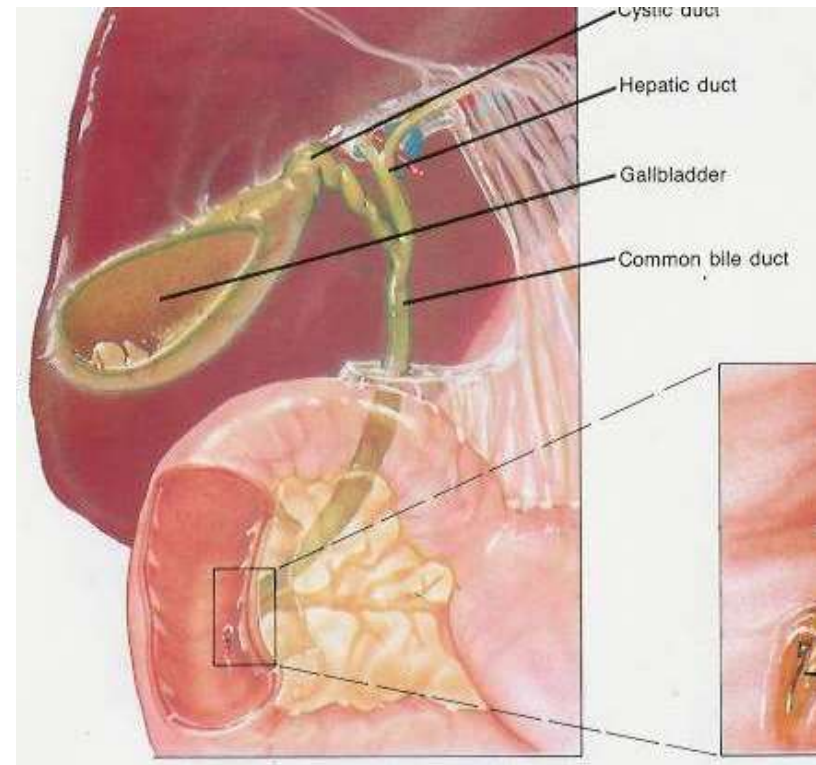
Normal measurements:

- 7-10 cm long
- ~ 6 cm diameter
- 30 – 35 cc volume

Cystic duct:

...

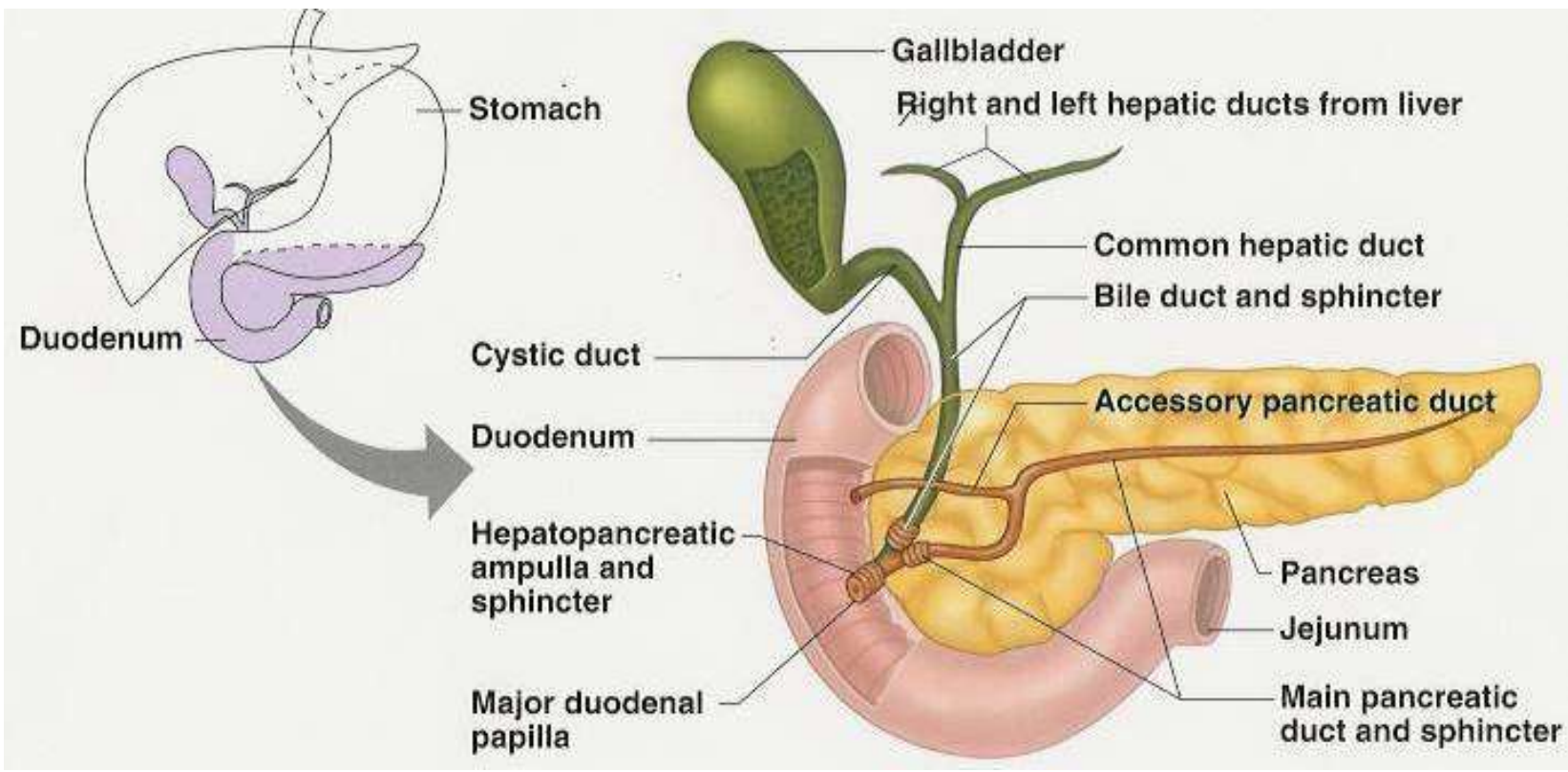
- joins common hepatic duct to form the common bile duct
- superior and posterior to pylorus of stomach



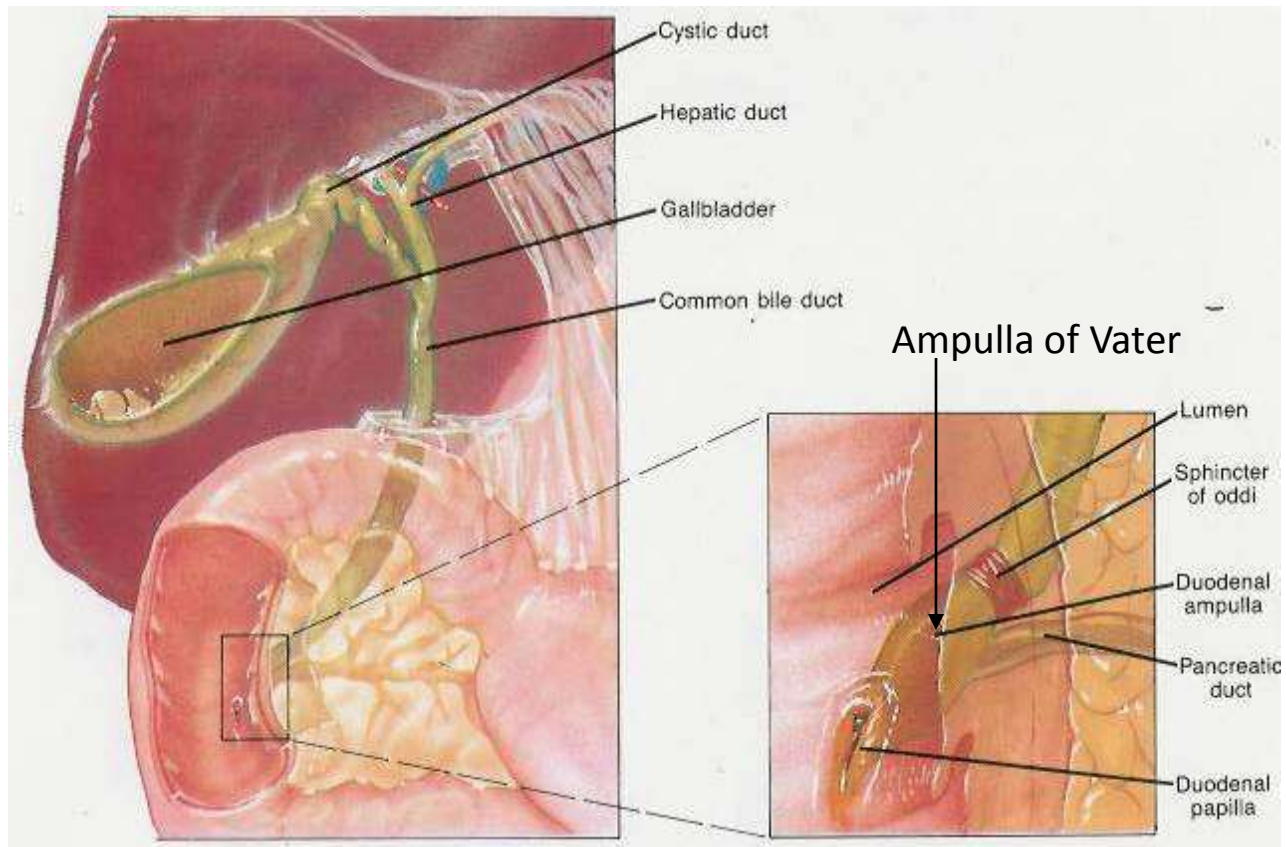
Common Bile Duct

- 10-15 cm long
- Descends in the free margin of the lesser omentum with hepatic artery on left and portal vein posterior
- Deep to pyloric sphincter
- Narrow tube, 1-2 mm diameter
- Joins with pancreatic duct
- Combined duct empties into duodenum at the ampulla of Vater
- Sphincter of Oddi guards duct, regulates bile flow
 1. Closed: bile goes into gallbladder
 2. Open: bile goes into duodenum

The Gallbladder and Biliary System with Pancreas



Ampulla of Vater with CBD and Pancreatic Duct



Blood supply to gallbladder:

1. Cystic artery

- a. arises (~ 60% of the time)
from right hepatic artery
- b. passes posterior to hepatic
duct, then divides

Arterial Supply to the Gallbladder

- Cystic artery
- Right hepatic artery
- Proper hepatic artery
- Common hepatic artery

