

# The Large Intestine

Prof. Oluwadiya KS

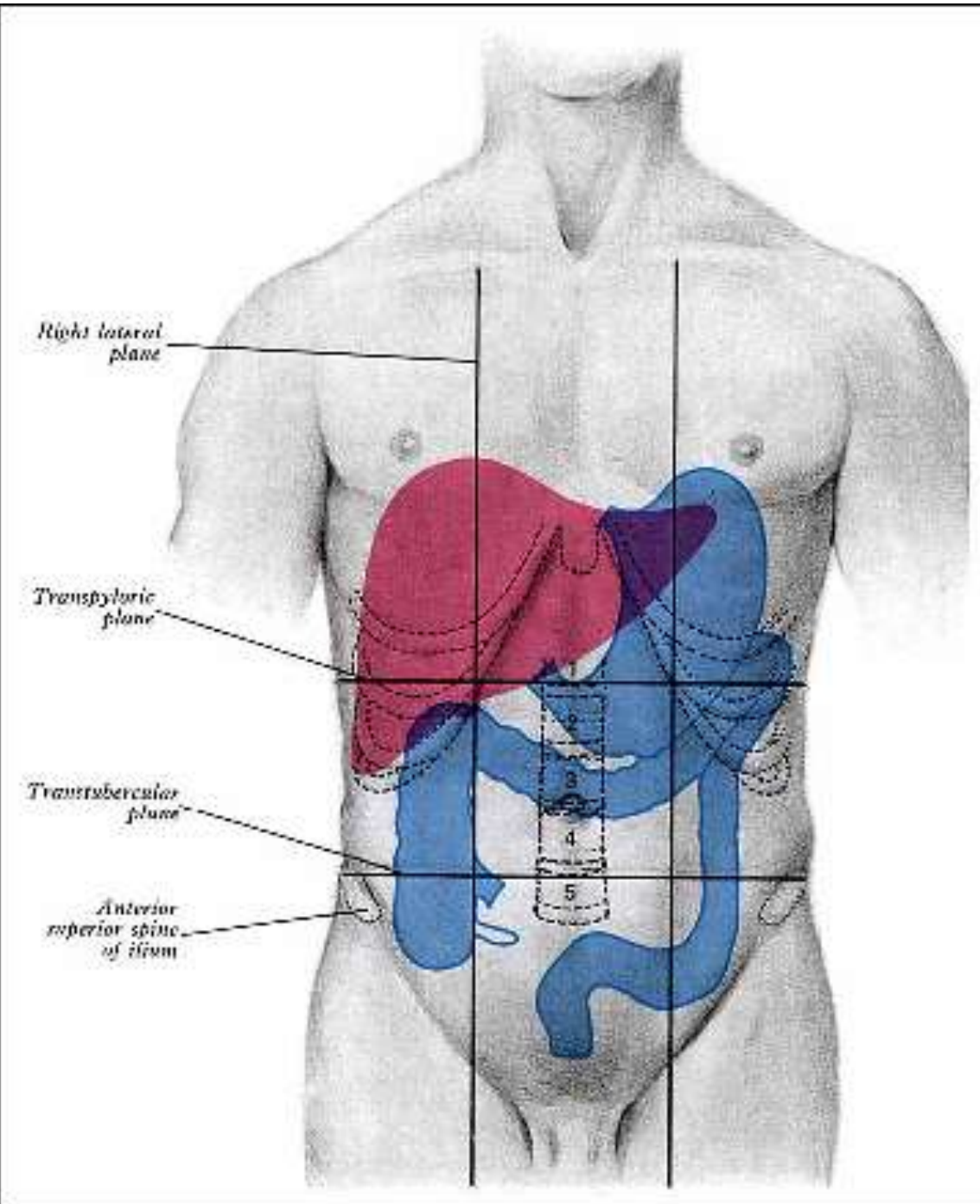
[www.oluwadiya.sitesled.com](http://www.oluwadiya.sitesled.com)

# Large Intestine: Introduction

**The following anatomic parts makes up the large intestine :**

1. Appendix
2. Cecum
3. Ascending colon
4. Hepatic flexure
5. Transverse colon
6. Splenic flexure
7. Descending colon
8. Sigmoid colon
9. Anorectum

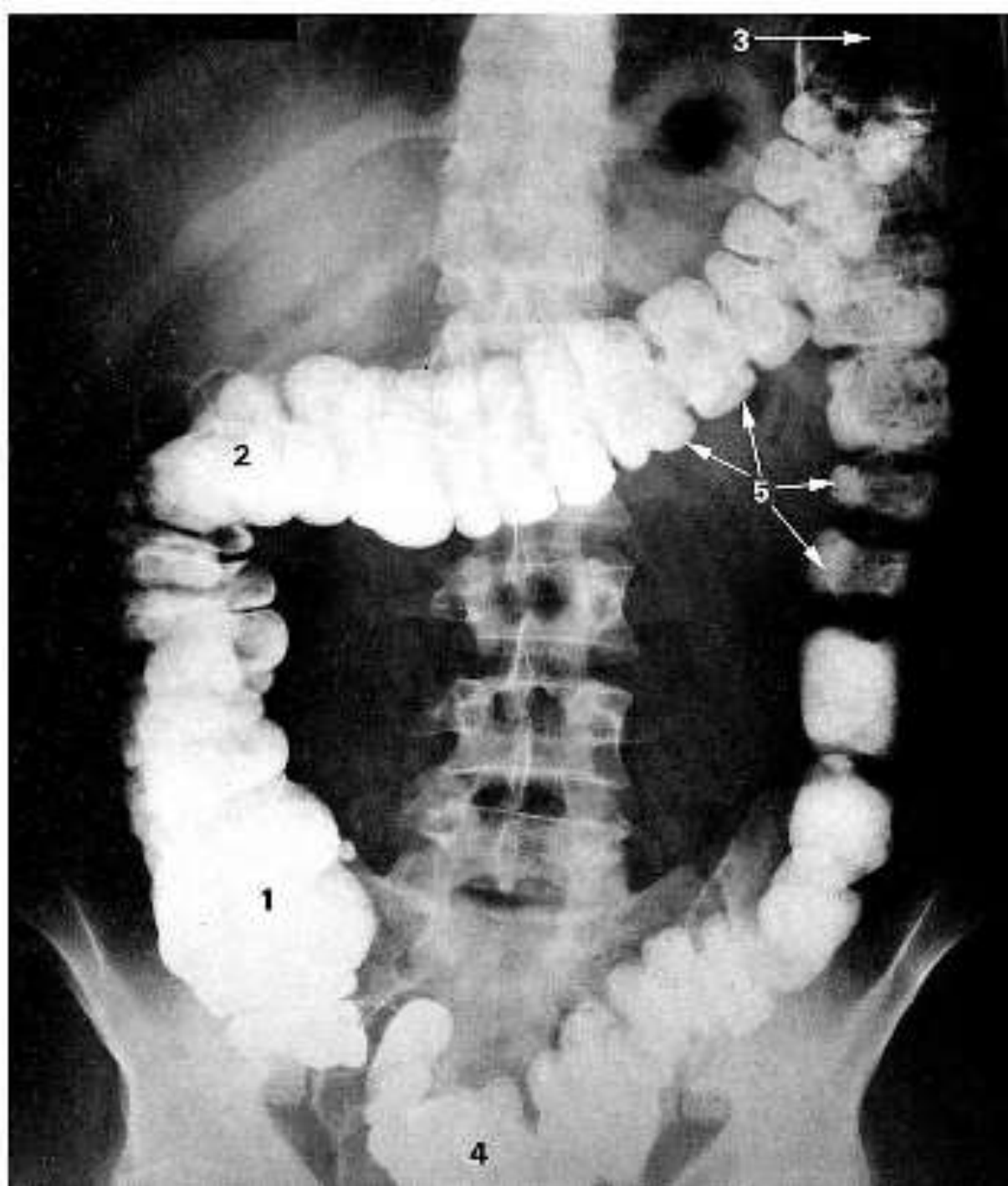
# The Large Intestine: Surface Marking



# The Large Intestine: Radiography

## Note the following:

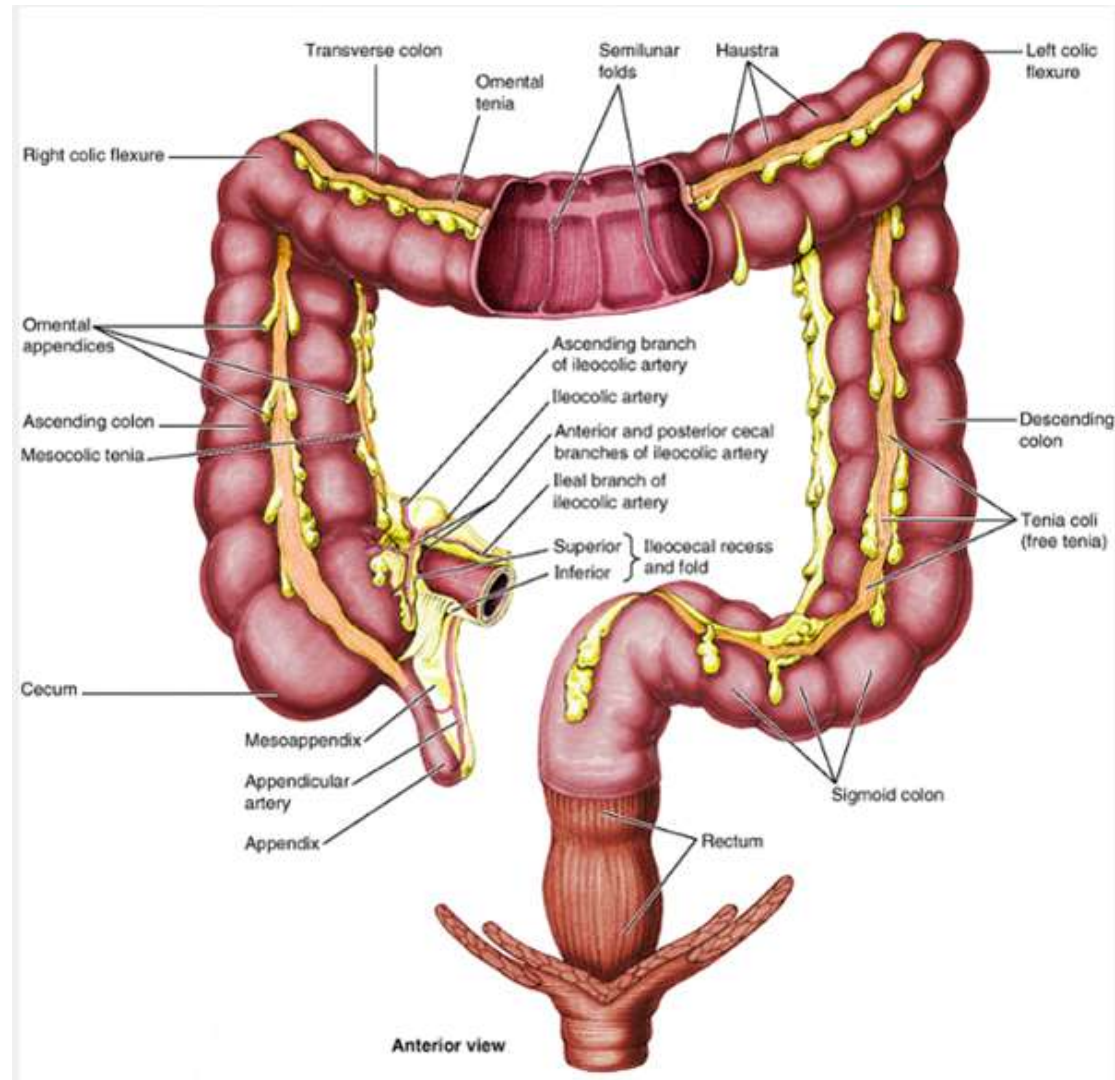
- a) Right flexure (2) is lower and less acute than the left flexure (3)
- b) The haustral sacculations
- c) The caecum (1), which is the widest part



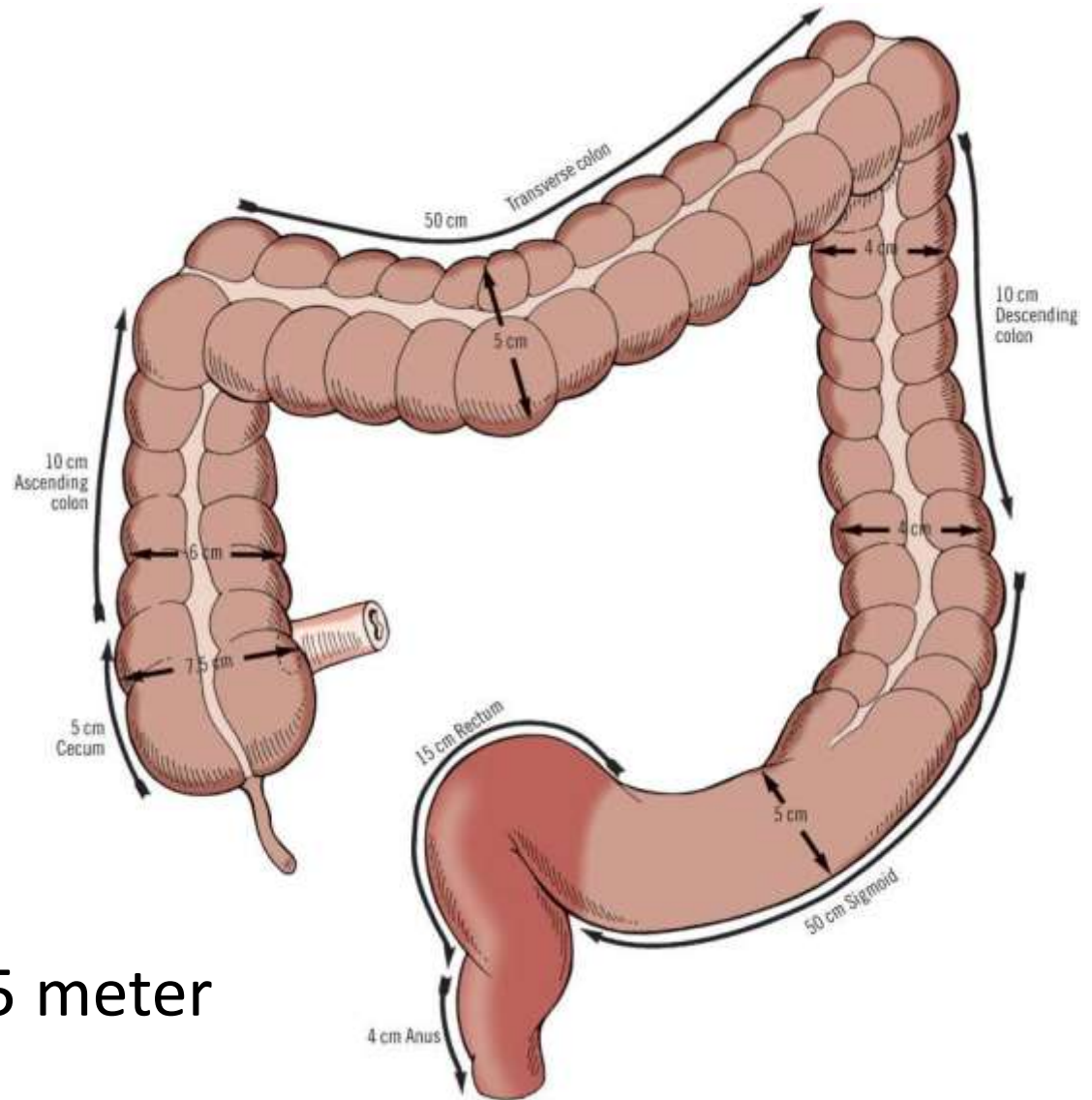
# Facts about the LI

- Its diameter is greater than that of the small intestine, but in length, it is less than half as long.
- It curves around the small intestine in a variation of shapes to end in the pelvic region.
- Except for its terminal end, the longitudinal muscle fibers of the large intestine are arranged as three bands known as taenia coli.
- Tension produced by these bands causes the large intestine to fold into pocket-like sacs known as haustral.
- A third unique feature of the large intestine is its omental appendices, which are fat-filled pouches of visceral peritoneum hanging from its external surface.

# The LI: Properties in picture



# Large Intestine: Dimension



**Length:** 1.35-1.5 meter

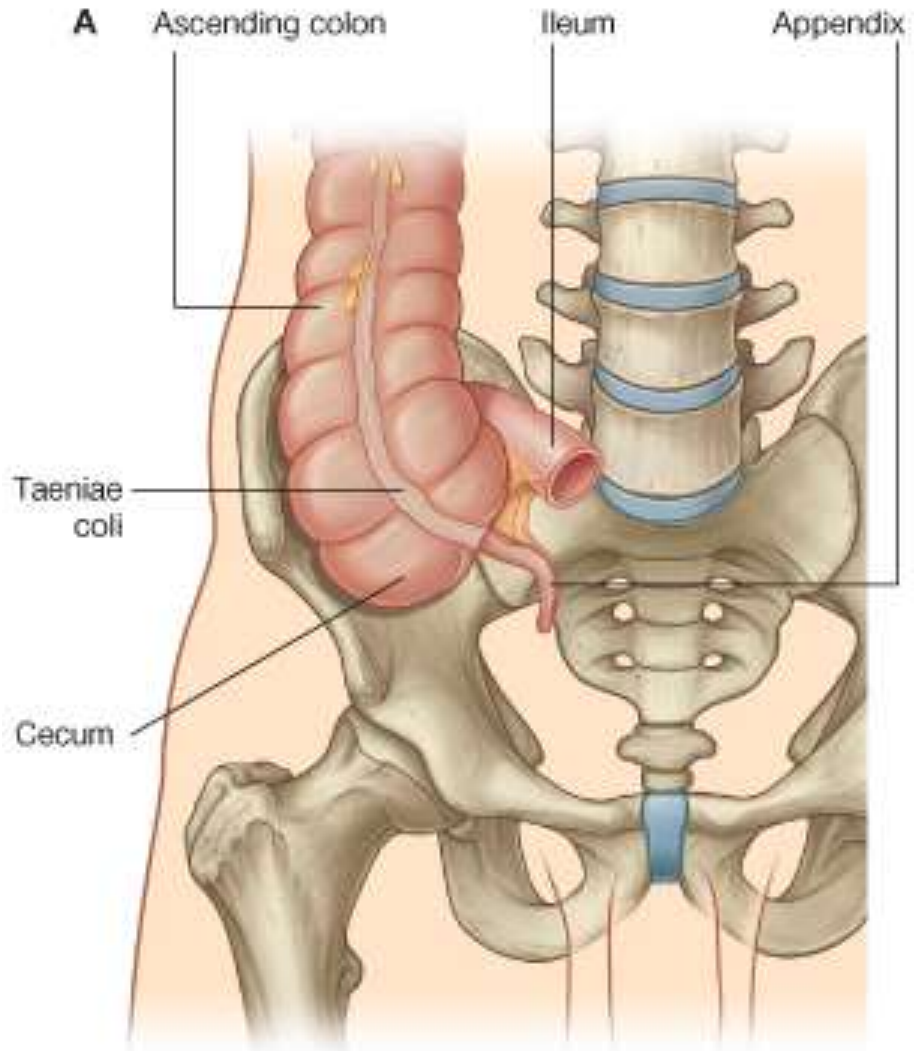
# Cecum

- The cecum is the first part of the large intestine and lies in the right iliac fossa, where it is continuous with the ascending colon superiorly and with the vermiform appendix inferiorly.
- It is about 5-6 cm in length and 7.5cm diameter
- It is inferior to the ileocecal opening.
- Becomes the ascending colon above the entrance of the ileum.
- It is almost entirely intraperitoneal, but it has no mesentery
- It may cross the pelvic brim to lie in the true pelvis



# Cecum

- It lies superior to the lateral half of the inguinal ligament and
- Rests posteriorly on the right iliacus and psoas major muscles.



# The Appendix

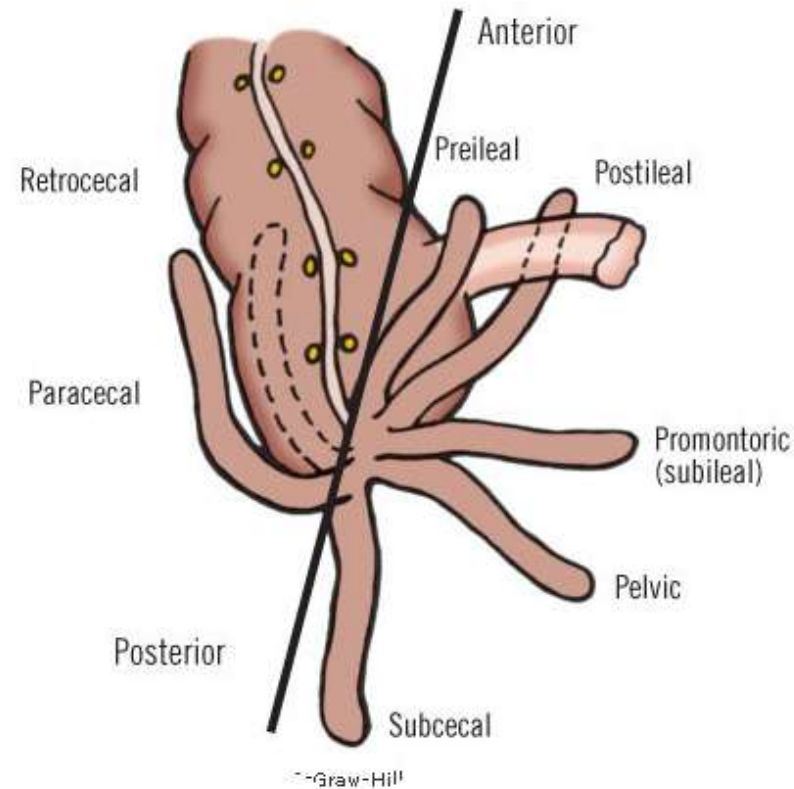
- The appendix is a blind intestinal diverticulum (6 to 10 cm in length) that contains masses of lymphoid tissue.
- It arises from the posteromedial aspect of the cecum inferior to the ileocecal junction.
- The three taenia coli on caecum converge on the base of the appendix, merging into its longitudinal muscle.
- It has a short triangular mesentery, the mesoappendix, which derives from the posterior side of the mesentery of the terminal ileum .
- The mesoappendix attaches to the cecum and the proximal part of the appendix.

# The Appendix

- The appendix varies from 2 to 20 cm in length, the average being about 9 cm.
- It is longer in children and may atrophy or diminish after mid-adult life.
- The canal of the appendix is small and opens into the cecum by an orifice lying below and a little behind the ileocecal opening
- The position of the appendix is variable, but it is usually retrocecal

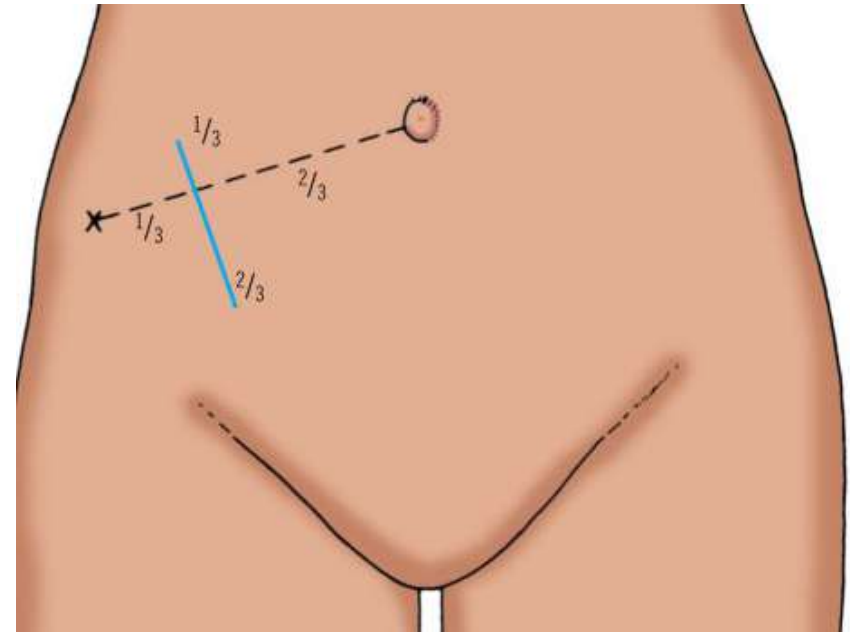
# Appendix: Possible positions

- Posterior to the cecum or the lower ascending colon, or both, in a **retrocecal** or **retrocolic** position
- Suspended over the pelvic brim in a **pelvic** or descending position
- Below the cecum in a **subcecal** location
- Anterior to the terminal ileum, possibly contacting the abdominal wall, in a **preileal** position or posterior to the terminal ileum in a **postileal** position



# McBurney's point

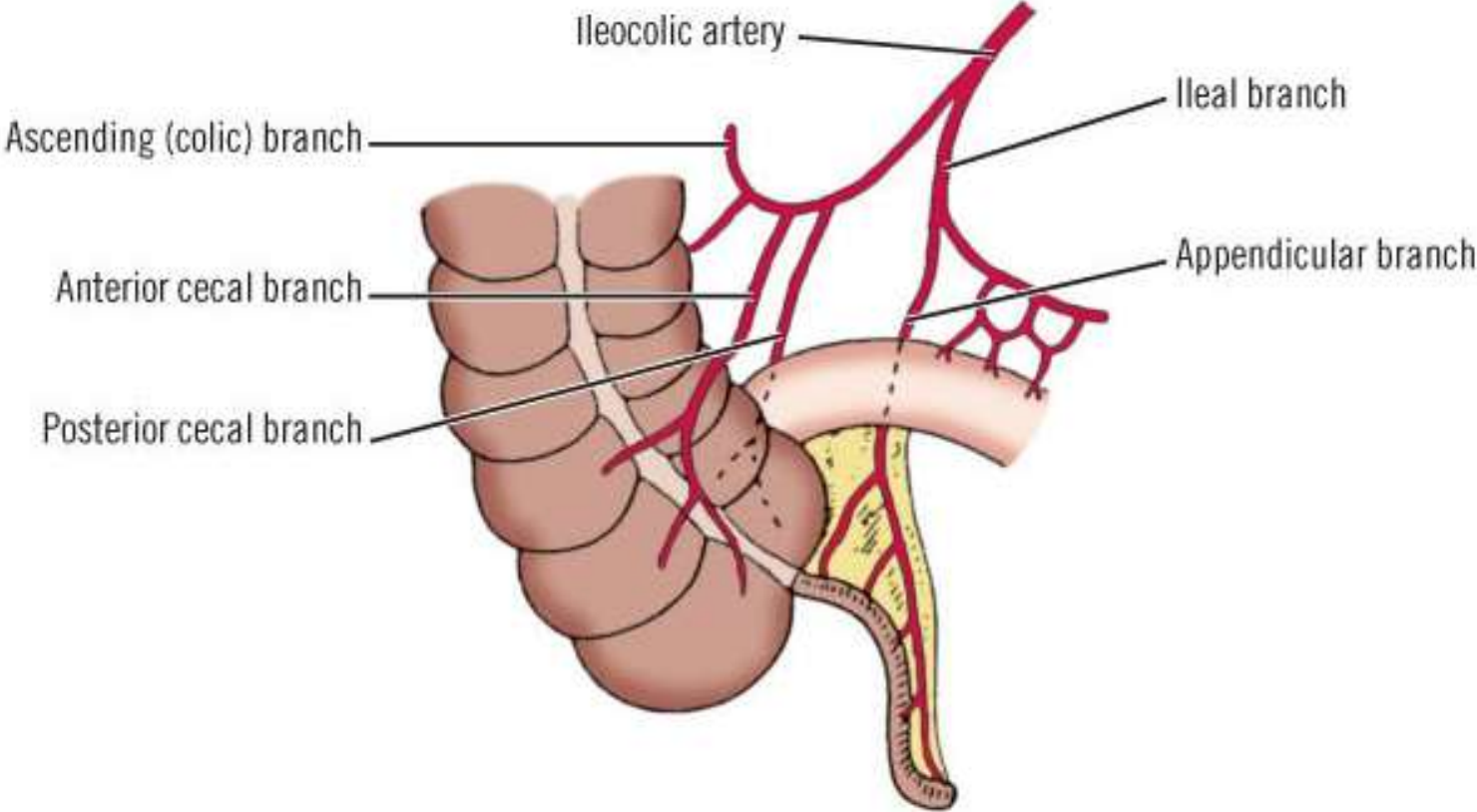
- This is the **surface projection** of the base of the appendix
- It is at the junction of the lateral and middle one-thirds of a line from the anterior superior iliac spine to the umbilicus



## **Cecum and appendix: Blood supply**

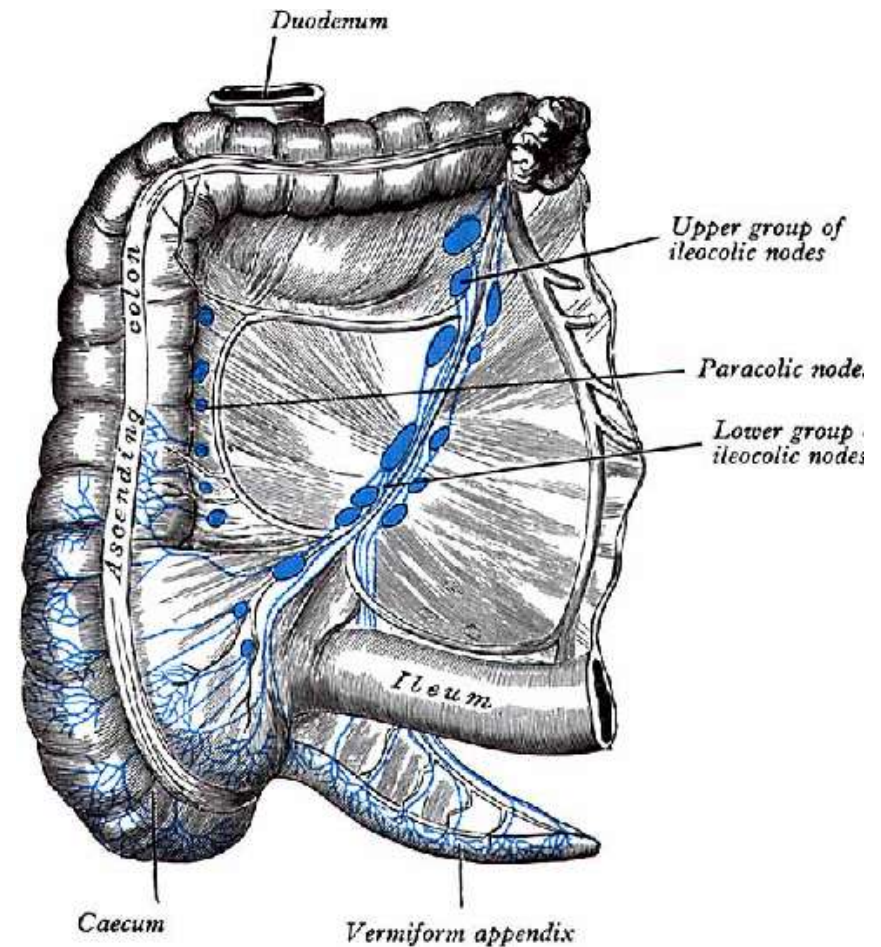
- The ileocolic artery, which arises from the right side of the superior mesenteric artery, is the chief blood supply of the cecum.
- The appendicular artery, a branch of the ileocolic artery, supplies the appendix
- The ileocolic vein is a tributary of the superior mesenteric vein

# Cecum and appendix: Arterial supply



# Cecum and appendix: lymphatics

- The lymphatic vessels from the cecum and appendix pass to lymph nodes in the mesoappendix and to the ileocolic lymph nodes that lie along the ileocolic artery
- The nerve supply is from the superior mesenteric plexus



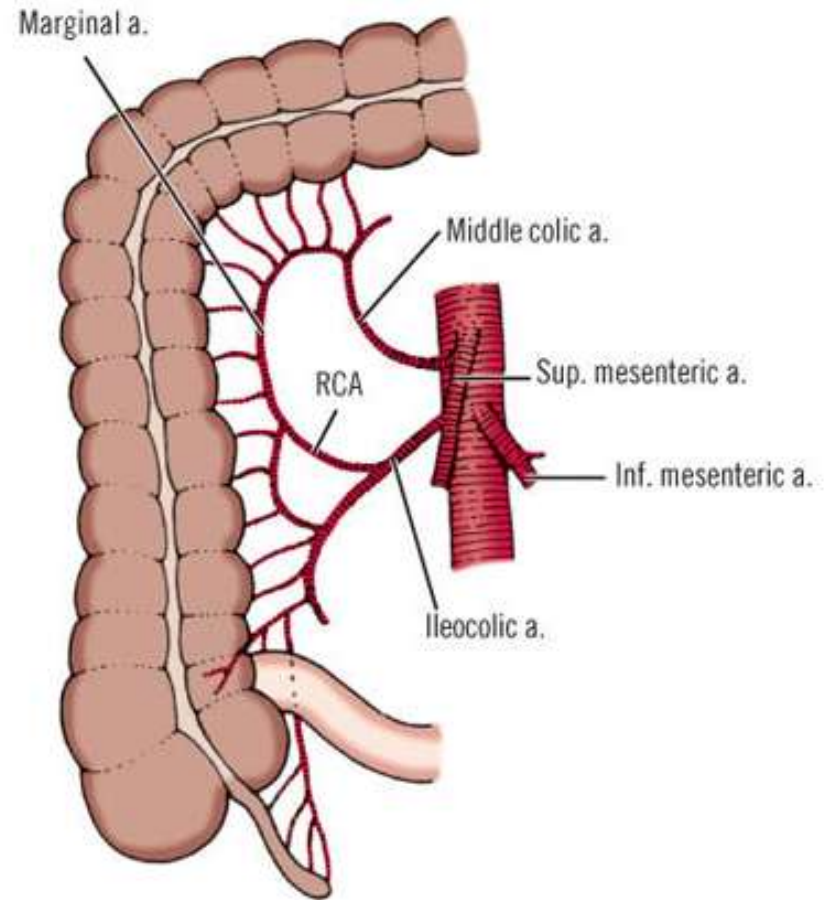


# Ascending Colon

- Retroperitoneal and narrower than the cecum
- Second part of the large intestine
- It passes superiorly on the right side of the abdominal cavity from the cecum to the right lobe of the liver, where it turns to the left at the right colic flexure (hepatic flexure) to become the transverse colon
- The right paracolic gutter, lies between the lateral aspect of the ascending colon and the adjacent abdominal wall

# Ascending Colon

- The arterial supply to the ascending colon and right colic flexure is from branches of the SMA, the ileocolic and right colic arteries
- Tributaries of the SMV, the ileocolic and right colic veins, drain blood from the ascending colon



# Right Colic (Hepatic) flexure

- The hepatic flexure is located under the right 9th and 10th costal cartilages in the vicinity of the midaxillary line.
  - The inferior surface of the right hepatic lobe is located **superiorly & anterolaterally**
  - The anterior surface of the lower half of the right kidney is located **posteriorly**
  - The duodenum (descending part) and the gall bladder are located **anteromedially**.

# The transverse colon

- The third part of the large intestine
- It is also the longest and most mobile
- Approximately 45 cm long
- Starts on the right, below the gall bladder at the right (hepatic) colonic flexure
- Ends on the left, below the spleen as the left colonic (splenic) flexure.
- Entirely intraperitoneal; mesentery is the transverse mesocolon

# The transverse mesocolon

- The root of the transverse mesocolon lies along the inferior border of the pancreas
- The transverse mesocolon contains the middle colic artery and vein, lymph nodes as well as nerves.
- The transverse mesocolon and transverse colon provide the barrier between the supracolic and infracolic compartments of the peritoneal cavity

# The left colic (splenic) flexure

- Has an acute angle.
- It is located higher and more posterior than the hepatic flexure, at the level of the 8th intercostal space.
- The lower part of the spleen and the tail of the pancreas are **superior**
- The anterior aspect of the left kidney is **medial** to it.
- It is attached to the diaphragm by the phrenicocolic ligament

# Transverse colon: Blood supply

- The main blood supply of the transverse colon is the middle colic artery.
- The ascending branch of the left colic artery also contributes to the distal part of the transverse colon

# Transverse colon: Lymphatics

- Lymphatic drainage of the **proximal** transverse colon including the hepatic flexure usually drains into the middle colic or right colic system; rarely it drains into the ileocolic system.
- The **middle** transverse colon is served by the middle colic system.
- Lymphatic drainage of the **distal** transverse colon including the splenic flexure drains to the middle colic and left colic systems.



# The descending colon

- Starts at the left colonic or splenic flexure
- Continuous with the sigmoid colon distally
- Entirely retroperitoneal
- Has the left paracolic gutter laterally to it
- It is an anterior relation to the lateral border of the left kidney
- Length: 10cm
- Breadth: 4cm
- Blood supply: Left Colic artery

# The descending colon

- The descending colon is related to the following anatomic organs:
  - i. The quadratus lumborum muscle
  - ii. Left adrenal gland
  - iii. Left kidney and left ureter
  - iv. Left gonadal vessels
  - v. Left iliohypogastric nerve
  - vi. Left ilioinguinal nerves

# Sigmoid colon

- Second longest part of the large intestine
- Continuation of the descending colon
- Starts at the level of the iliac crest
- Ends at the 3rd sacral vertebra
- Called "sigmoid" because of its "S" shape
- Has a mesentery called sigmoid mesocolon
- Has two portions:
  - i. The iliac portion is fixed and located at the left iliac fossa and is the downward continuation of the descending colon. It ends at the pelvic brim and is bereft of mesentery
  - ii. The pelvic portion which is mobile.

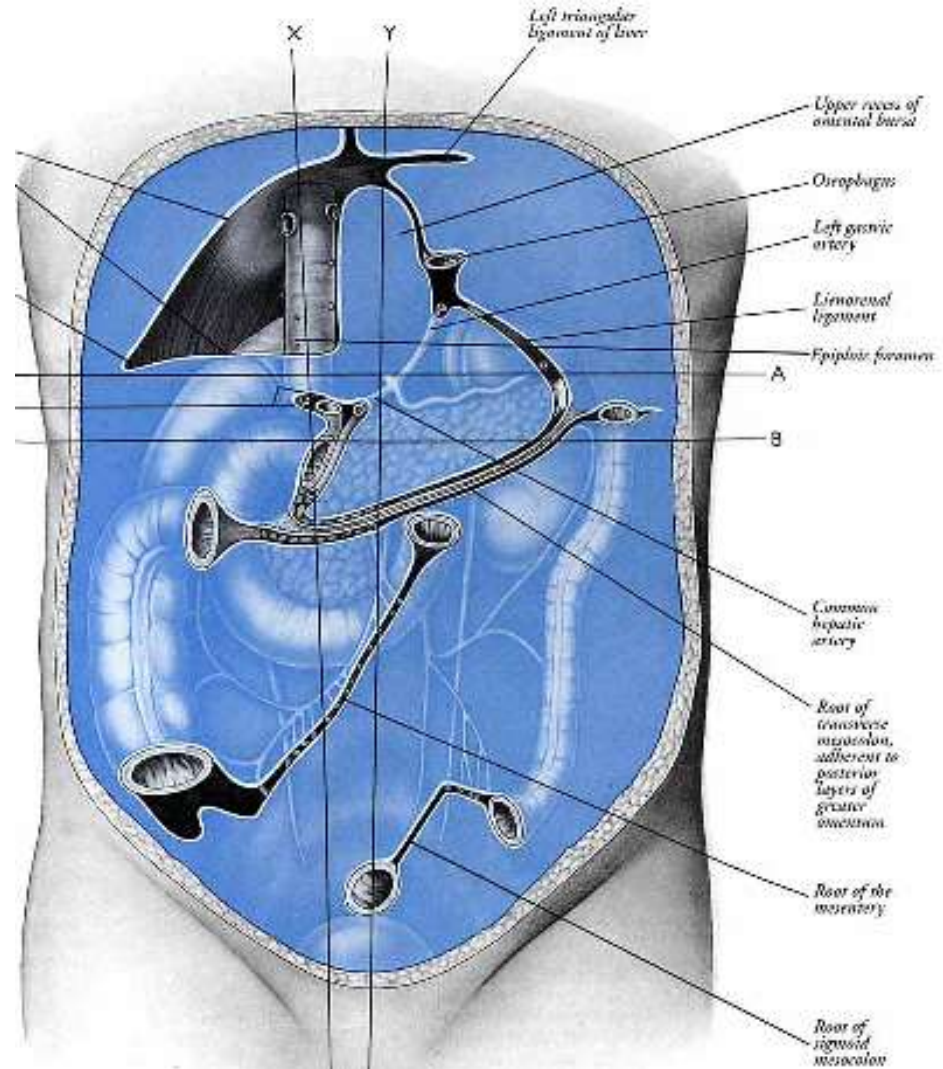
# Root of the Sigmoid colon

Has an inverted V-shaped attachment to the posterior abdominal wall

Apex is at the bifurcation of the common iliac vessels

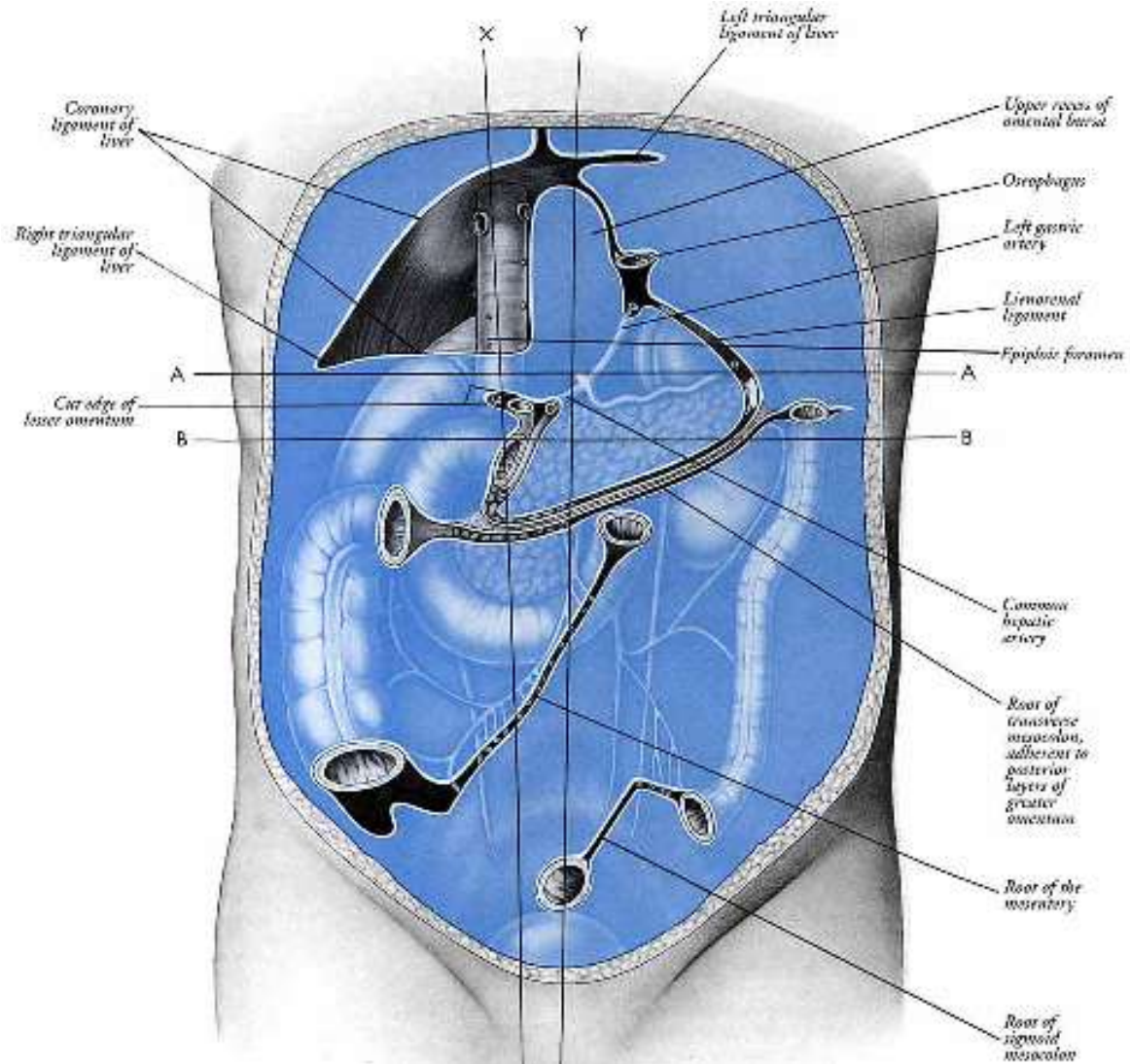
Extends first medially and superiorly along the external iliac vessels

Then medially and inferiorly from the bifurcation of the common iliac vessels to the anterior aspect of the sacrum



# Root of the Sigmoid colon

The left ureter and the division of the left common iliac artery lie retroperitoneally at the bifurcation

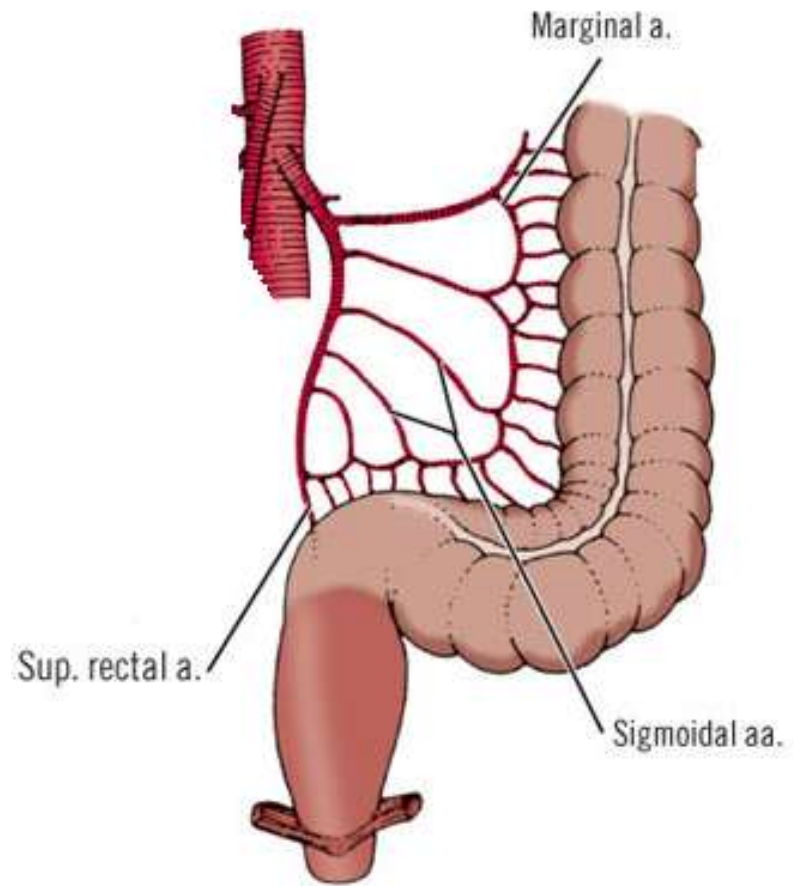


# Sigmoid colon

- The sigmoid becomes the rectum at the rectosigmoid junction
- The taenia coli terminate here
- The omental appendices also terminate here

# Sigmoid colon: Blood supply

- The sigmoid branches of the inferior mesenteric artery supply the sigmoid colon.
- The course of the lymphatics of the descending colon is as follows: the lymphatic vessels drain to nodes along the left colic artery, then to inferior mesenteric artery nodes, then to left lumbar nodes or left aortic nodes



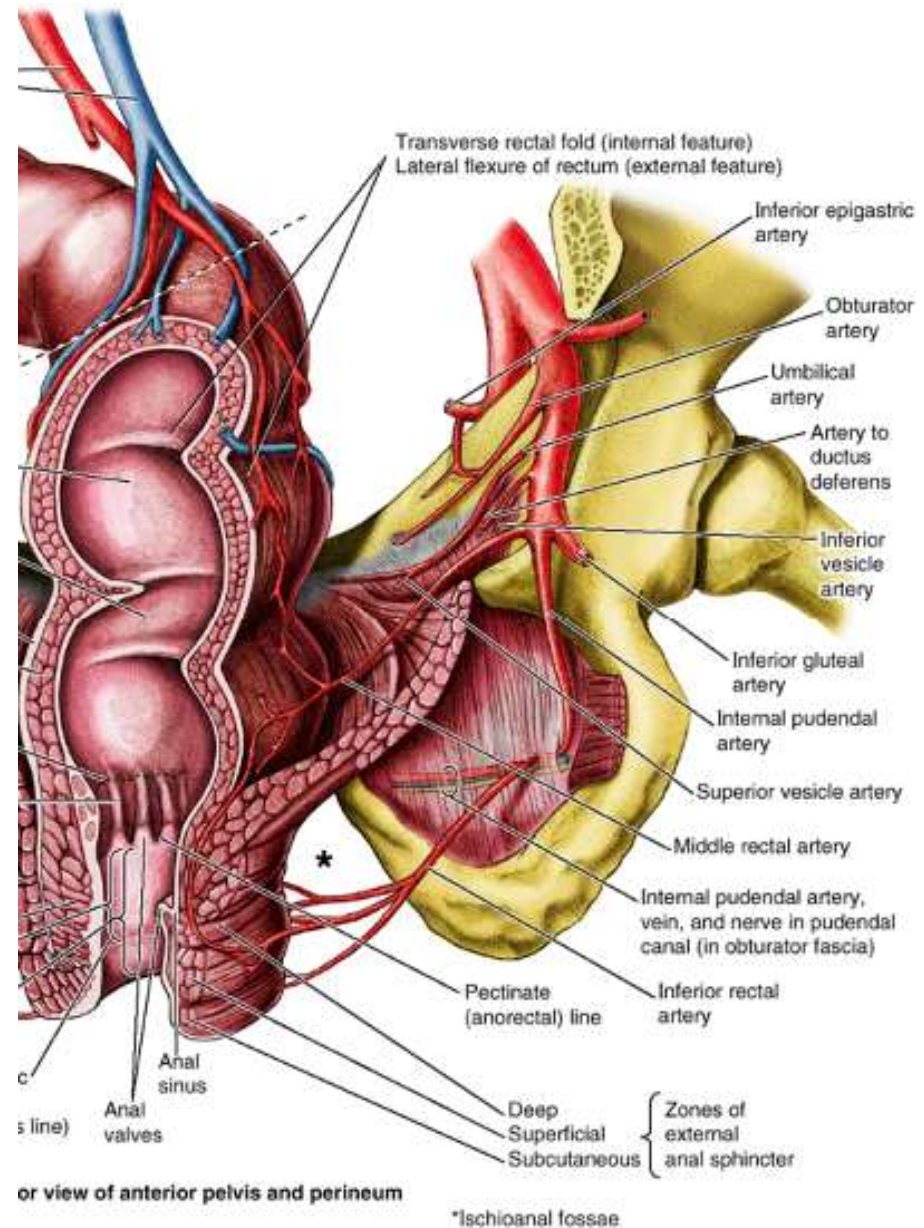
# The rectum

- The terminal part of the large intestine.
- Measures about 15 cm in length
- It is continuous with the sigmoid colon at the level of S3 vertebra. This is the rectosigmoid junction
- The rectum is continuous inferiorly with the anal canal at the dentate line



# The rectum

- Follows the contour of the sacrum
- Has 3 lateral flexures:
  - i. superior
  - ii. intermediate
  - iii. inferior
- The flexures are formed in relation to three internal infoldings (transverse rectal folds): two on the left and one on the right side.



# The rectum: Ampulla

- The dilated terminal part of the rectum, lying directly superior to and supported by the pelvic diaphragm (levator ani) and anococcygeal ligament is the ampulla of the rectum
- The ampulla receives and holds an accumulating fecal mass until it is expelled during defecation.
- The ability of the ampulla to relax to accommodate the initial and subsequent arrivals of fecal material is an essential element of maintaining fecal continence.

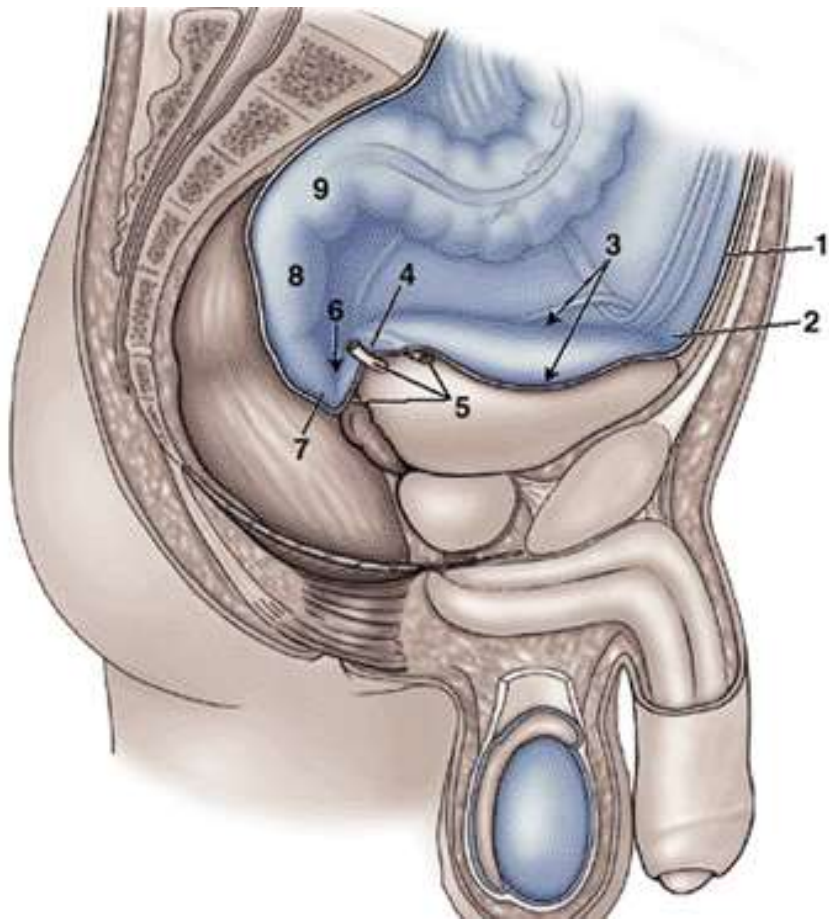
# The rectum

- Upper one-third is surrounded by peritoneum anteriorly and laterally
- The middle one-third is covered only anteriorly by peritoneum
- The lower one-third is not covered at all because it is subperitoneal

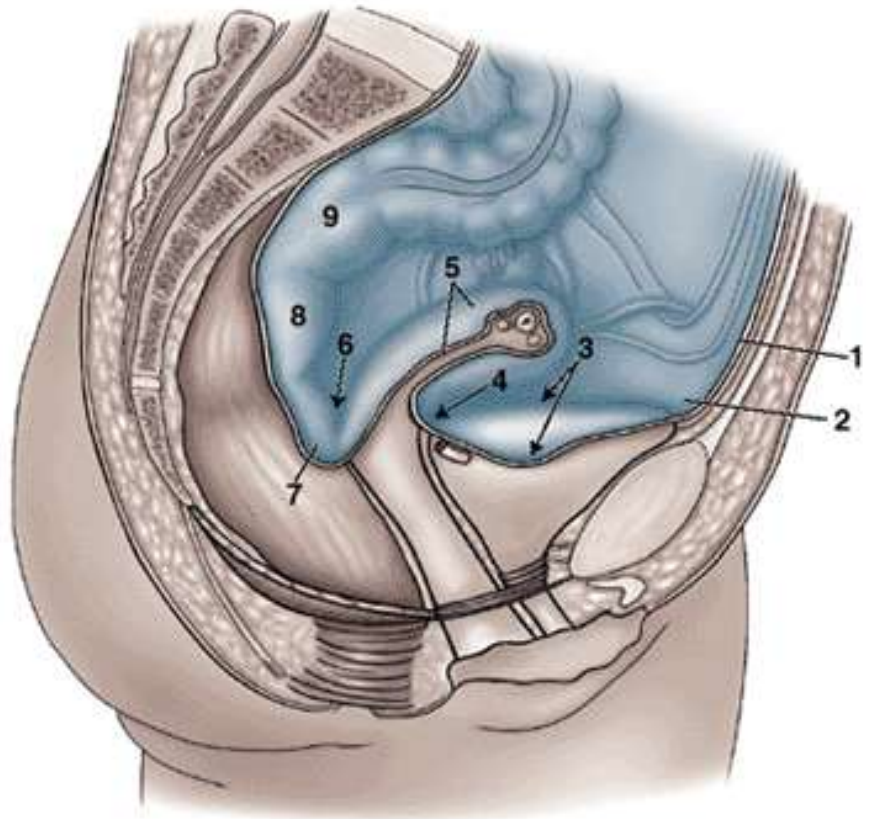
# The rectum: Peritoneal reflections

- **Males:**
  - The peritoneum reflects from the rectum to the posterior wall of the bladder, where it forms the floor of the rectovesical pouch.
- **Females:**
  - The peritoneum reflects from the rectum to the posterior part of the fornix of the vagina, where it forms the floor of the rectouterine pouch.
- **Both sexes:**
  - Lateral reflections of peritoneum from the superior third of the rectum form pararectal fossae, which permit the rectum to distend as it fills with feces.

# The rectum: Peritoneal reflections

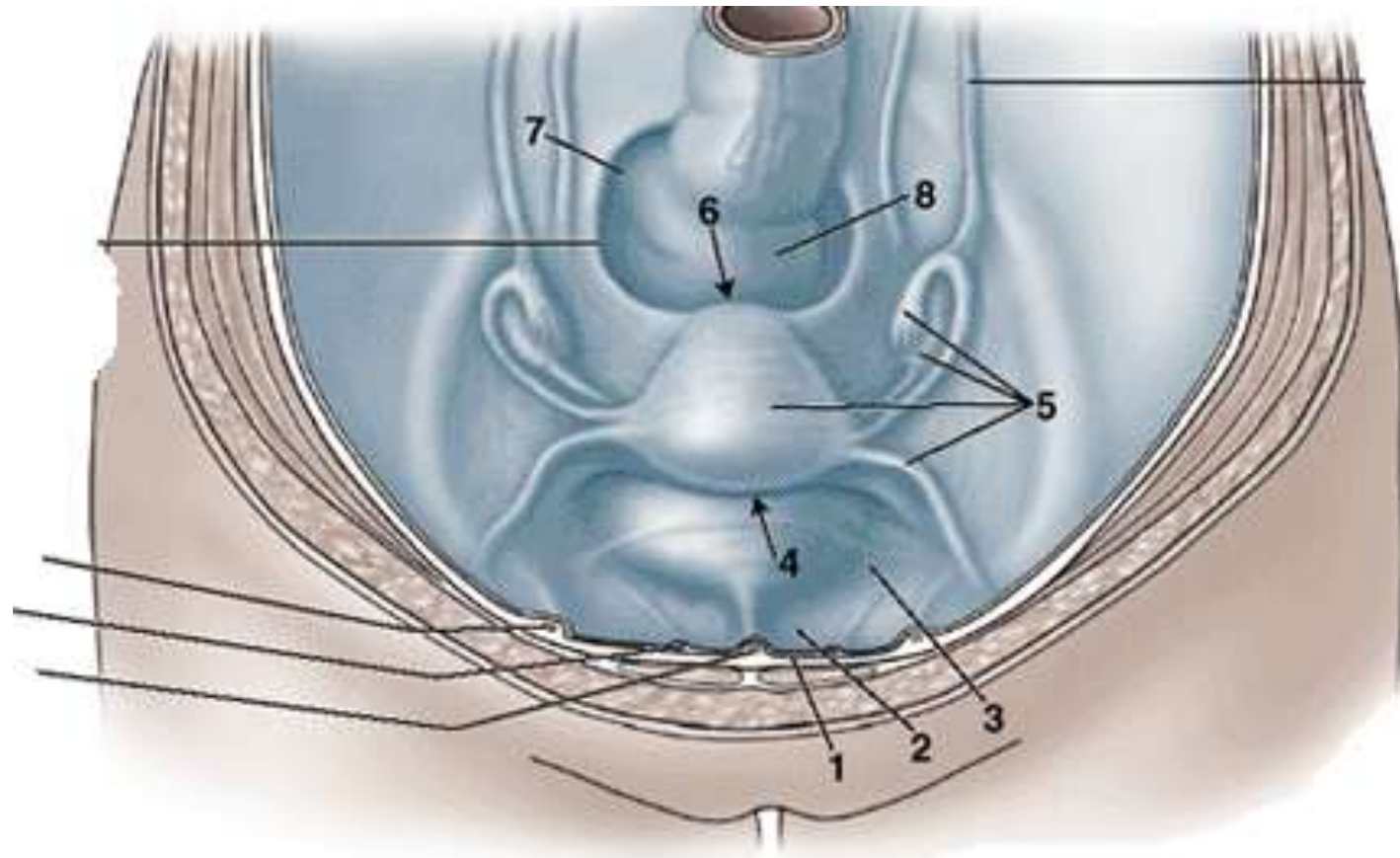


Male



Female

# The rectum: Peritoneal reflections





# The rectum: relations

## Male

- **Anterior:** prostate, seminal vesicles, ductus (vas) deferens, ureters, urinary bladder
- **Lateral:** intestinal loops, pelvic wall
- **Posterior:** sacrum, coccyx and its muscles, levator ani, median sacral vessels, roots of the sacral nerve plexus

## • Female

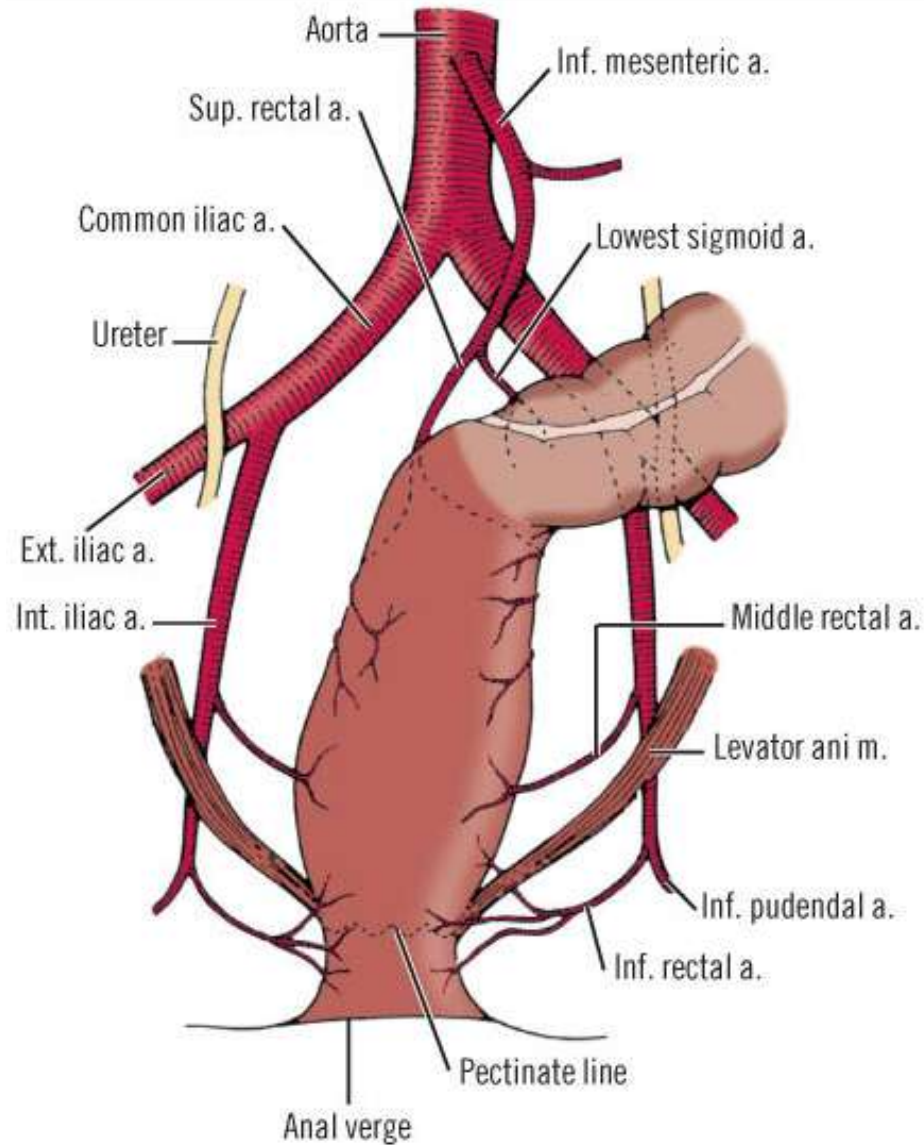
- **Anterior:** posterior vaginal wall, upper uterus, uterine (fallopian) tubes, ovaries
- **Lateral:** intestinal loops, pelvic wall
- **Posterior:** sacrum, coccyx and its muscles, levator ani, median sacral vessels, roots of the sacral nerve plexus

# The rectum: Arterial supply

- The superior rectal artery (the continuation of the inferior mesenteric artery) supplies the proximal part of the rectum
- The right and left middle rectal arteries, usually arising from the inferior vesical arteries, supply the middle and inferior parts of the rectum.
- The inferior rectal arteries, arising from the internal pudendal arteries, supply the anorectal junction and anal canal.
- Anastomoses between these arteries provide potential collateral circulation



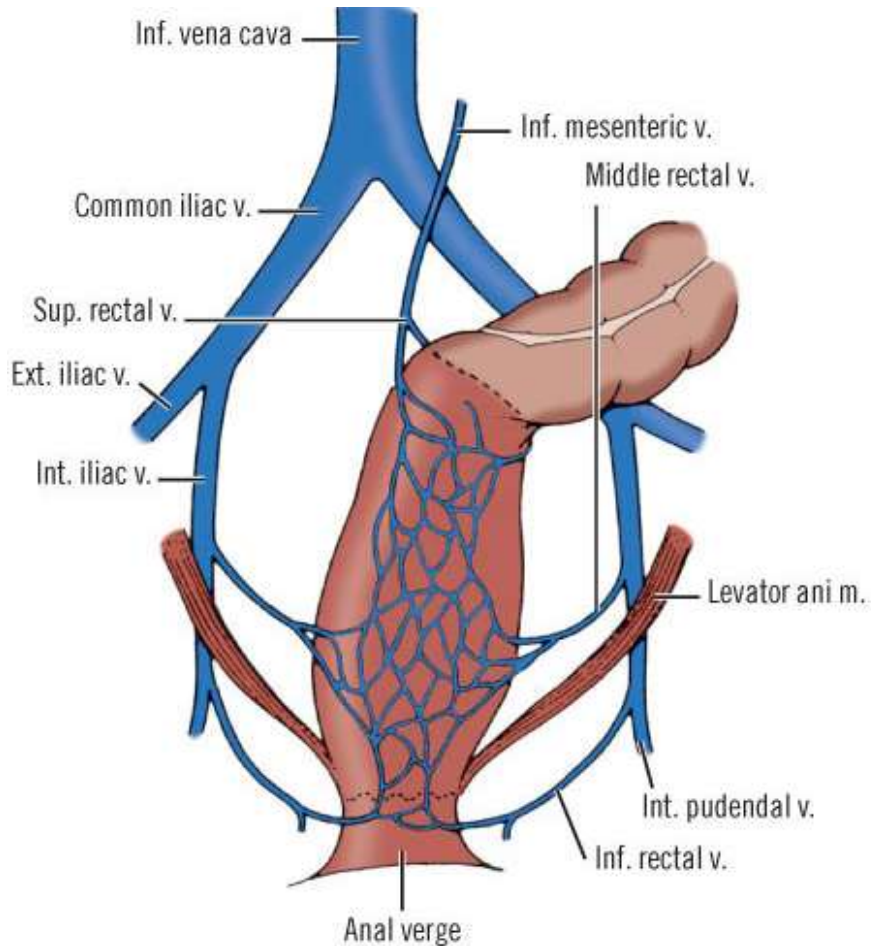
# The rectum: Arterial supply



# The rectum: Venous drainage

- Blood from the rectum drains through the superior, middle, and inferior rectal veins
- These anastomoses are clinically important areas of portacaval anastomosis:
  - i. Superior rectal vein drains into the portal venous system and the
  - ii. Middle and inferior rectal veins drain into the systemic system

# The rectum: Venous drainage



- The rectal venous plexus consists of two parts:
  - i. The internal rectal venous plexus just deep to the mucosa of the anorectal junction and
  - ii. The external rectal venous plexus external to the muscular wall of the rectum

# The rectum: Lymphatic drainage

- Superior half of the rectum
- First to the pararectal lymph nodes, then to the inferior mesenteric lymph nodes, either via sacral lymph nodes or more directly passing through nodes along the superior rectal vessels to the inferior mesenteric nodes.
- Lymphatic vessels from the inferior half of the rectum drain directly to sacral lymph nodes or, to the internal iliac lymph nodes

# The anal canal

- The terminal part of the alimentary canal
- Begins at the tip of the coccyx at the level of puborectalis muscle where the rectum makes a sharp turn posteriorly (anorectal flexure)
- Ends at the anus
- Measures 3.5 to 4 cm
- Surrounded by two sphincters
  - i. Internal anal sphincter
  - ii. External anal sphincter

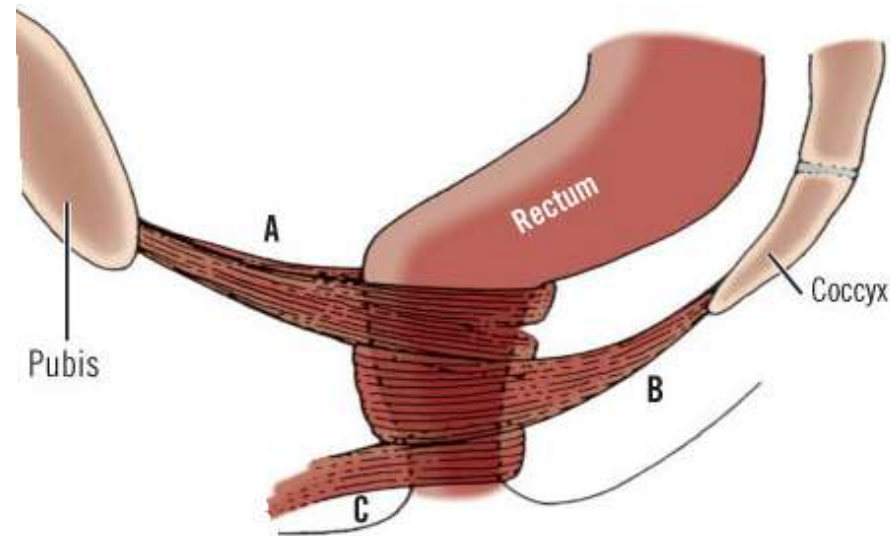
# The anal canal

- The internal anal sphincter is an involuntary sphincter surrounding the superior two thirds of the anal canal.
- It is a thickening of the circular muscle layer
- Stimulated and maintained by sympathetic fibers from the superior rectal and hypogastric plexuses
- Inhibited by parasympathetic fiber stimulation

# The anal canal: The external anal sphincter

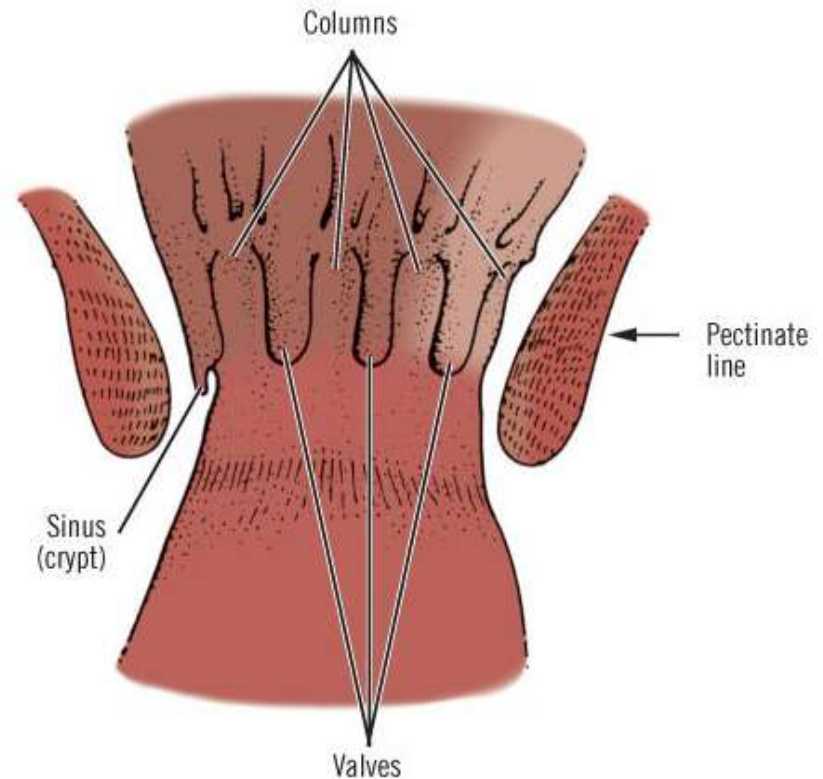
- Made of voluntary muscles
- Surrounds the inferior two thirds of the anal canal
- Attached anteriorly to the perineal body and posteriorly to the coccyx via the anococcygeal ligament (body)
- Has three parts:
  - i. Deep **(A)**.
  - ii. Superficial **(B)**
  - iii. Subcutaneous **(C)**

Continence depends on the preservation of at least one of the three.



# The anal canal: Pectinate line

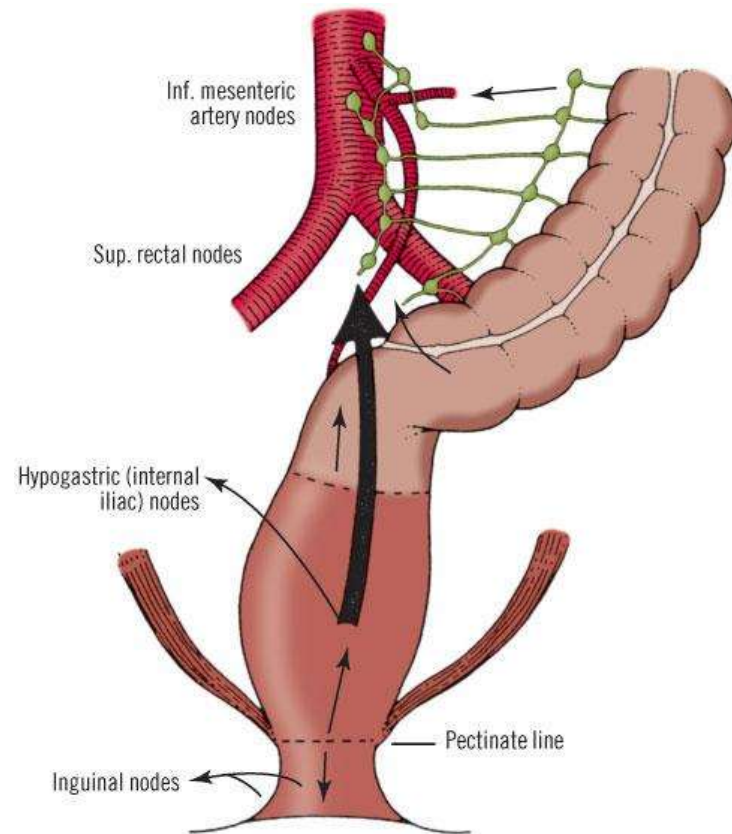
- The pectinate line is formed by the margins of the anal valves, small mucosal pockets between the 5-10 vertical folds of the mucosa known as the *anal columns of Morgagni*. These columns extend upward from the pectinate line to the level of the puborectalis sling





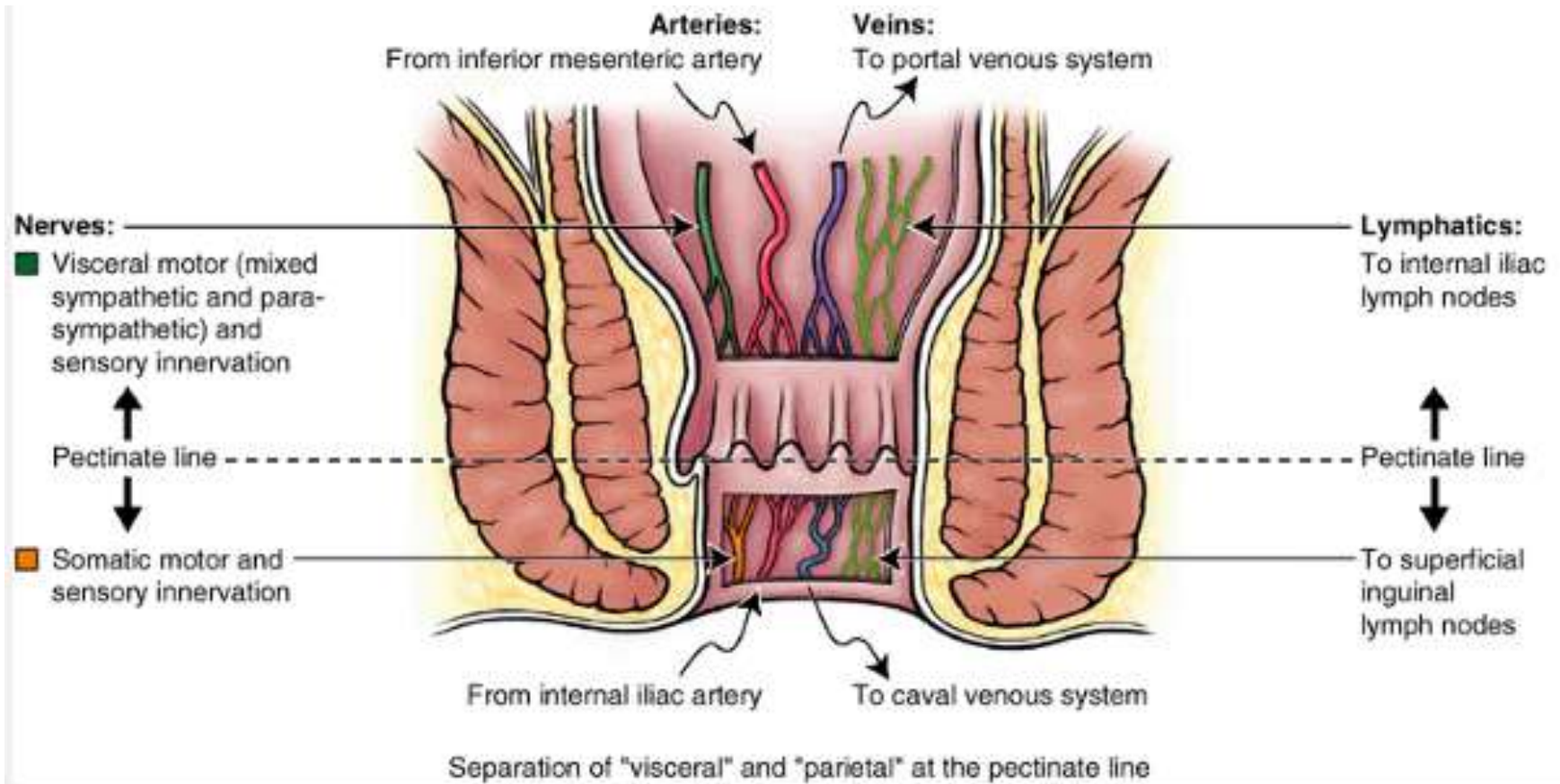
# The anal canal: Pectinate line

- Junction of the superior part of the anal canal (visceral; derived from the embryonic hindgut) and the inferior part (somatic; derived from the embryonic proctodeum)



Copyright ©2006 by The McGraw-Hill Companies, Inc.  
All rights reserved.

# The anal canal: Pectinate line



# Changes at the pectinate line

	<b>Below the Pectinate Line</b>	<b>Above the Pectinate Line</b>
Embryonic origin	Ectoderm	Endoderm
Anatomy		
Lining	Stratified squamous	Simple columnar
Arterial supply	Inferior rectal artery	Superior rectal artery
Venous drainage	Systemic, by way of inferior rectal vein	Portal, by way of superior rectal vein
Lymphatic drainage	To inguinal nodes	To pelvic and lumbar nodes
Nerve supply	Inferior rectal nerves (somatic)	Autonomic fibers (visceral)
Physiology	Excellent sensation	Sensation quickly diminishes

Any Question?

