

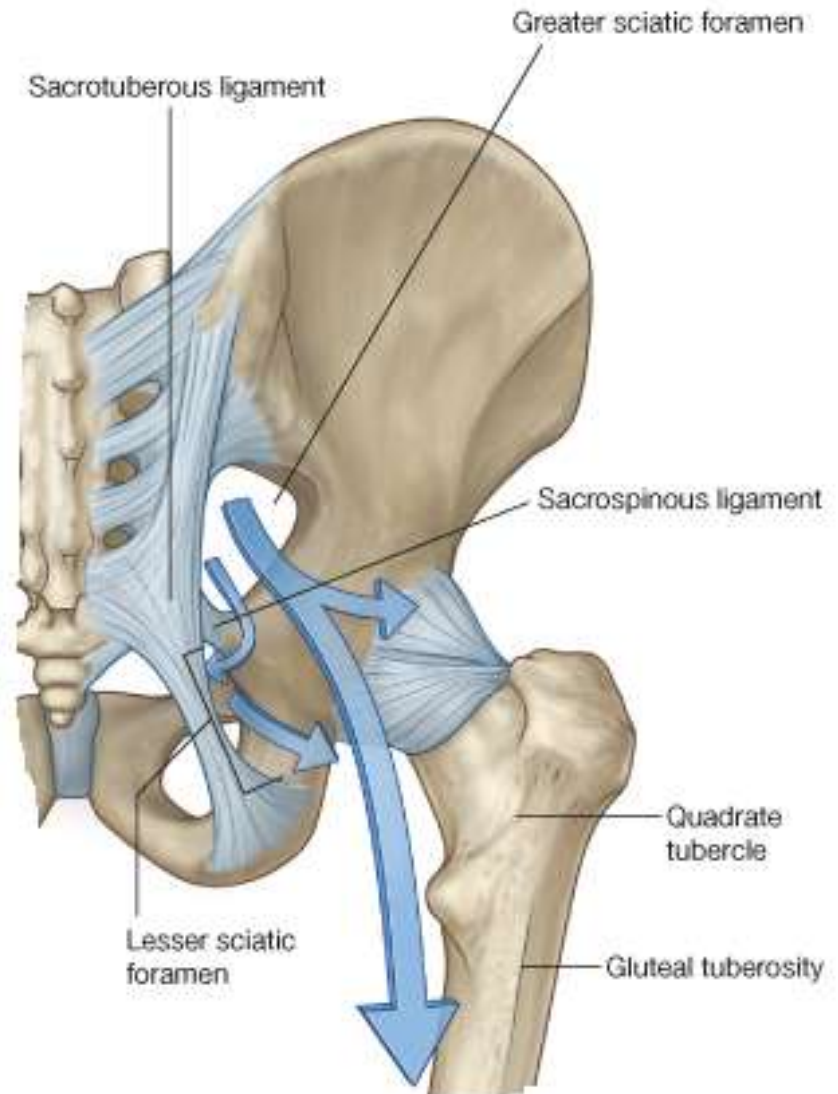
The Gluteal Region

Prof. Oluwadiya Kehinde

www.oluwadiya.com

Gluteal Region: Introduction

- Posterolateral to the bony pelvis
- Muscles abduct, extend and rotate the hip externally & internally
- Communicates with the pelvic cavity and perineum through the greater and lesser sciatic foramina respectively
- Continues with the posterior thigh



The muscles

Deep Layer (5 short muscles)

- i. Piriformis
 - ii. Superior Gemellus
 - iii. Obturatus Internus
 - iv. Inferior Gemellus
 - v. Quadratus Femoris
- All insert into or near the trochanteric fossa

Superficial Group (4 larger muscles).

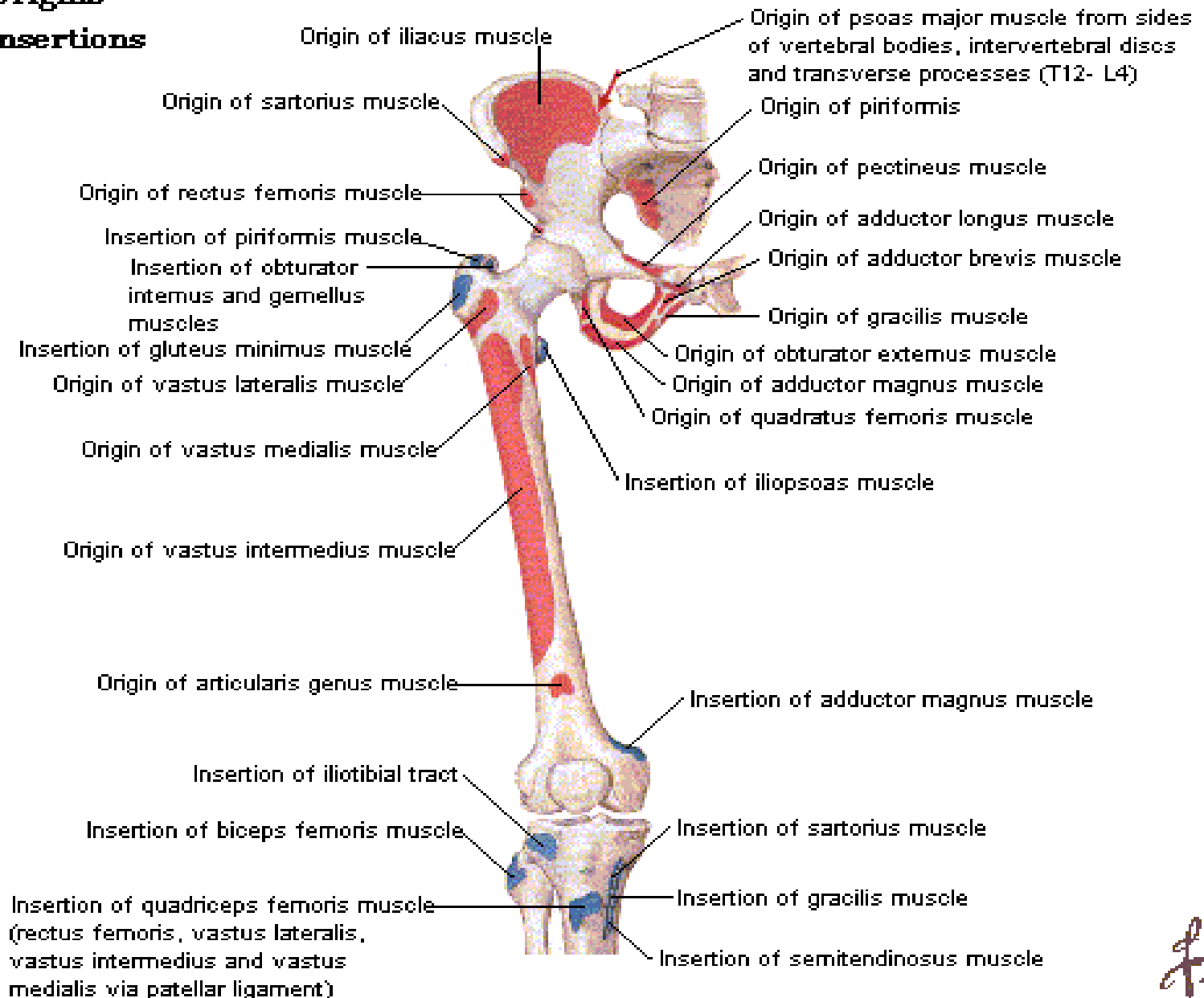
- i. Gluteal Minimus
 - ii. Gluteal Medius
 - iii. Gluteal Maximus
 - iv. Tensor fascia lata
- They all originate from the gluteal surface of the iliac wing and insert on or near the greater trochanter

Origins/Insertions

Anterior View

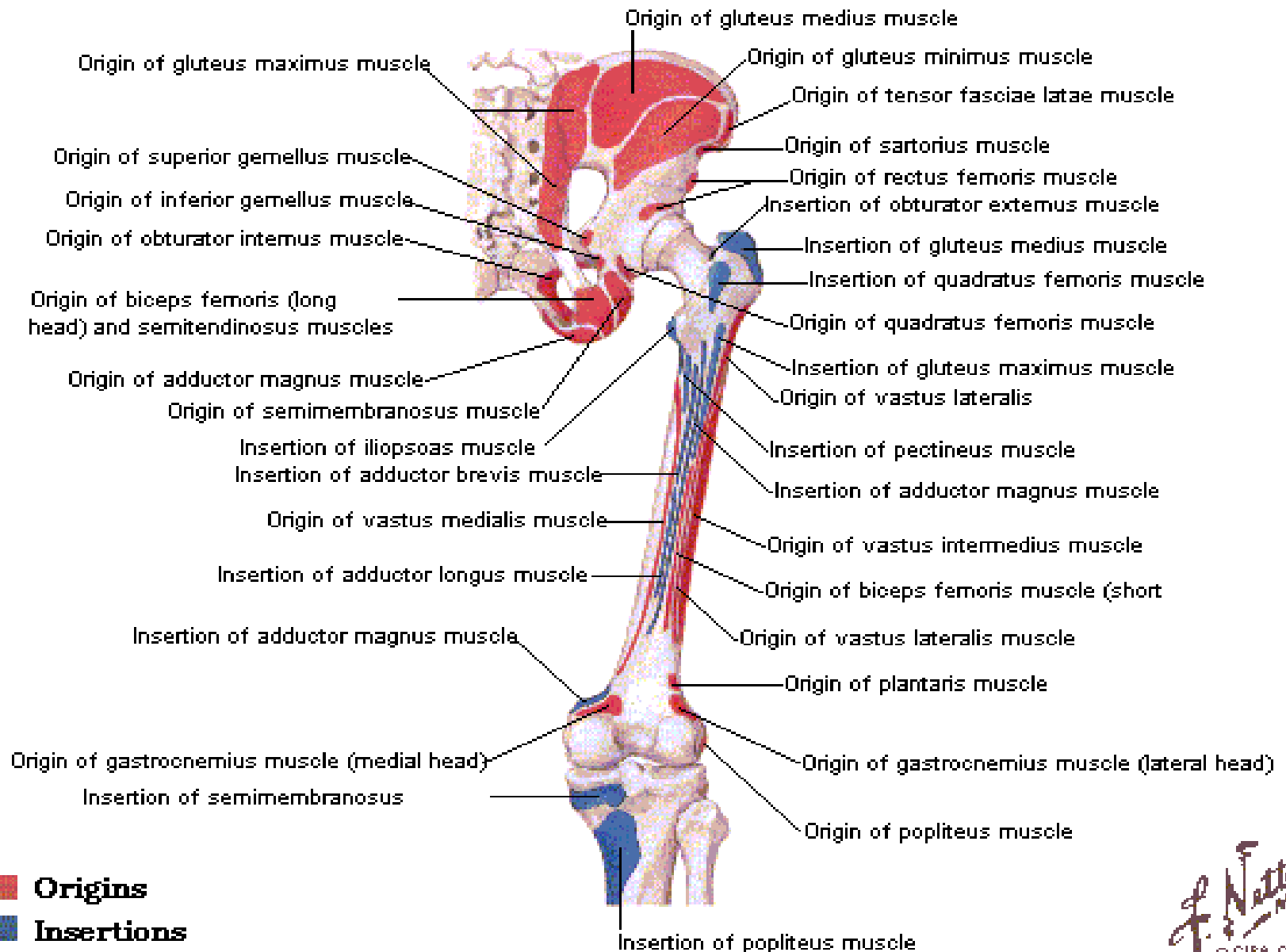
 **Origins**

 **Insertions**



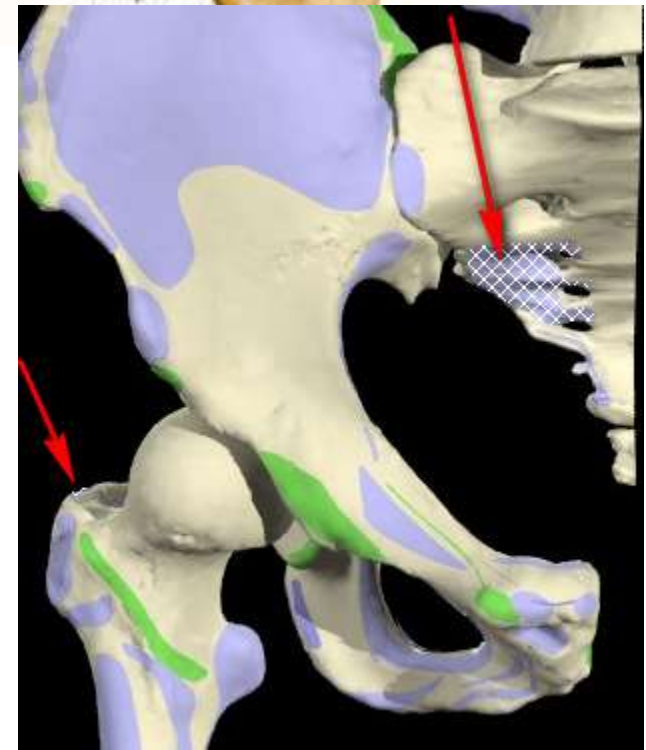
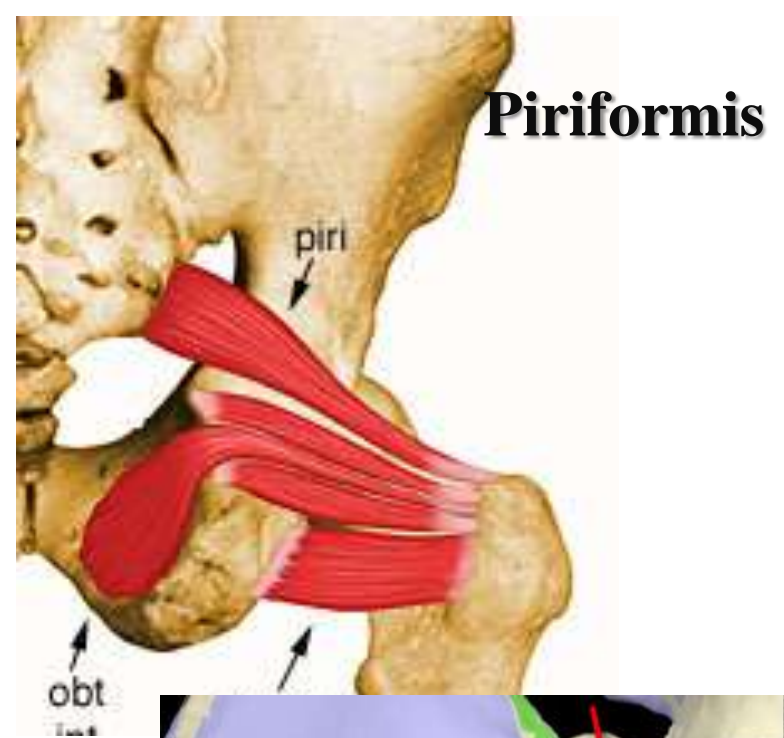
Origins/Insertions

Posterior View



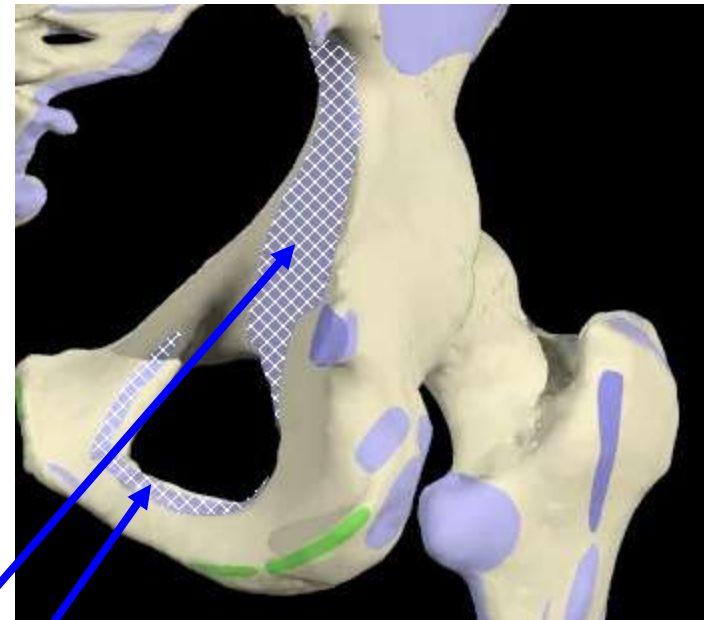
Piriformis

- **O**: Pelvic surface of 2nd to 4th sacral segment lateral to the pelvic sacral foramina
- **I**: Medial side of greater trochanter of femur
- **A**: Laterally rotates the extended femur at hip joint; abducts flexed femur at hip joint
- **N**: Nerve to obturator internus

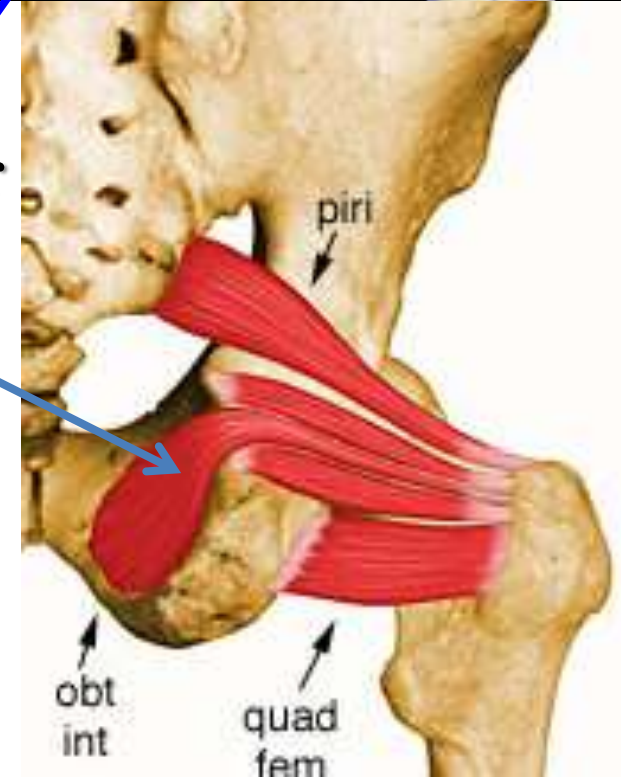


Obturator internus

- **O**: Inner surface of the obturator membrane and the bone surrounding the obturator foramen
- **I**: Medial side of greater trochanter above the trochanteric fossa
- **A**: Laterally rotates the extended femur at hip joint; abducts flexed femur at hip joint
- **N**: Nerve to the obturator internus

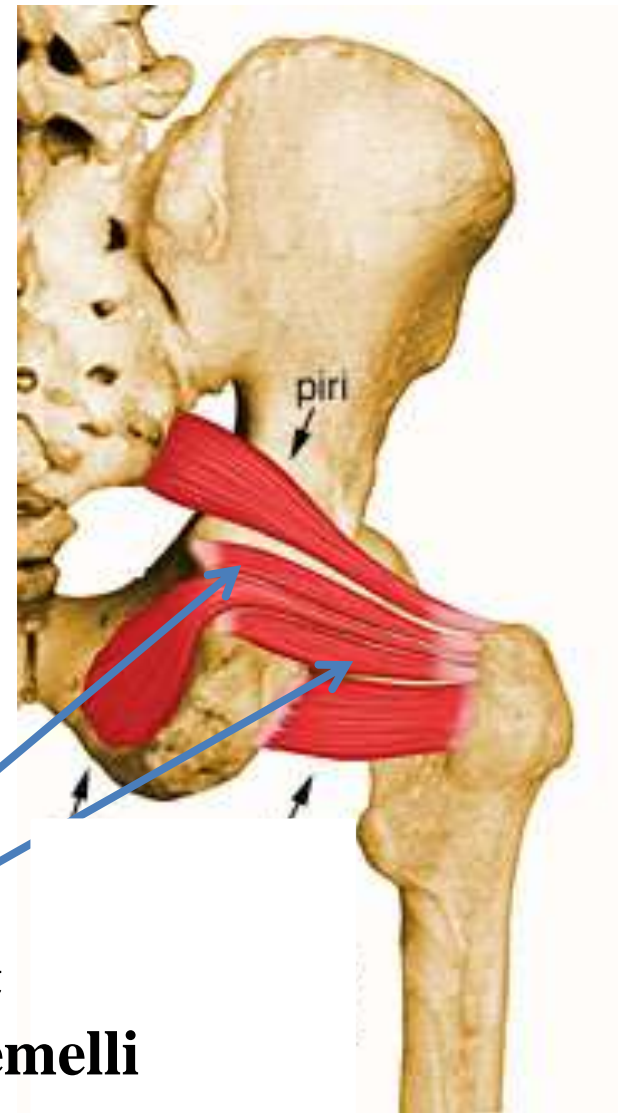


Obturator Internus



Gemellus superior

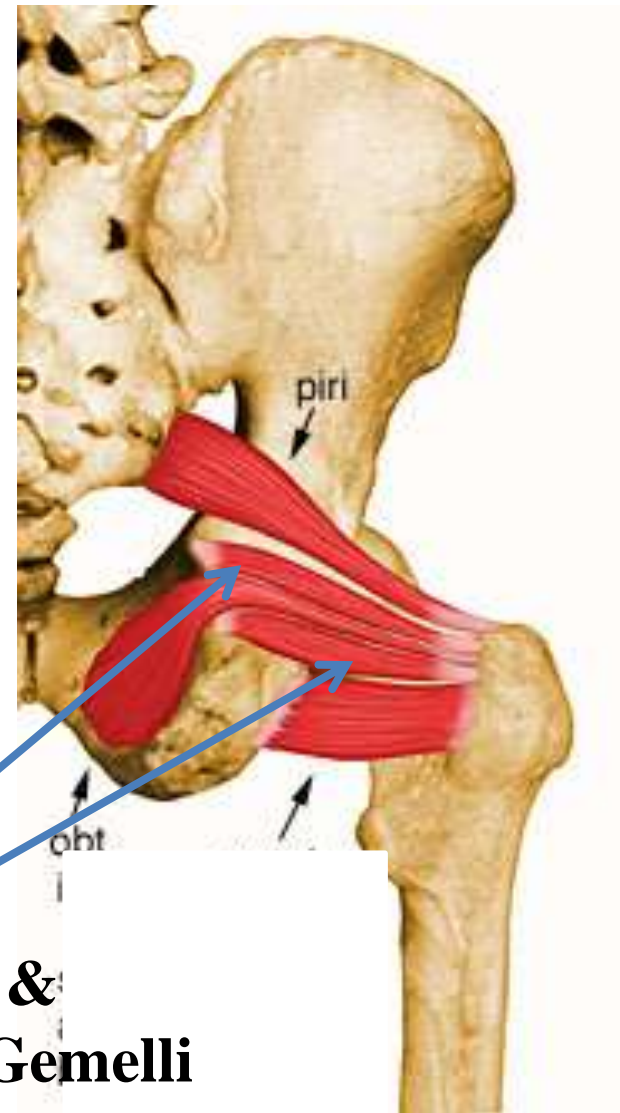
- **O**: Superior margin of lesser sciatic notch superior to obturator internus tendon
- **I**: medial side of greater trochanter of femur with obturator internus tendon
- **A**: Laterally rotates the extended femur at hip joint; abducts flexed femur at hip joint
- **N**: Nerve to obturator internus



**Superior &
Inferior Gemelli**

Gemellus Inferior

- **O**: Inferior margin of lesser sciatic notch inferior to obturator internus tendon
- **I**: medial side of greater trochanter of femur with obturator internus tendon
- **A**: Laterally rotates the extended femur at hip joint; abducts flexed femur at hip joint
- **N**: Nerve to quadratus femoris (L5,S1)

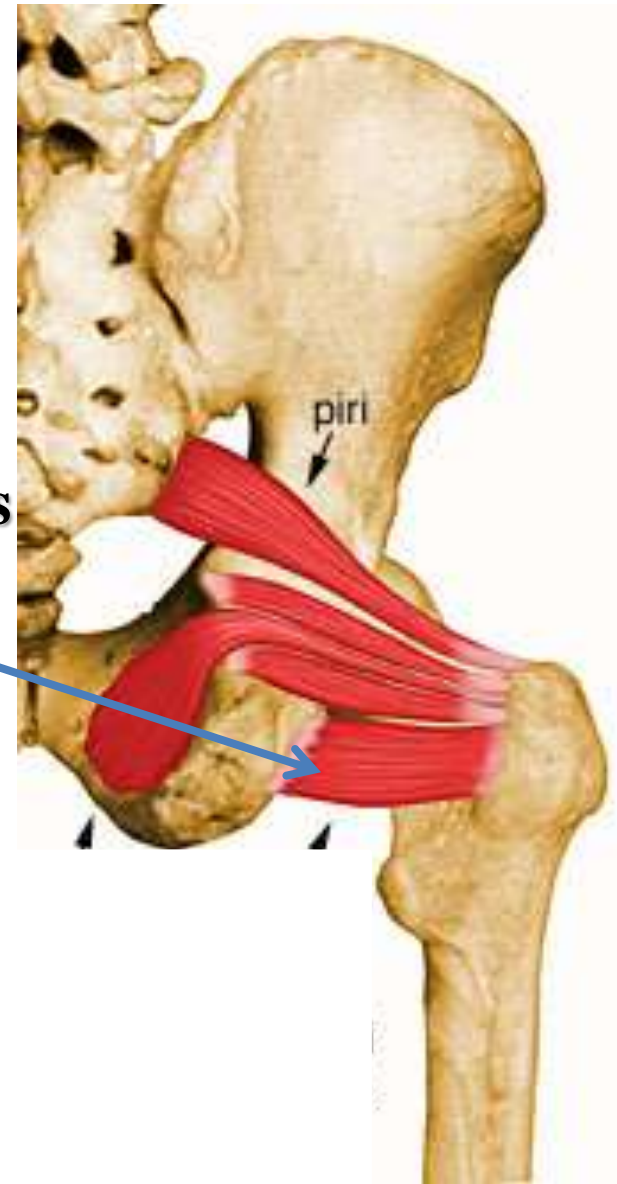


**Superior &
Inferior Gemelli**

Quadratus femoris

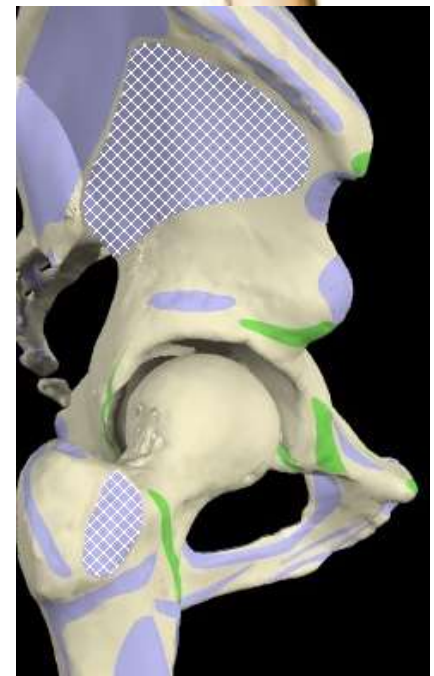
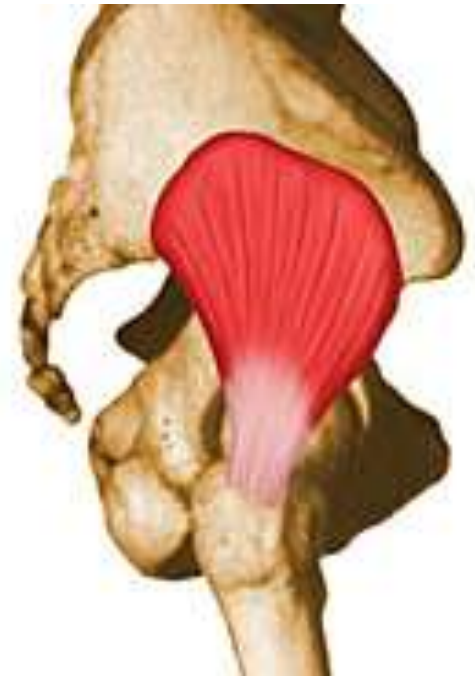- **O**: Lateral aspect of the ischium just anterior to the ischial tuberosity
- **I**: Quadrate tubercle and intertrochanteric crest
- **A**: Laterally rotates the extended femur at hip joint; abducts flexed femur at hip joint
- **N**: Nerve to quadratus femoris

Quadratus femoris



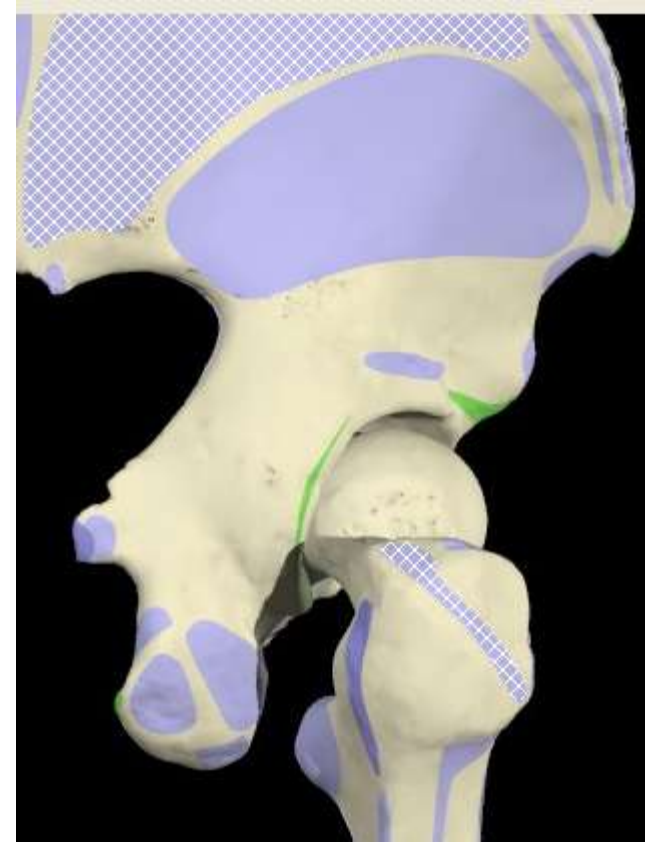
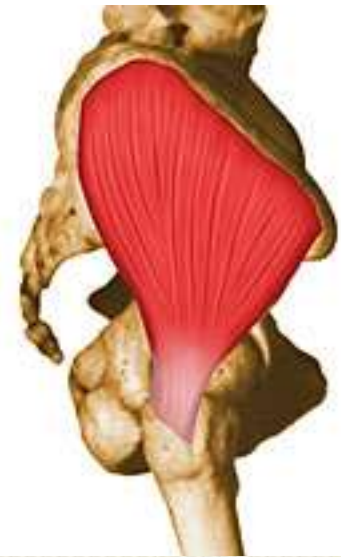Gluteus minimus

- **O**: External surface of ilium between inferior and anterior gluteal lines
- **I**: Linear facet on the anterolateral aspect of the greater trochanter
- **A**: 1. Abducts femur at hip joint. 2. holds pelvis secure over stance leg and prevents pelvic drop on the opposite swing side during walking. 3. medially rotates thigh
- **N**: Superior gluteal nerve



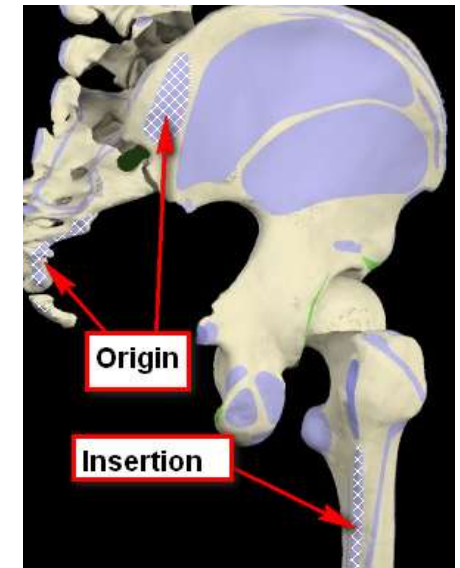
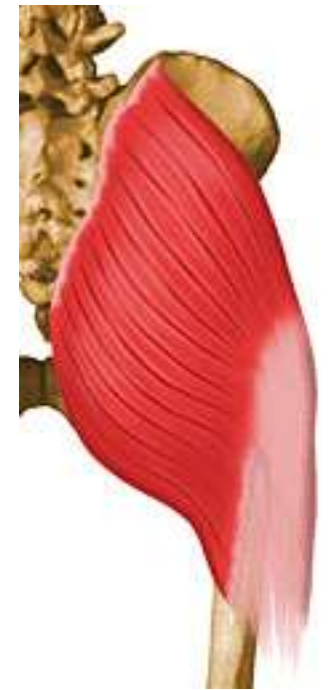Gluteus medius

- **O**: External surface of ilium between anterior and posterior gluteal lines
- **I**: facet on the lateral surface of the greater trochanter
- **A**: 1. Abducts femur at hip joint. 2. holds pelvis secure over stance leg and prevents pelvic drop on the opposite swing side during walking. 3. medially rotates thigh
- **N**: Superior gluteal nerve



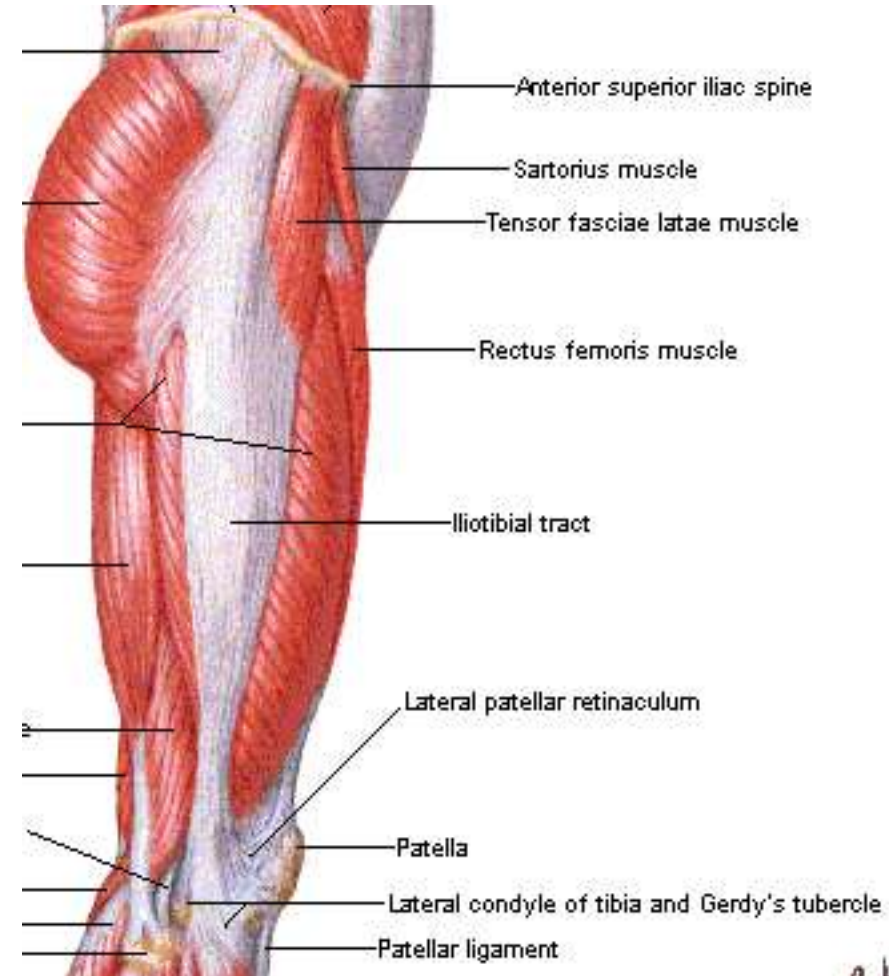
Gluteus maximus

- **O**: Fascia covering gluteus medius, external surface of ilium behind posterior gluteal line, fascia of erector spinae, dorsal surface of lower sacrum, lateral margin of coccyx, external surface of sacrotuberous ligament
- **I**: Gluteal tuberosity of the femur and the iliotibial tract
- **A**: Powerful extensor of flexed femur at hip joint; lateral stabilizer of hip joint and knee joint; laterally rotates and abducts thigh
- **N**: Inferior gluteal nerve



Tensor fasciae latae

- **O**: Lateral aspect of crest of ilium between anterior superior iliac spine and tubercle of the crest
- **I**: Iliotibial tract of fascia lata
- **A**: Stabilizes the knee in extension. Abducts the hip
- **N**: Superior gluteal nerve



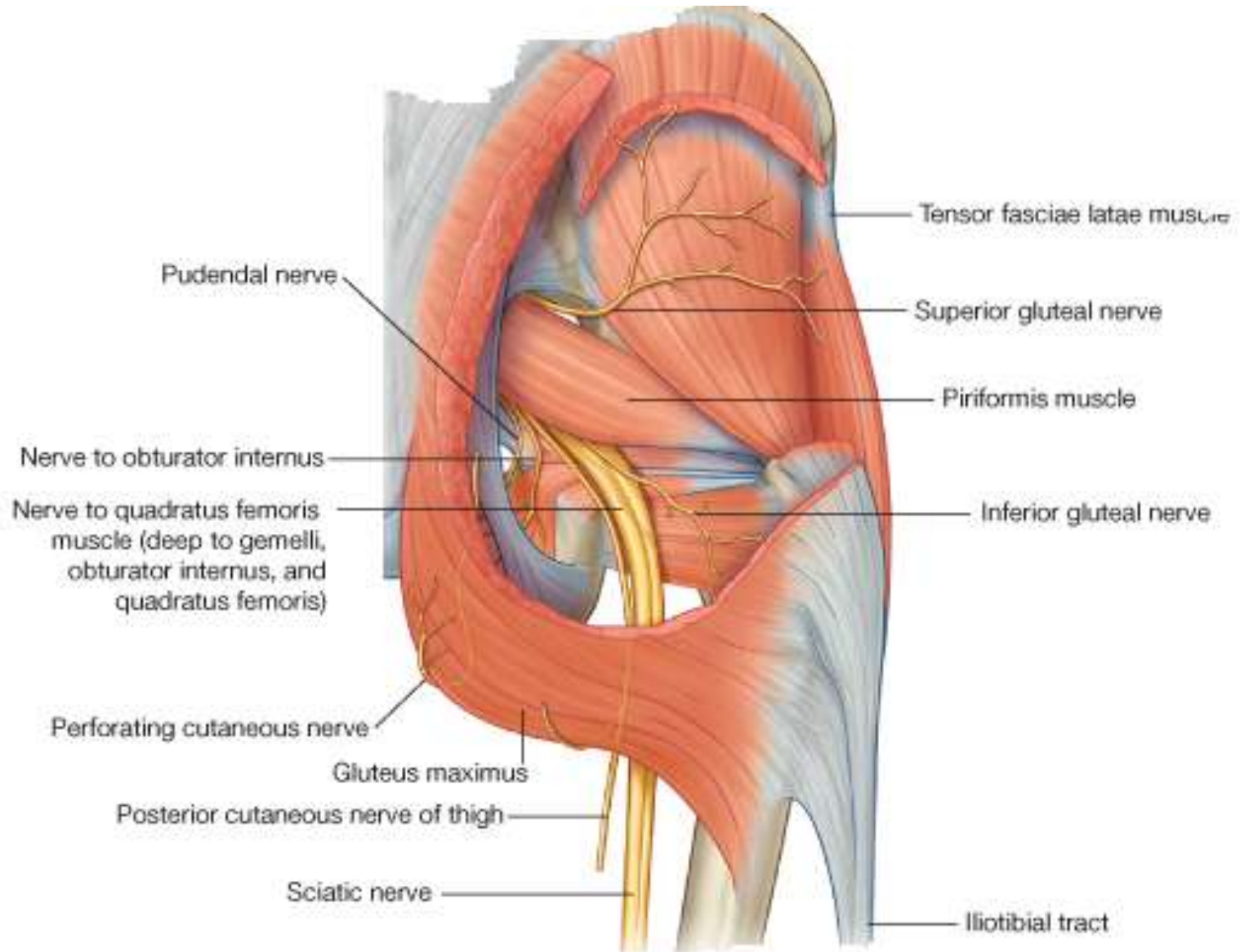
The Nerves

Seven nerves enter the gluteal region from the pelvis through the greater sciatic foramen

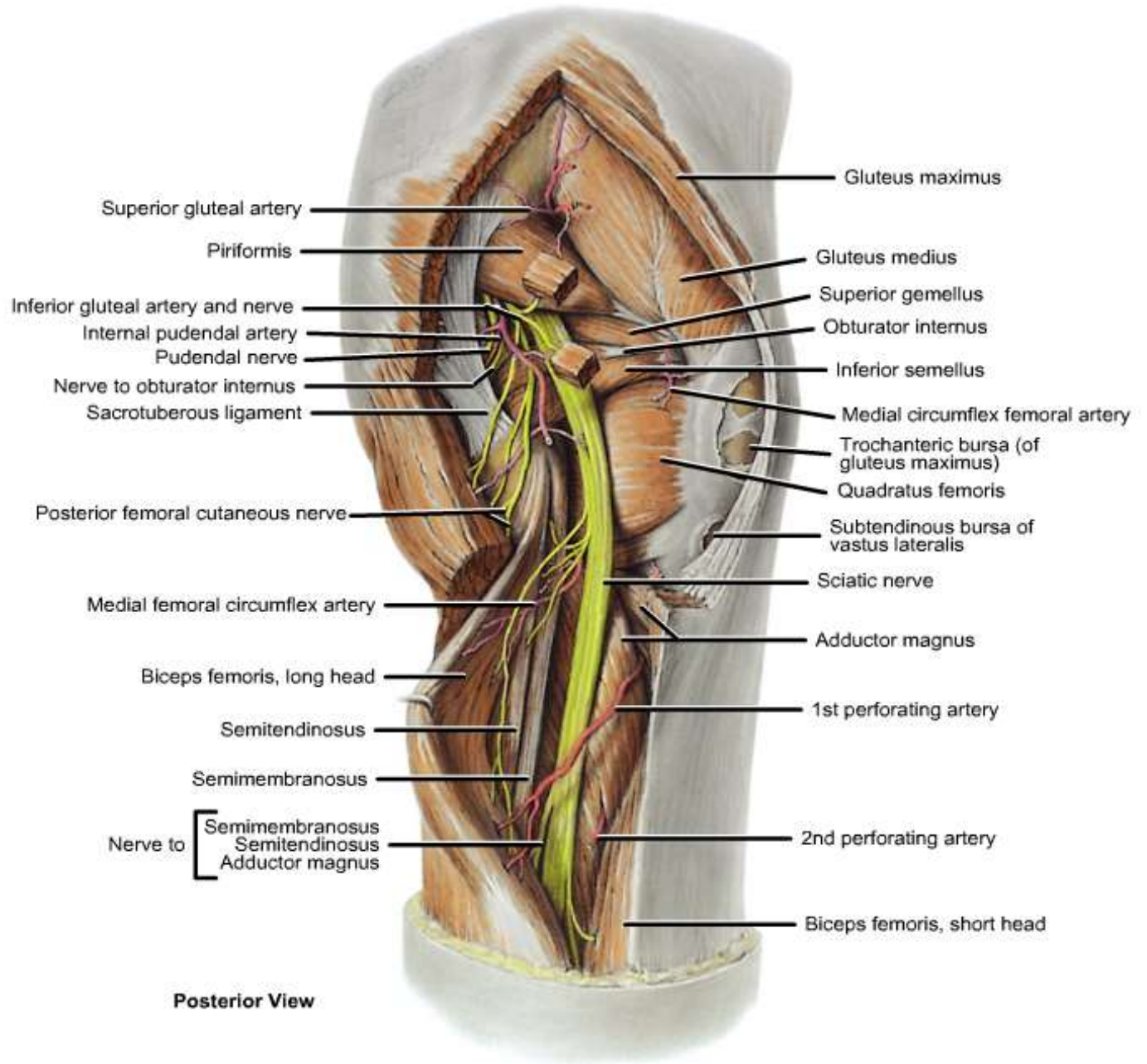
- I. The superior gluteal nerve
- II. Sciatic nerve
- III. Nerve to the quadratus femoris
- IV. Nerve to the obturator internus
- V. Posterior cutaneous nerve of the thigh
- VI. Pudendal nerve
- VII. Inferior gluteal nerve.

Finally, the the perforating cutaneous nerve pierces the sacrotuberous ligament

The Nerves



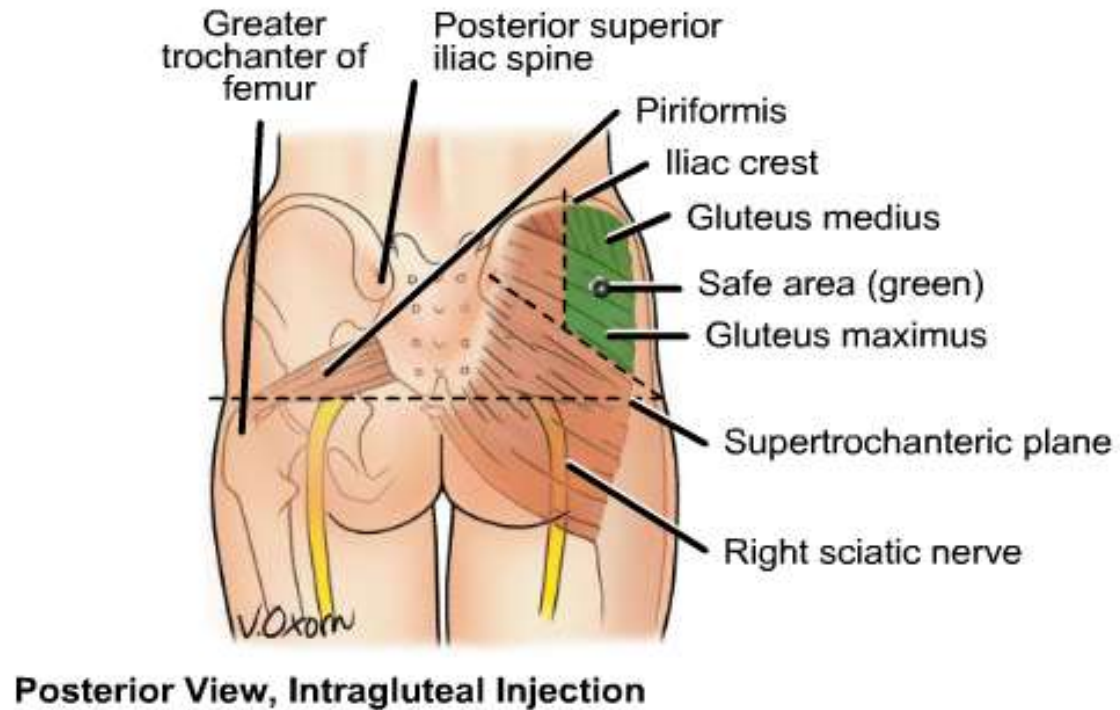
The Nerves



Posterior View

Safe Injection Area (Green)

- Divide the buttock into four
- The upper, lateral quadrant is the safest area to give injections
- You are more likely to injure the sciatic nerve in other areas



The Arteries

Two arteries:

- I. The inferior gluteal artery
- II. Superior gluteal artery
- III. Enters the gluteal region from the pelvic cavity through the greater sciatic foramen
- IV. Supplies the gluteal region and part of the posterior thigh

