

The Leg

Prof. Oluwadiya KS

www.oluwadiya.sitesled.com

Compartments of the leg

4 Four Compartments:

1. Anterior compartment

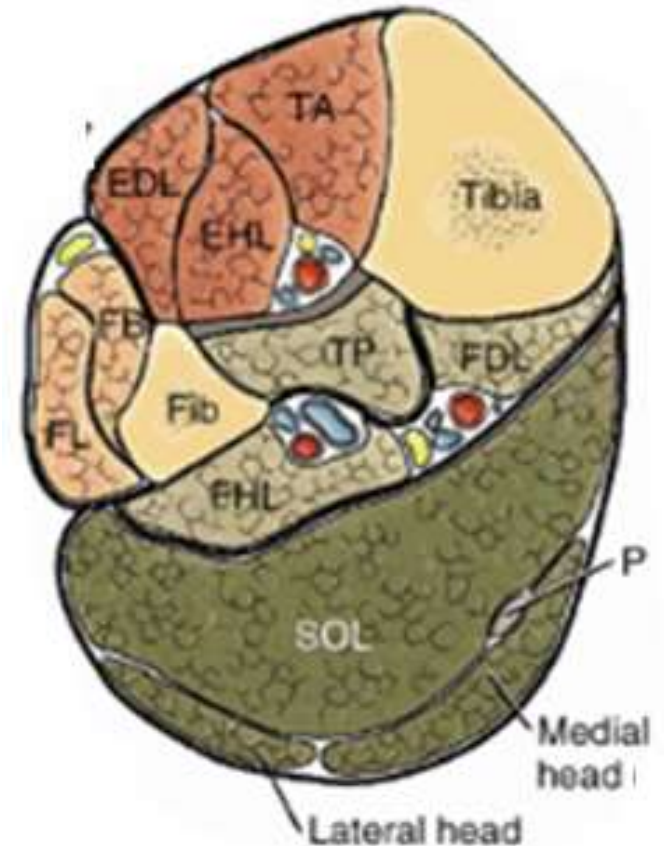
- Deep fibular nerve
- Dorsiflexes the foot and toes

2. Lateral Compartment

- Superficial fibular nerve
- Everts the foot

3&4. Superficial and Deep Posterior

- Tibial Nerve
- Plantar flexes the foot & toes

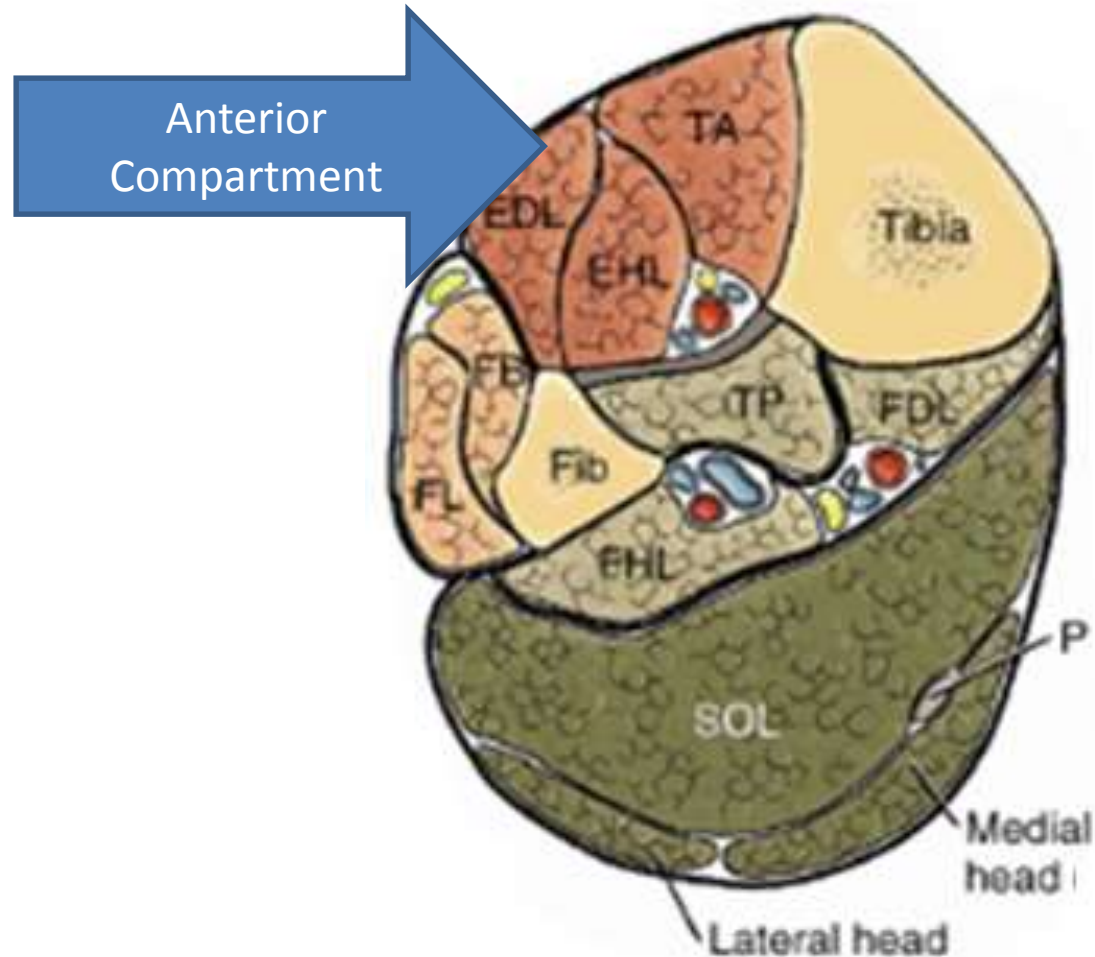


Muscles of the Leg

Anterior Compartment

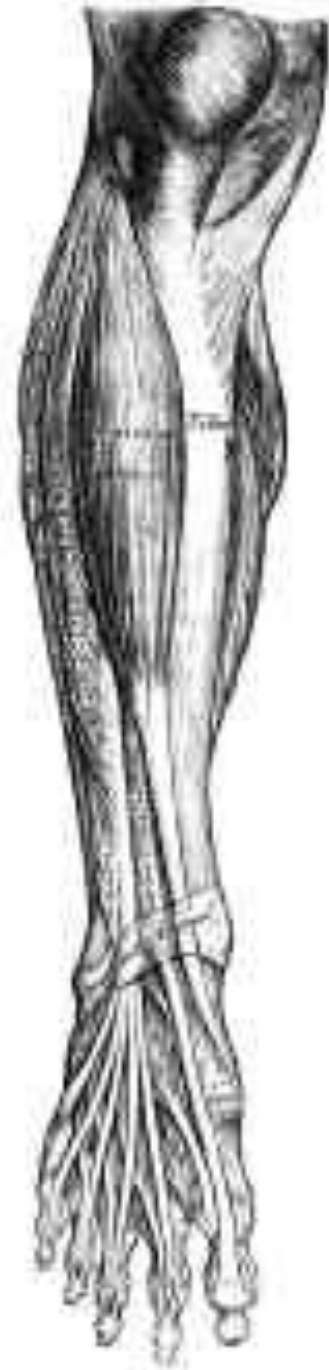– Borders

- Lateral surface of the shaft of Tibia
- Medial surface of the shaft of Fibula
- Interosseous membrane
- Deep fascia



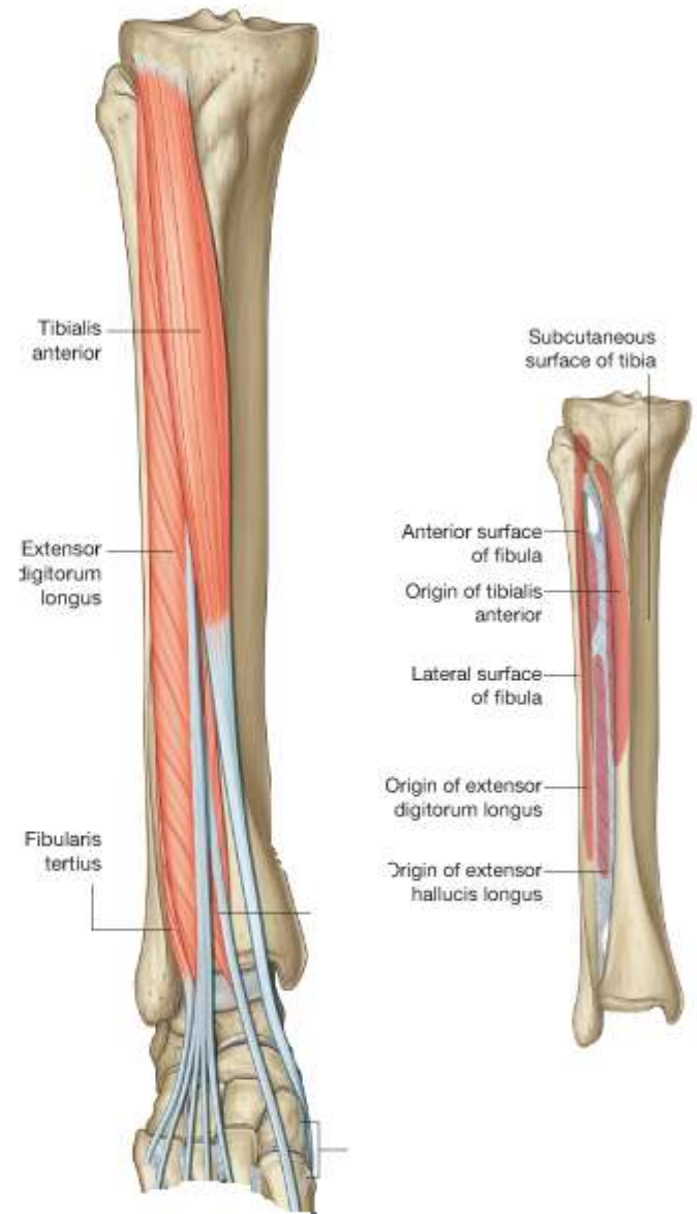
Structures in the Anterior Compartment

- i. Tibialis Anterior
- ii. Extensor Hallucis Longus
- iii. Extensor Digitorum Longus
- iv. Peroneus Tertius
- v. Deep Peroneal Nerve
- vi. Anterior Tibial Artery
- vii. Anterior Tibial Vein



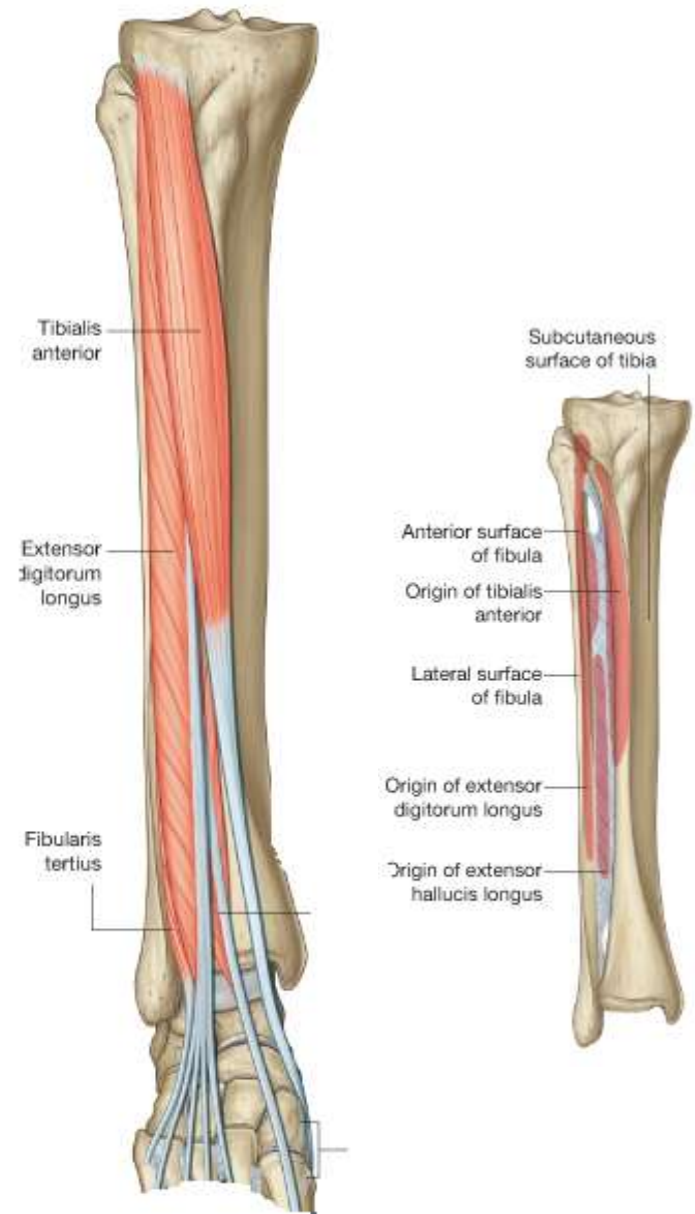
Tibialis Anterior

- O:** Lateral surface of tibia and adjacent interosseous membrane
- I:** Medial and inferior surfaces of medial cuneiform and adjacent surfaces on base of first metatarsal
- A:** Dorsiflexion of foot at ankle joint; inversion of foot; dynamic support of medial arch of foot
- N:** Deep fibular nerve



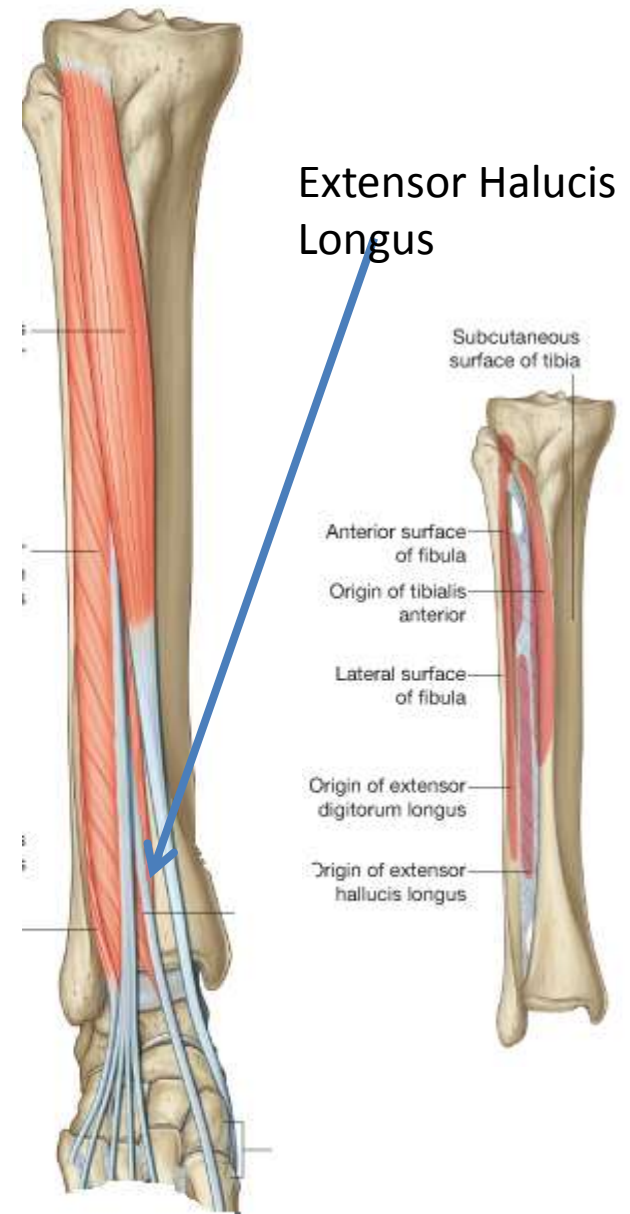
Extensor digitorum longus

- O:** Proximal one-half of medial surface of fibula and related surface of lateral tibial condyle
- I:** Via dorsal digital expansions into bases of distal and middle phalanges of lateral four toes
- A:** Extension of lateral four toes and dorsiflexion of foot
- N:** Deep fibular nerve



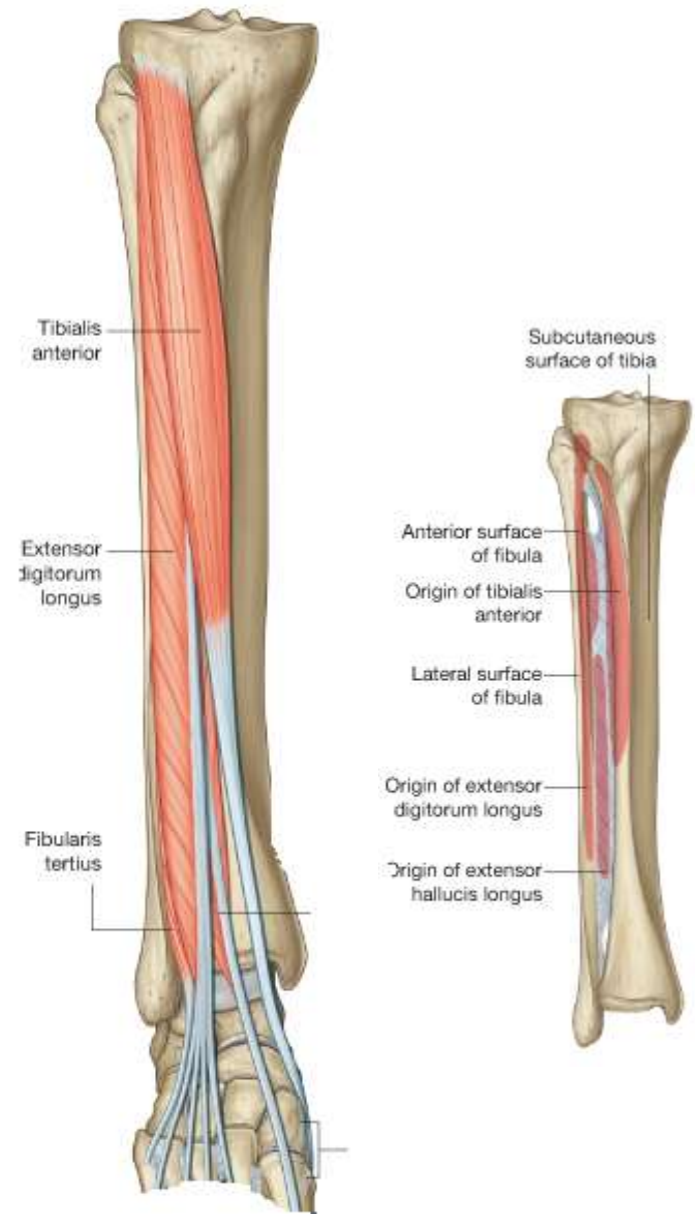
Extensor hallucis longus

- O**: Middle half of medial surface of fibula and adjacent interosseous membrane
- I**: Dorsal surface of base of distal phalanx of great toe
- A**: Extension of great toe and dorsiflexion of foot
- N**: Deep fibular nerve



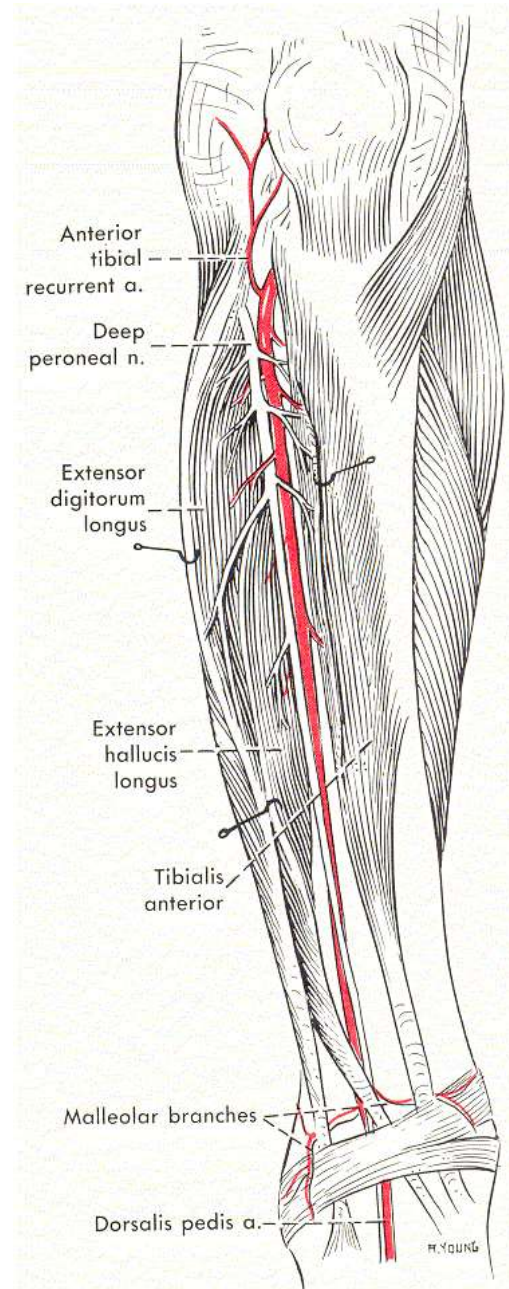
Fibularis tertius

- O**: Distal part of medial surface of fibula
- I**: Dorsomedial surface of base of metatarsal V
- A**: Dorsiflexion and eversion of foot
- N**: Deep fibular nerve



Arteries and Nerves of the anterior Compartment

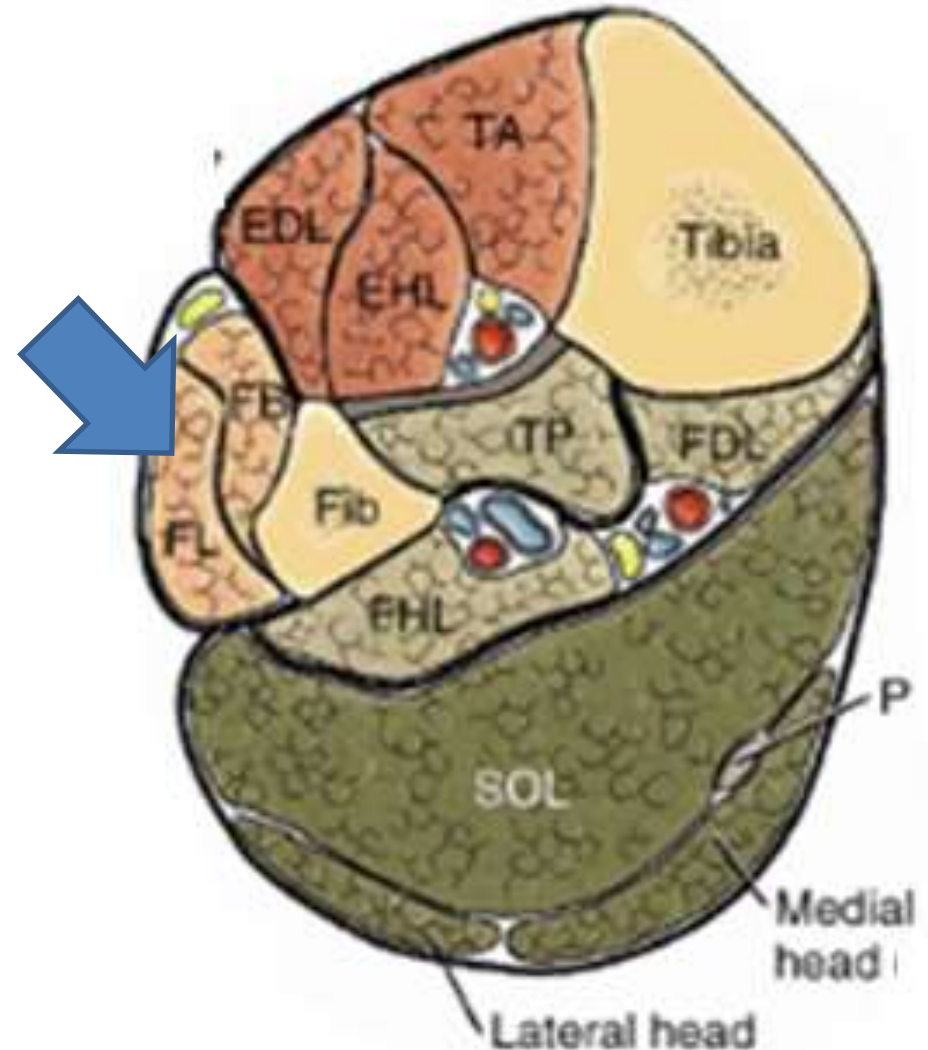
- Deep Fibula Nerve
- Anterior Tibial Artery
- Anterior Tibial Vein



Lateral Compartment

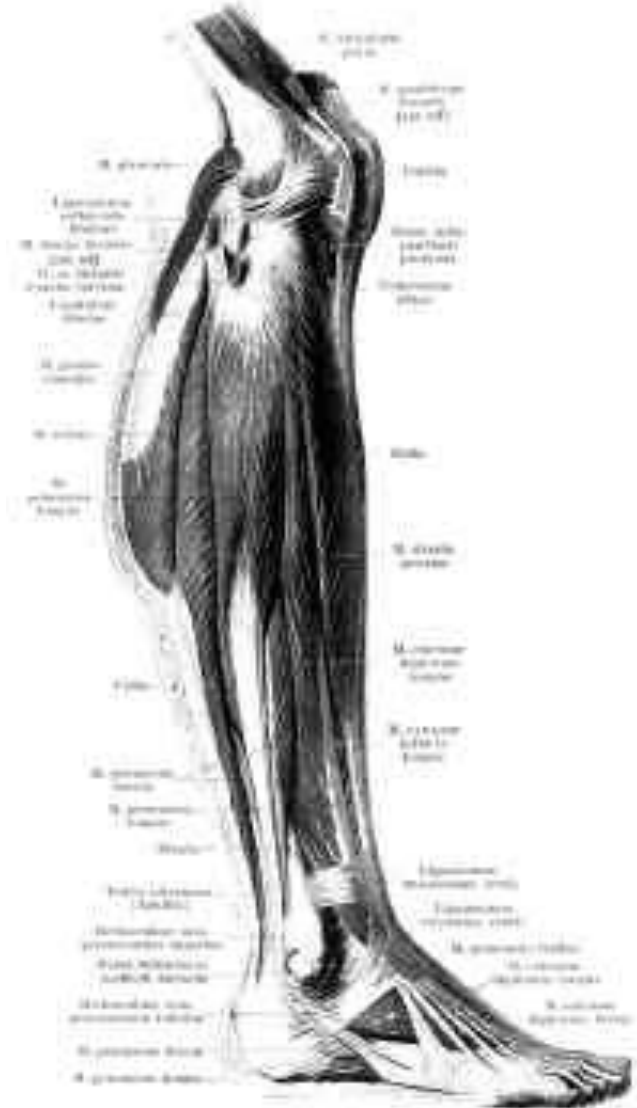
– Borders

- Lateral surface of the fibula
- Anterior intermuscular septum
- Posterior intermuscular septum
- Deep fascia
- It is the smallest compartment



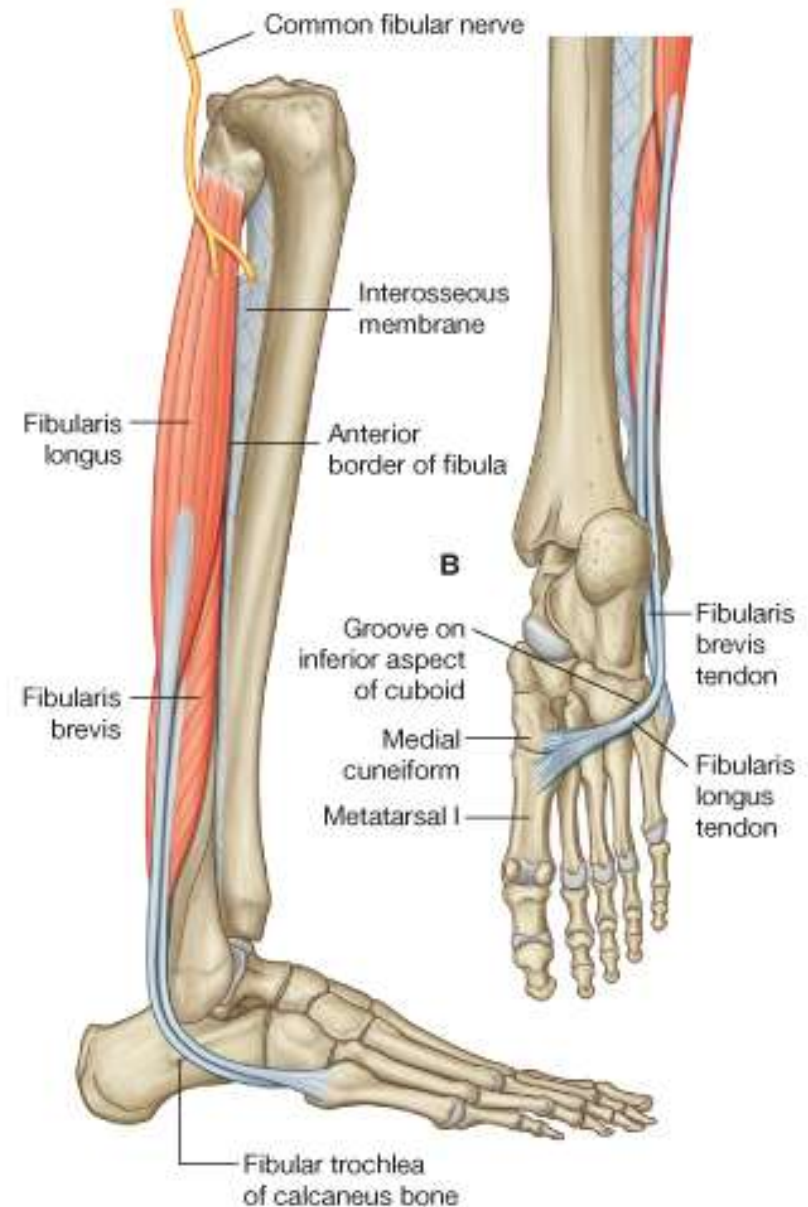
Structures in the Lateral Compartment

- Fibularis Longus
- Fibularis Brevis
- Superficial Fibular Nerve
- Fibular Artery
- Superior and Inferior Peroneal Retinaculum



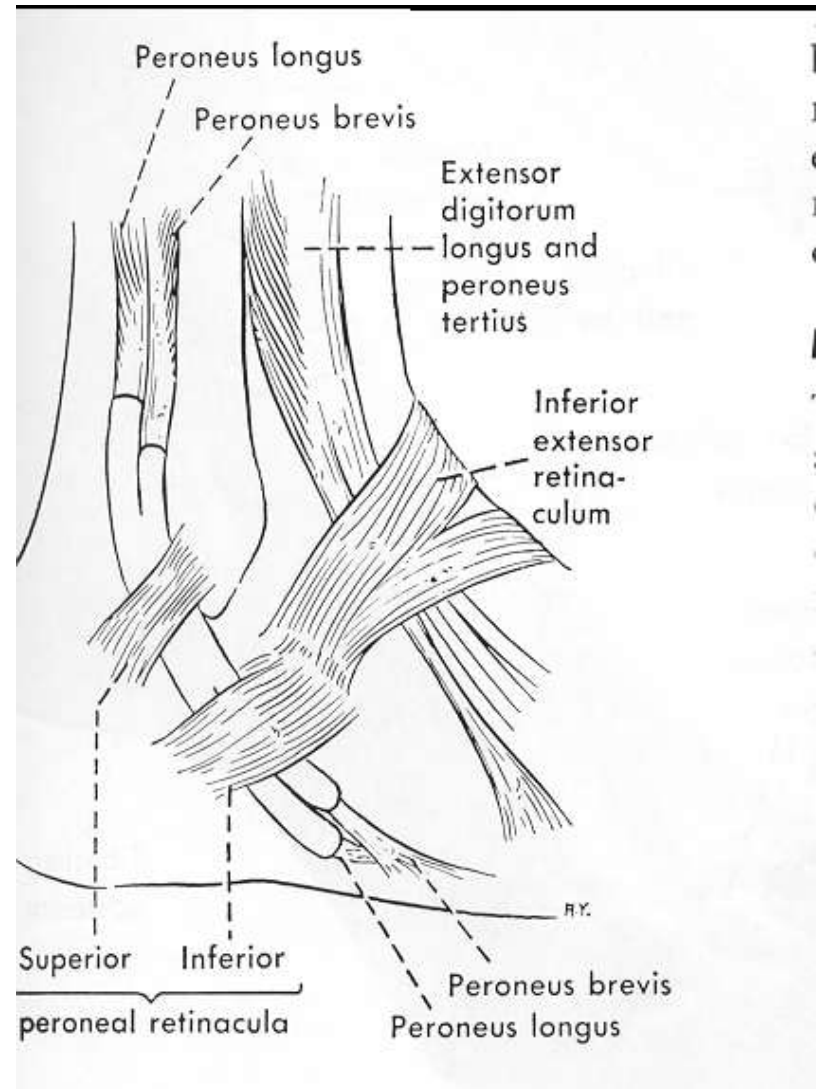
Fibularis Longus

- O**: Upper lateral surface of fibula, head of fibula and lateral tibial condyle
- I**: Undersurface of lateral sides of distal end of medial cuneiform and base of metatarsal I
- A**: Eversion and plantarflexion of foot; supports arches of foot
- N**: Superficial fibular nerve



Superior and Inferior peroneal retinaculum

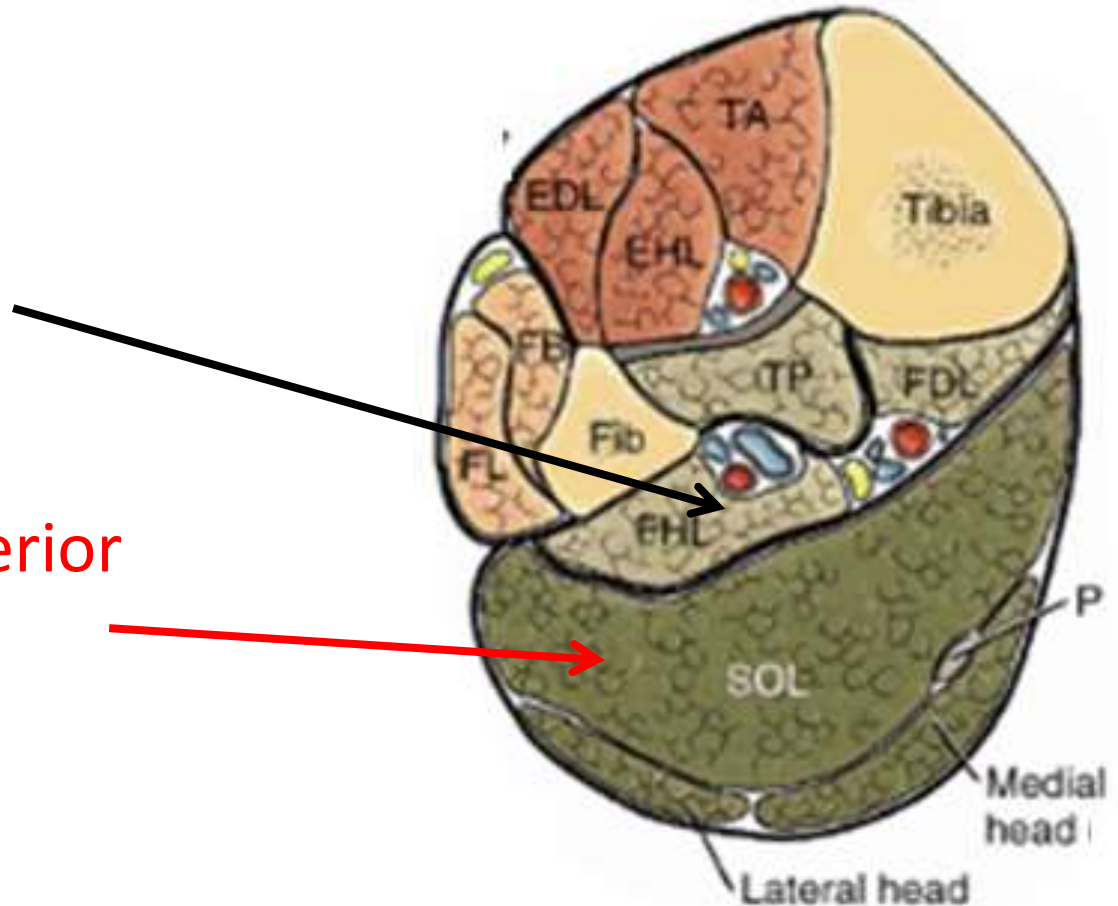
- Superior and Inferior Fibular (peroneal) Retinaculum



Posterior Compartment

Divided into two

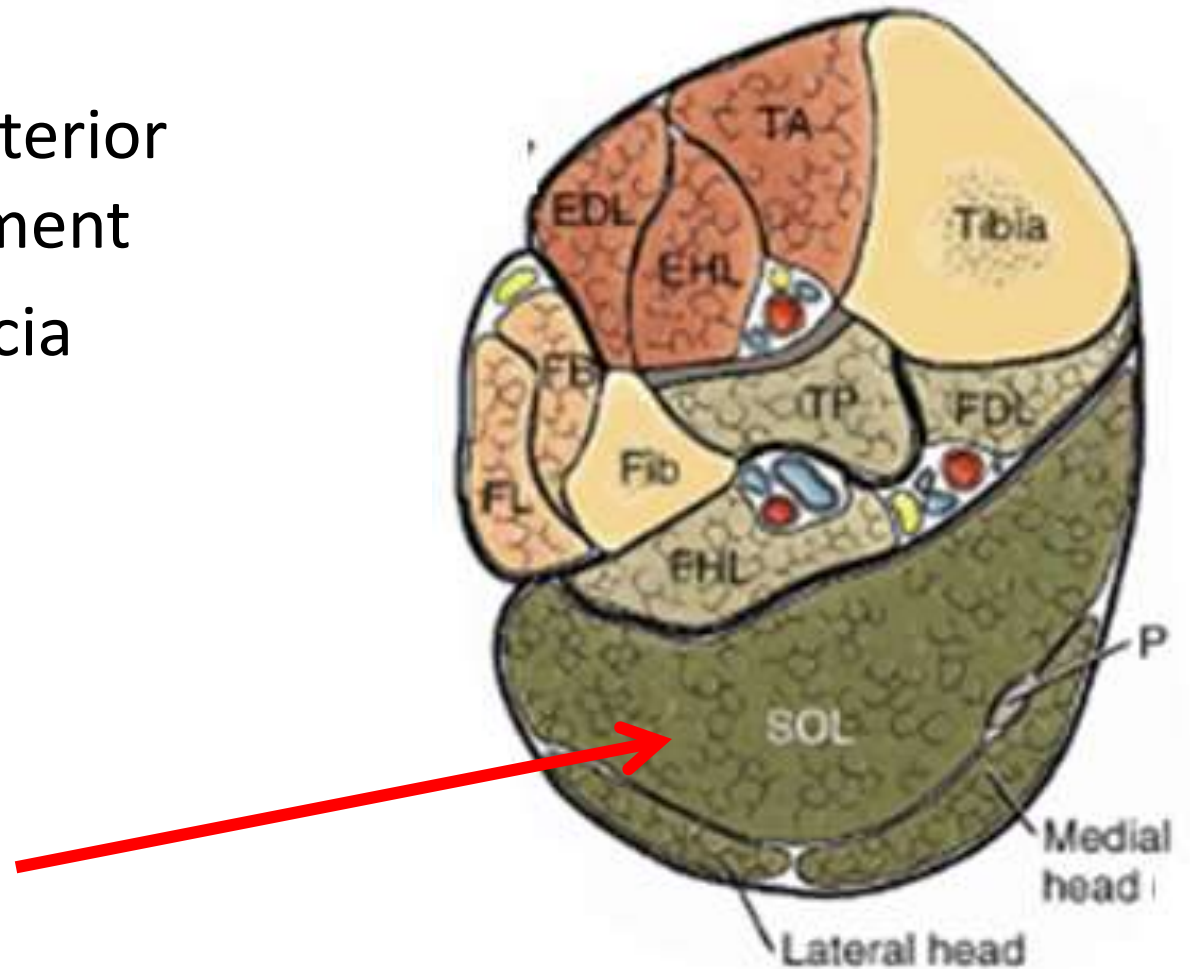
- Deep posterior compartment
- Superficial posterior compartment



Superficial Posterior Compartment

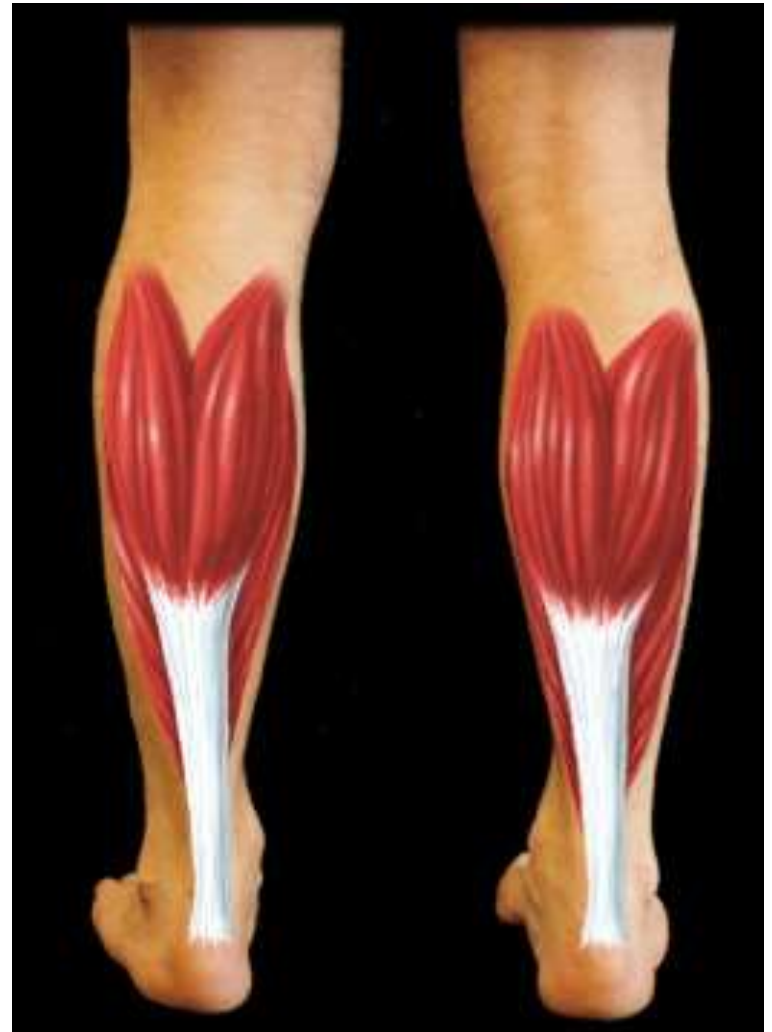– Borders

- Deep posterior compartment
- Deep Fascia



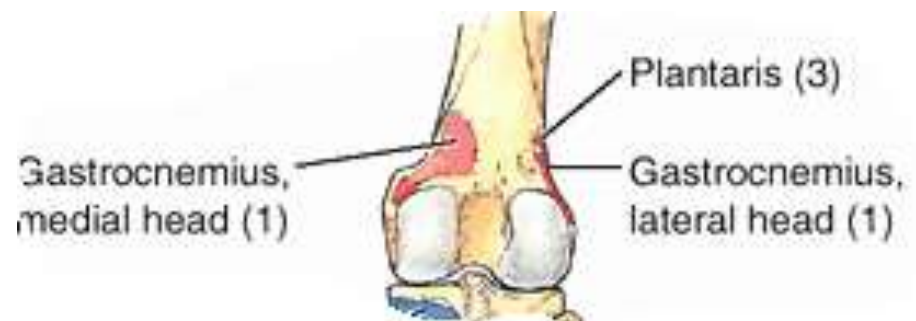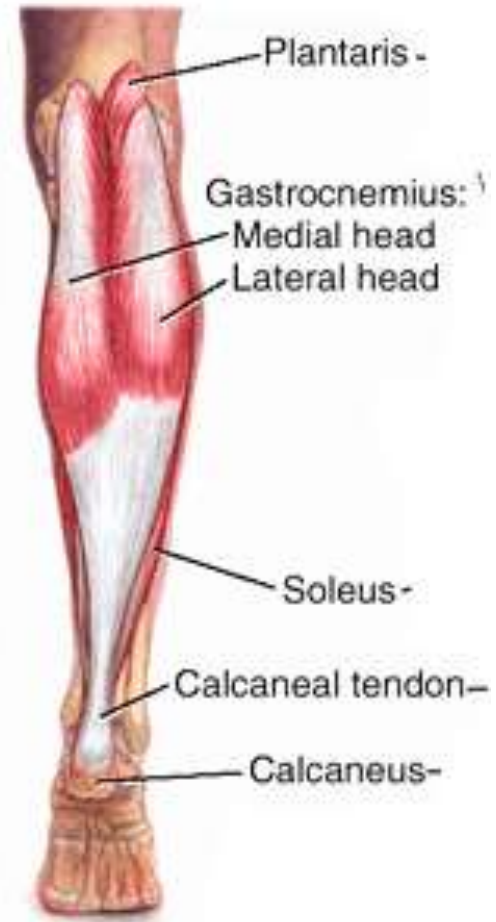Structures of the superficial Post. Compartment

- Soleus
- Gastrocnemius
- Plantaris
- Tibial Nerve
- Posterior Tibial Artery



Gastrocnemius

- O:** **Medial head**- Posterior surface of distal femur just superior to medial condyle;
Lateral head- Upper posterolateral surface of lateral femoral condyle
- I:** Via calcaneal tendon (tendo Achilles) to posterior surface of calcaneus
- A:** Plantarflexes foot and flexes knee
- N:** Tibia nerve



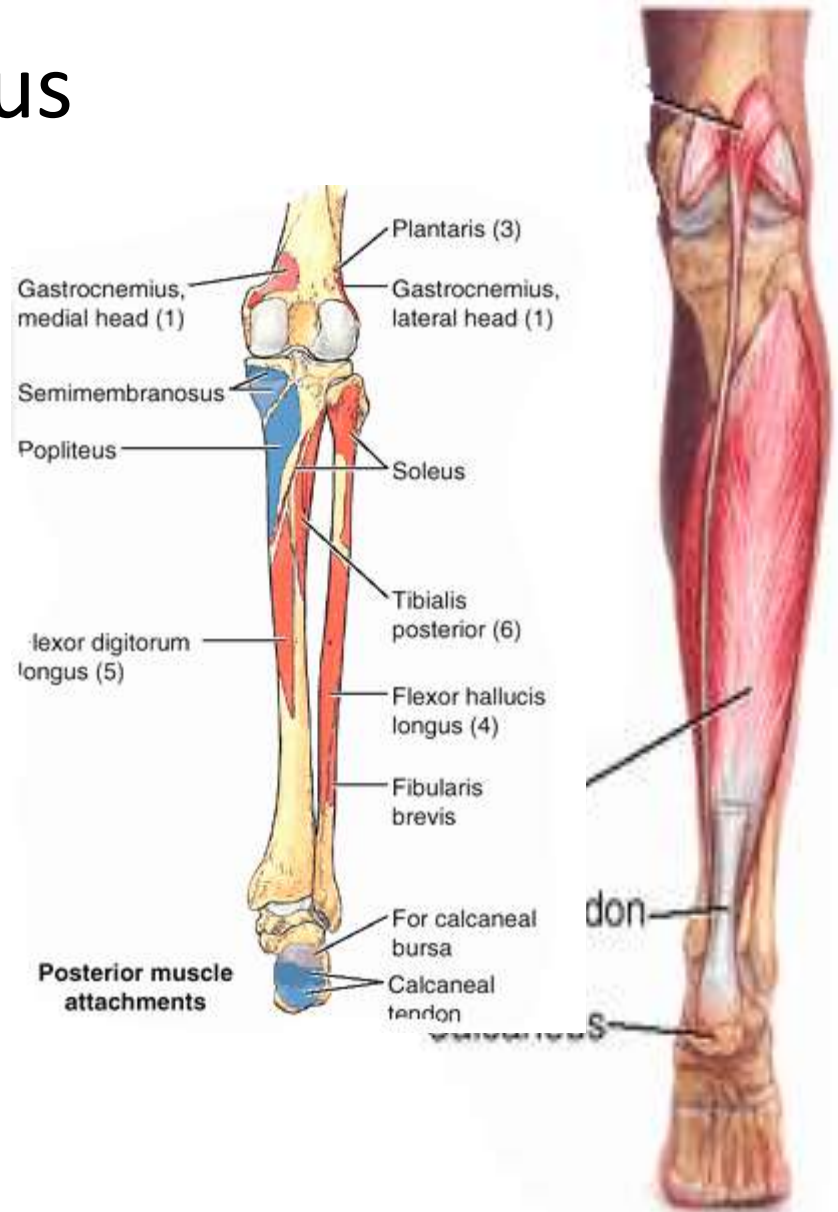
Soleus

O: Soleal line and medial border of tibia; posterior aspect of fibular head and adjacent surfaces of neck and proximal shaft; tendinous arch between tibial and fibular attachments

I: Via calcaneal tendon, to posterior surface of calcaneus

A: Plantarflexes the foot

N: Tibia nerve



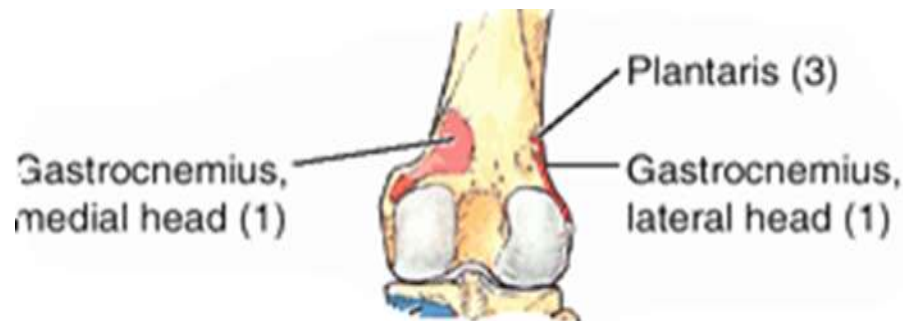
Plantaris

O: Inferior part of lateral supracondylar line of femur and oblique popliteal ligament of knee

I: Via calcaneal tendon, to posterior surface of calcaneus

A: Plantarflexes foot and flexes knee

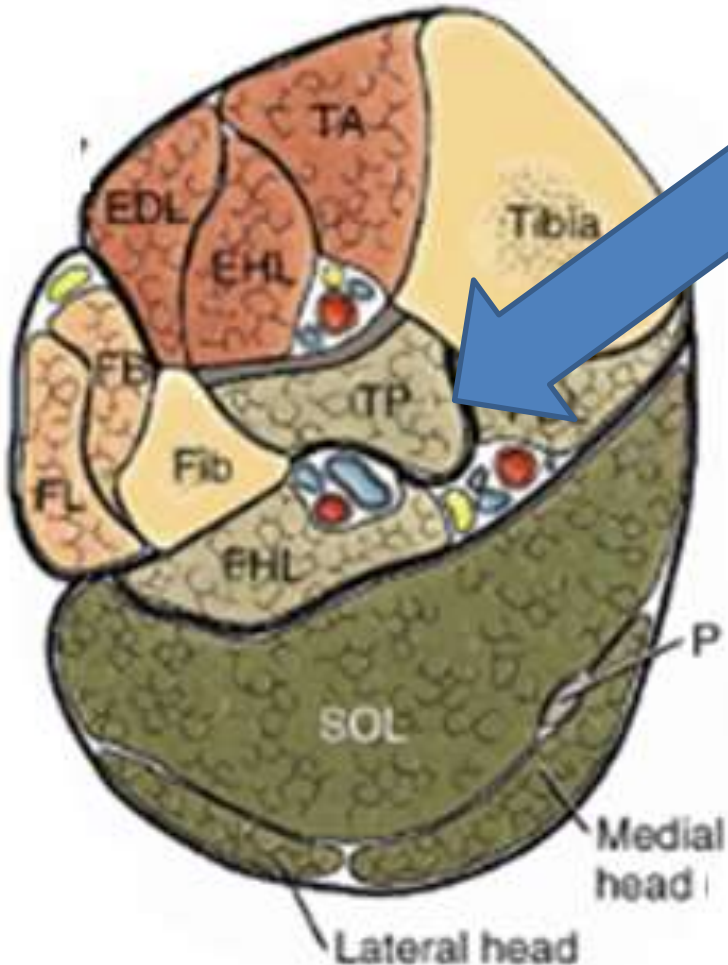
N: Tibia nerve



Deep Posterior Compartment

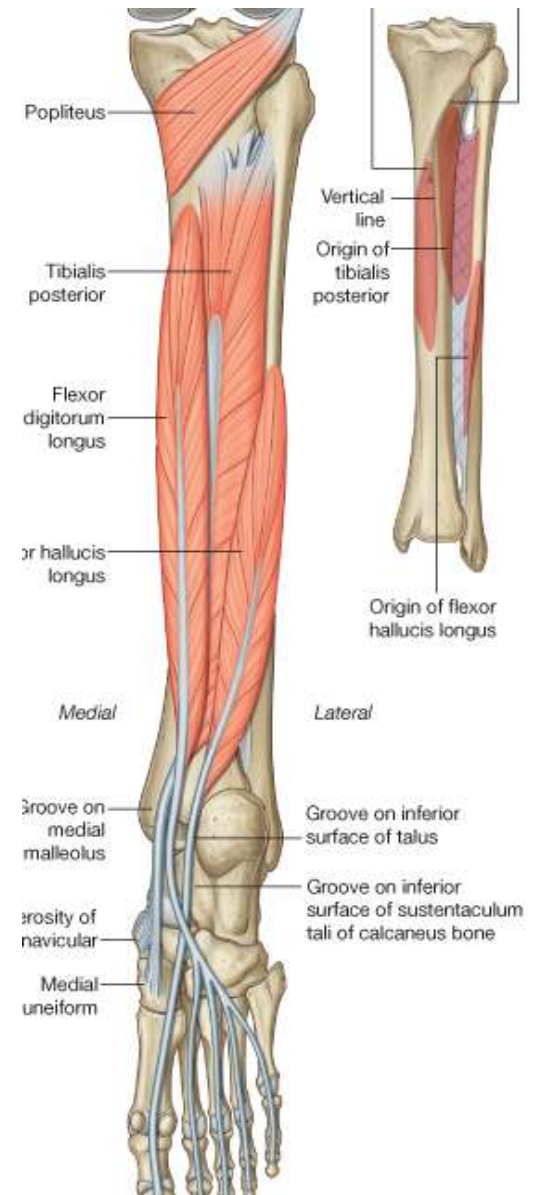
- **Borders**

- Interosseus Membrane
- Posterior surface of tibia
- Posterior surface of the fibula
- Superficial Posterior Compartment



Structures in the Deep posterior Compartment

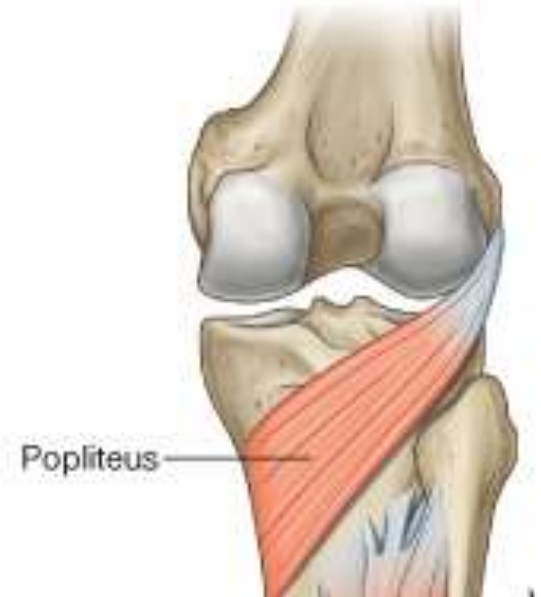
- Popliteus
- Tibialis Posterior
- Flexor Digitorum Longus
- Flexor Hallucis Longus
- Tibial Nerve
- Posterior Tibial Artery



Popliteus

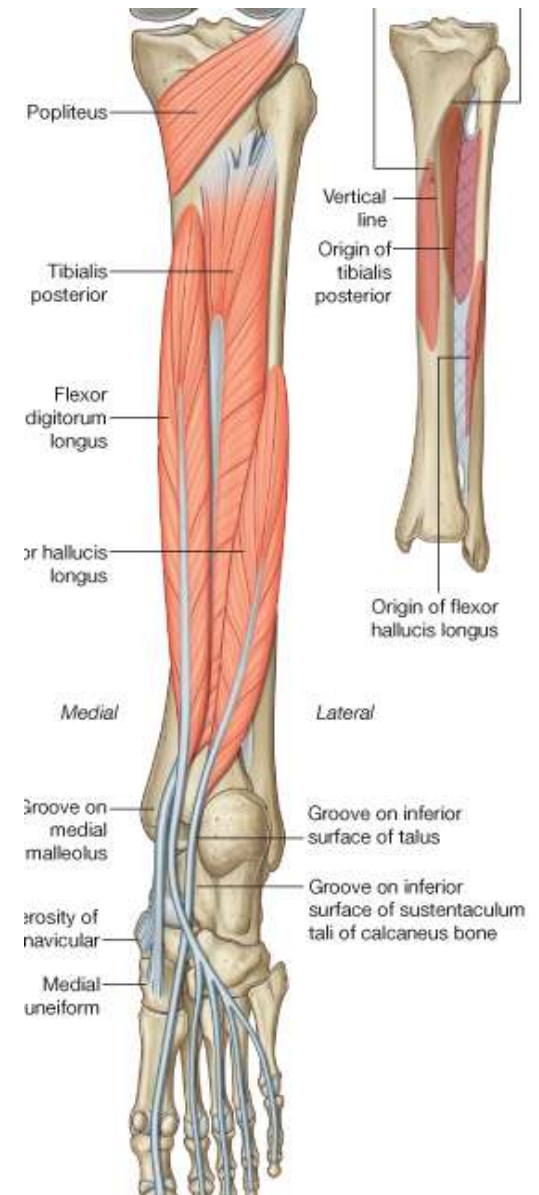
- O:** Posterior surface of proximal tibia above soleal line
- I:** Lateral femoral condyle
- A:** Unlocks knee joint (laterally rotates femur on fixed tibia)
- N:** Tibia nerve

The popliteus muscle forms part of the floor of the popliteal fossa



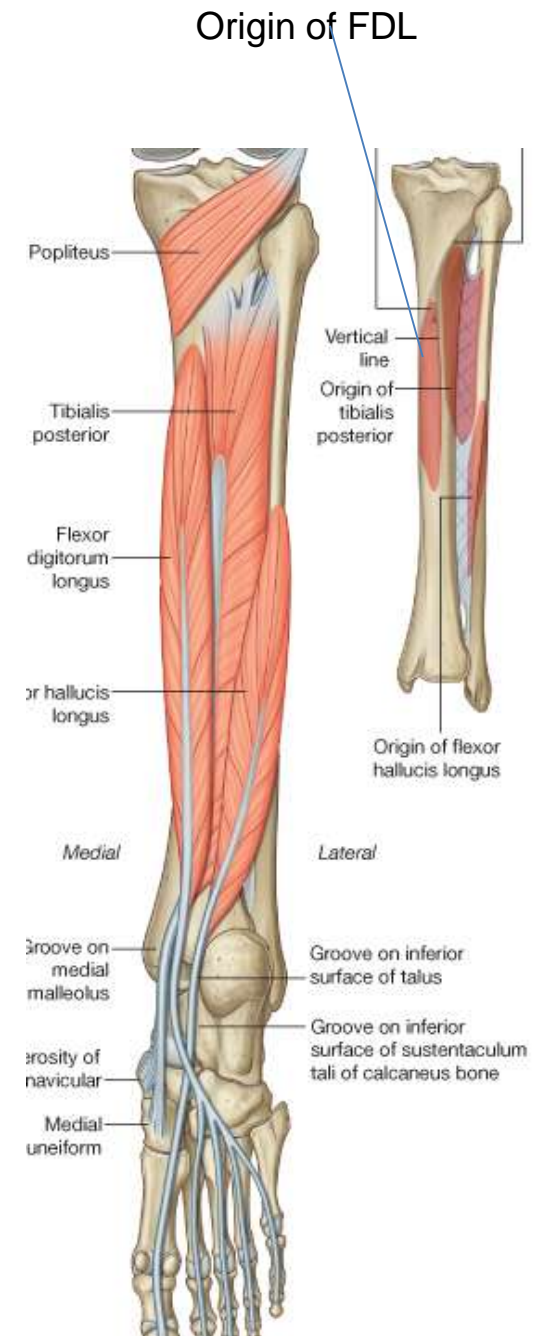
Flexor hallucis longus

- O:** Posterior surface of fibula and adjacent interosseous membrane
- I:** Plantar surface of distal phalanx of great toe
- A:** Flexes great toe and the foot
- N:** Tibia nerve



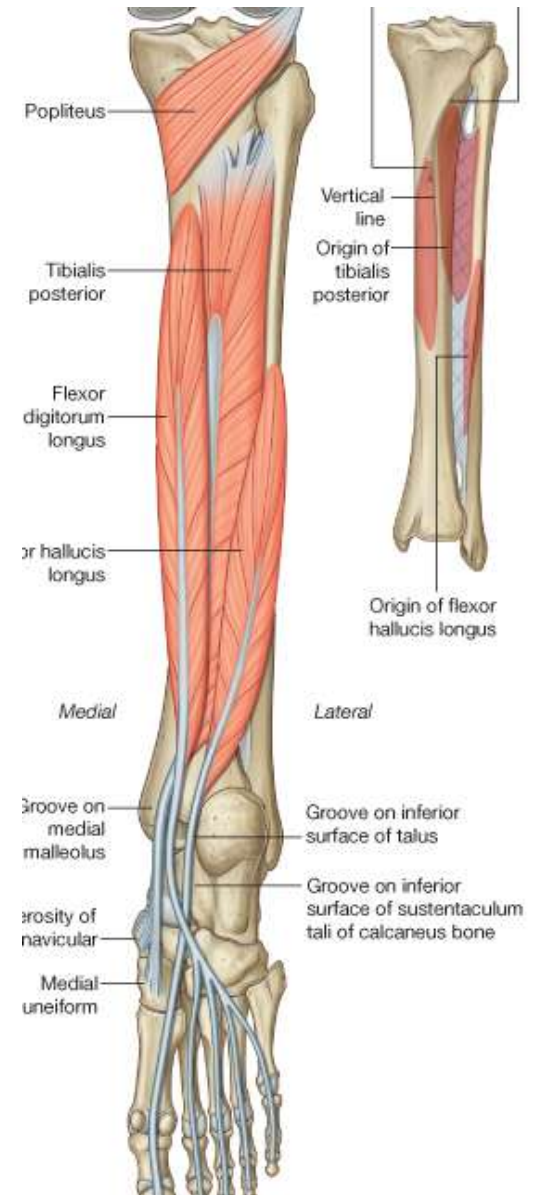
Flexor digitorum longus

- O:** Medial side of posterior surface of the tibia
- I:** Plantar surfaces of bases of distal phalanges of the lateral four toes
- A:** Flexes lateral four toes
- N:** Tibia nerve



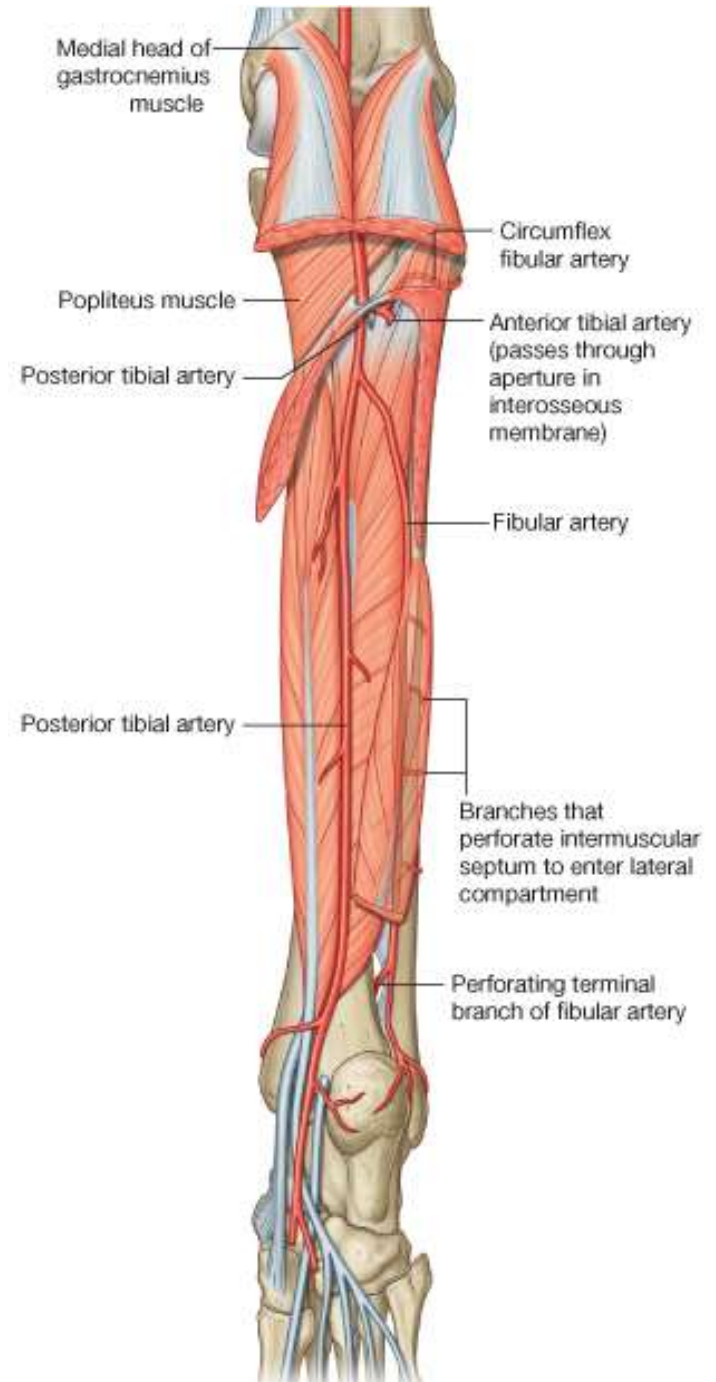
Tibialis Posterior

- O:** Posterior surfaces of interosseous membrane and adjacent regions of tibia and fibula
- I:** Mainly to tuberosity of navicular and adjacent region of medial cuneiform
- A:** Inversion and plantarflexion of foot; support of medial arch of foot during walking
- N:** Tibia nerve



Arterial supply of the leg

- Popliteal divides into:
 - i. Anterior tibial
 - ii. Posterior tibial
- Anterior tibial supplies the anterior compartment
- Posterior gives branches:
 - i. Fibula artery
 - ii. Circumflex fibula artery
 - iii. Muscular branches



The nerves

- Sciatic nerve becomes:
 - i. Tibial nerve which supplies the posterior compartment
 - ii. Common Fibular nerve which supplies the anterior and lateral compartments

