

# Introduction to the pelvis and the pelvic peritoneum

Prof. Oluwadiya Kehinde Sunday

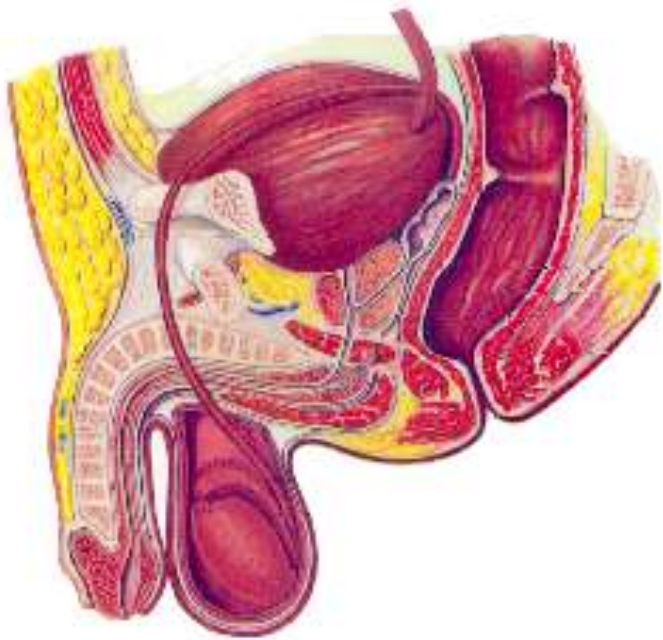
[www.oluwadiya.com](http://www.oluwadiya.com)

# The pelvis

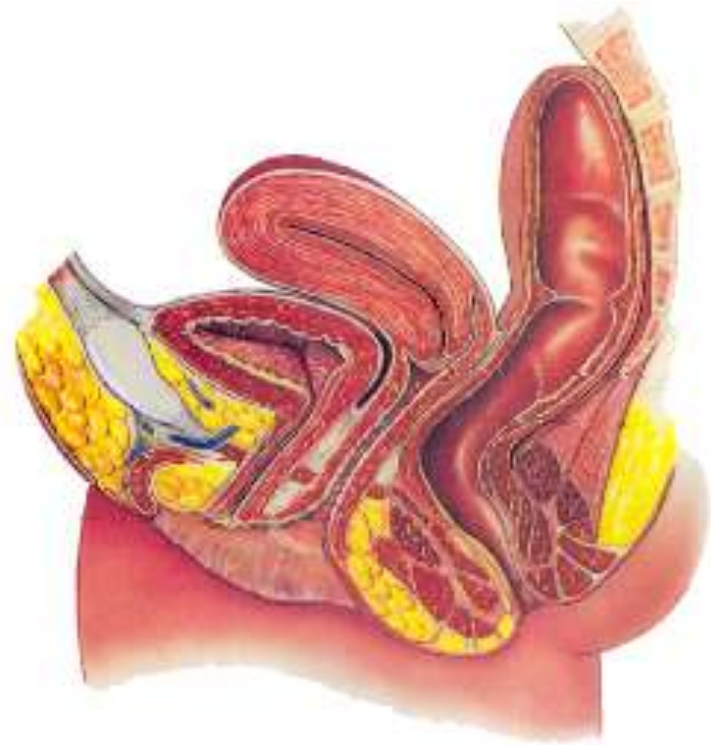
- Attaches lower limbs to the spine
- Supports visceral organs
- Attaches to the axial skeleton by strong ligaments
- Different in males and females in terms of structure and contents

# The pelvic viscera

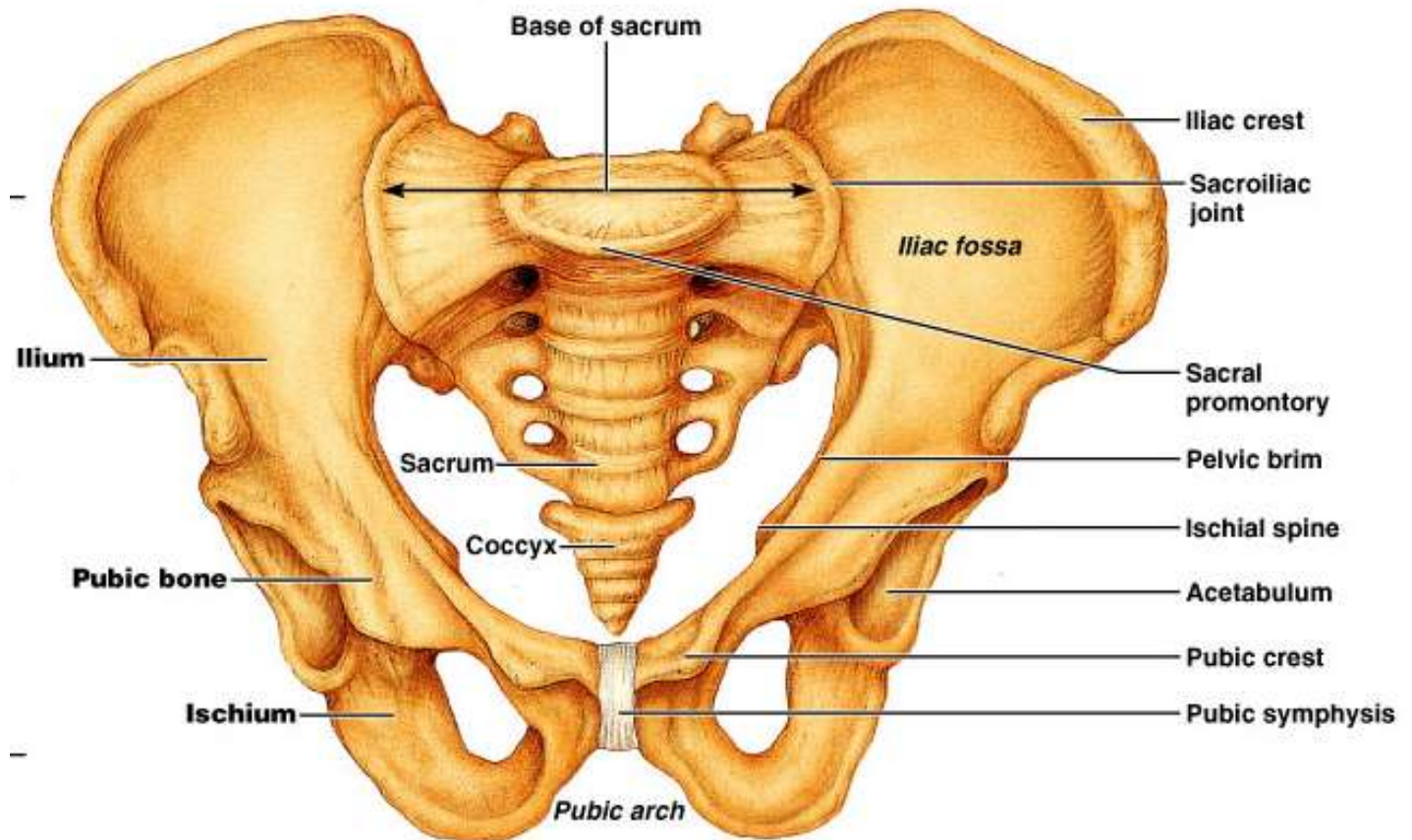
**Male pelvic viscera**



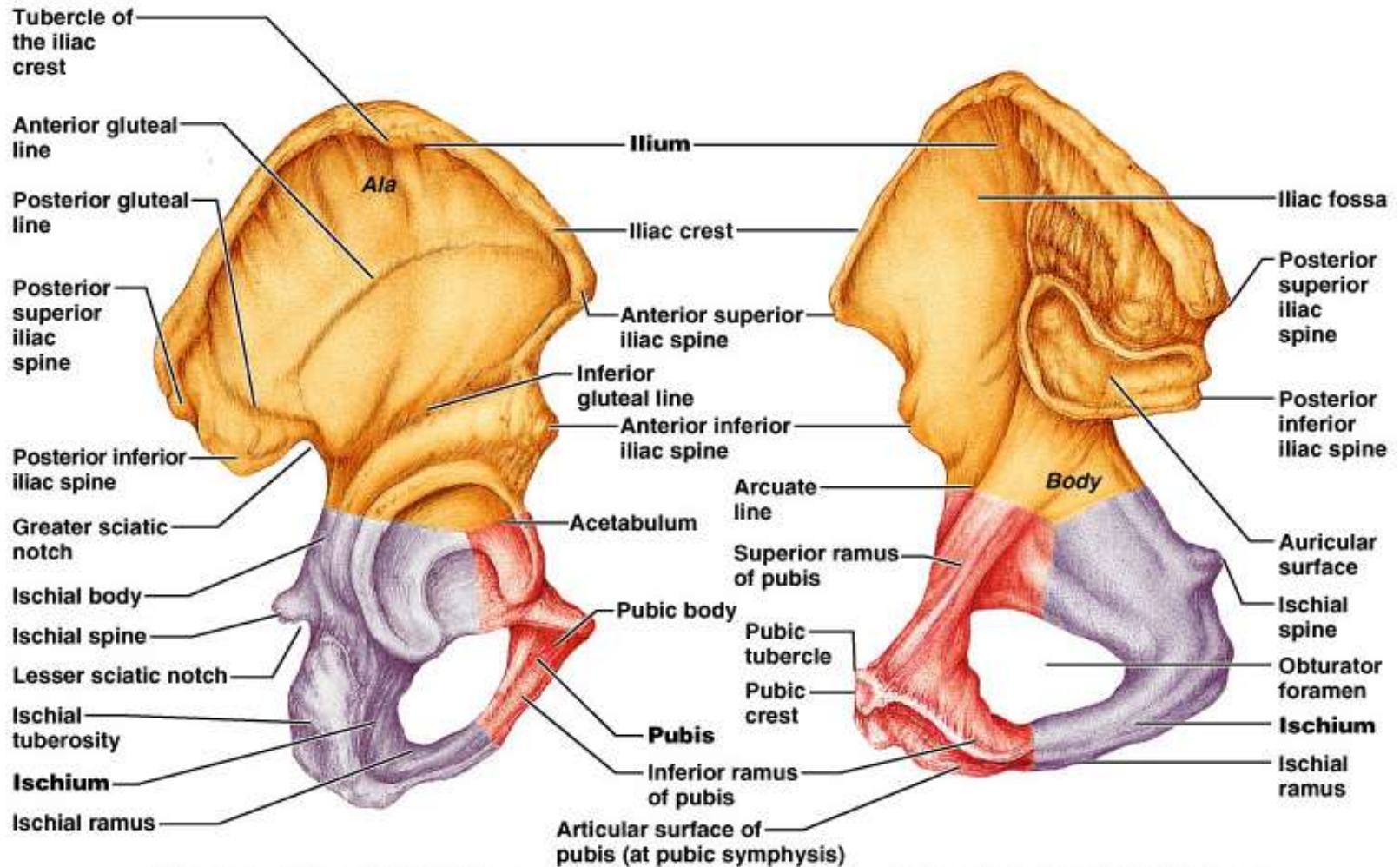
**Female pelvic viscera**



# The bones of the pelvis



# Bones of the pelvis



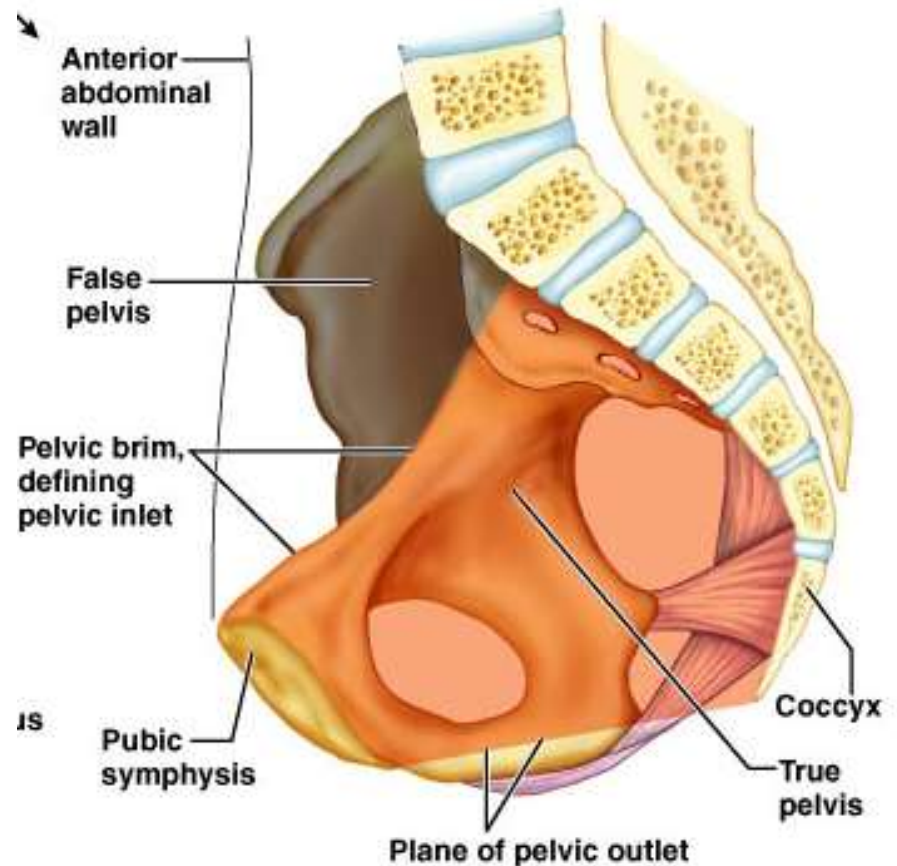
**(b) Lateral view, right hip bone**

**(c) Medial view, right hip bone**



# Divisions of the bony pelvis


- divided two regions by the pelvic brim (inlet)
  - False (greater) pelvis – bounded by the iliac bones
  - True (lesser) pelvis – inferior to pelvic brim
    - The true pelvis forms a bowl containing the pelvic organs



(b)

# Pelvis

**False pelvis  
(major)**

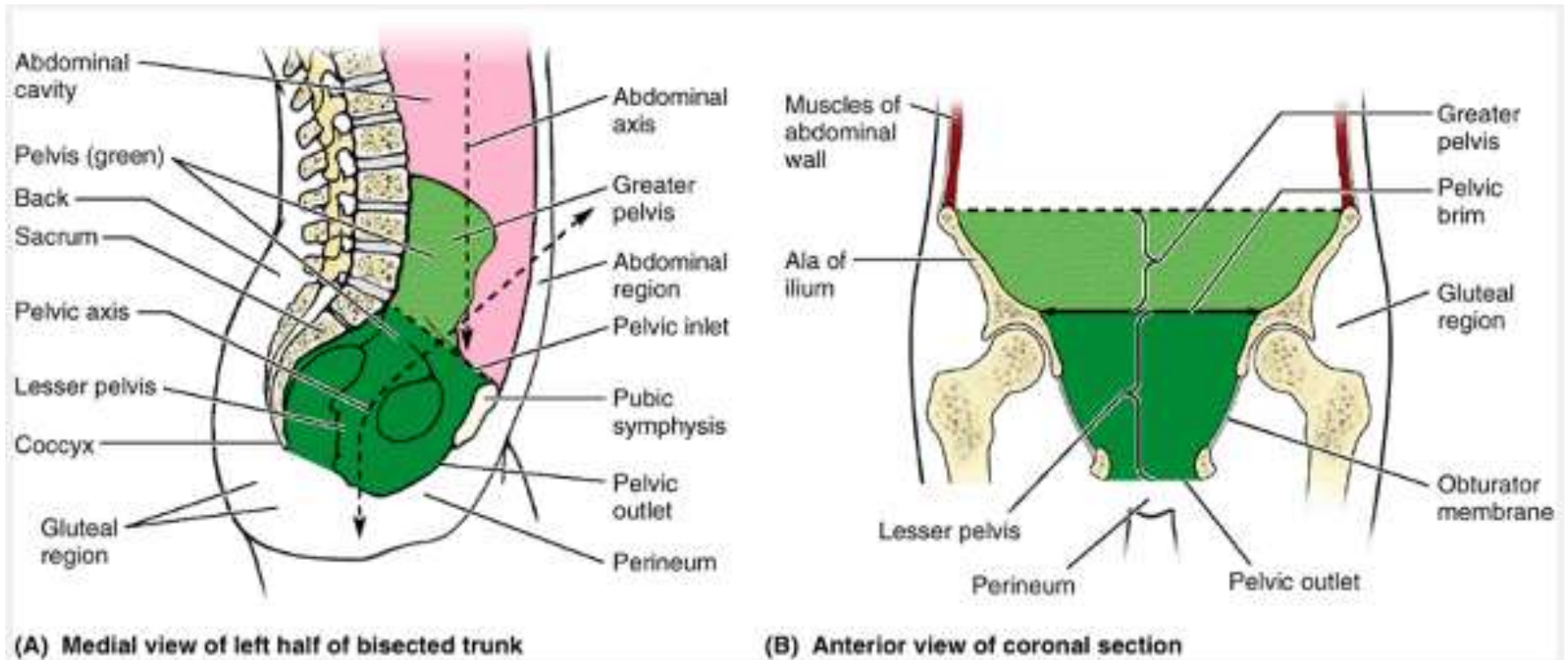


**True pelvis  
(minor)**

**Bounded by:**  
lumbar vertebrae posteriorly,  
iliac fossa laterally on both sides  
abdominal wall anteriorly

**Bounded by:**  
Sacrum and coccyx posteriorly  
Ischium and pubis on both sides laterally  
Pubis anteriorly  
Pelvic inlet superiorly  
Pelvic floor inferiorly

# The bones of the pelvis





## **The greater (false) pelvis**

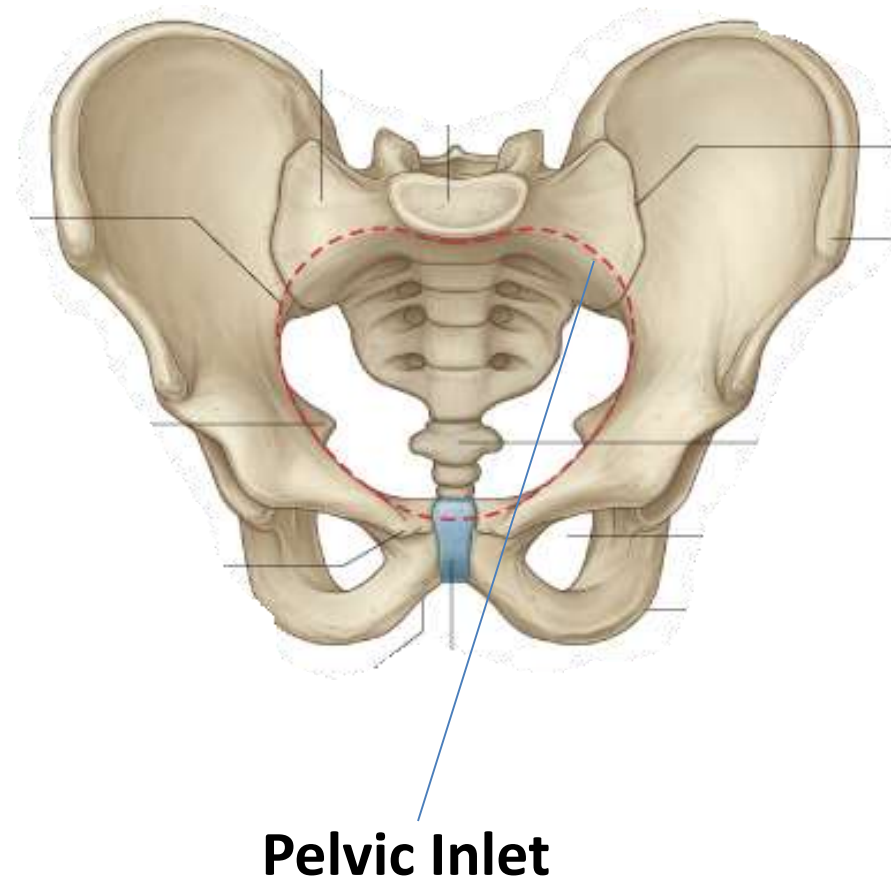
- Superior to the pelvic inlet.
- Bounded by the iliac alae posterolaterally and the anterosuperior aspect of the S1 vertebra posteriorly.
- Occupied by abdominal viscera (the ileum and sigmoid colon).

## **The lesser (true) pelvis**

- Between the pelvic inlet and the pelvic outlet.
- Bounded by the pelvic surfaces of the hip bones, sacrum, and coccyx.
- Of major obstetrical and gynecological significance.

# The pelvic inlet

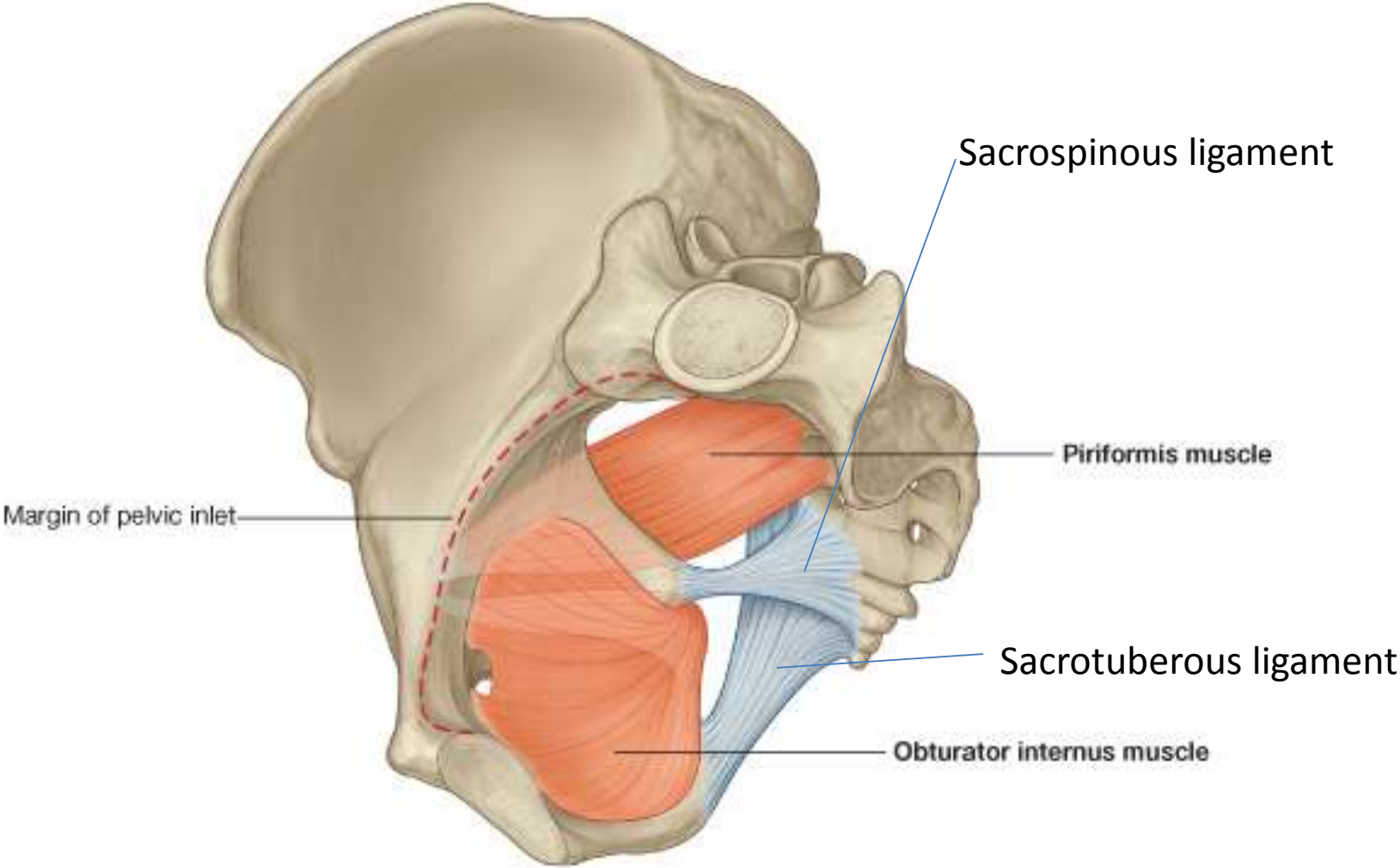
- Separates the false pelvis above from the true pelvis below
- Bounded:
  - Anteriorly: Superior aspect of the pubic bone
  - Laterally on both sides: Arcuate lines
  - Posteriorly : sacral promontory



# The pelvic wall

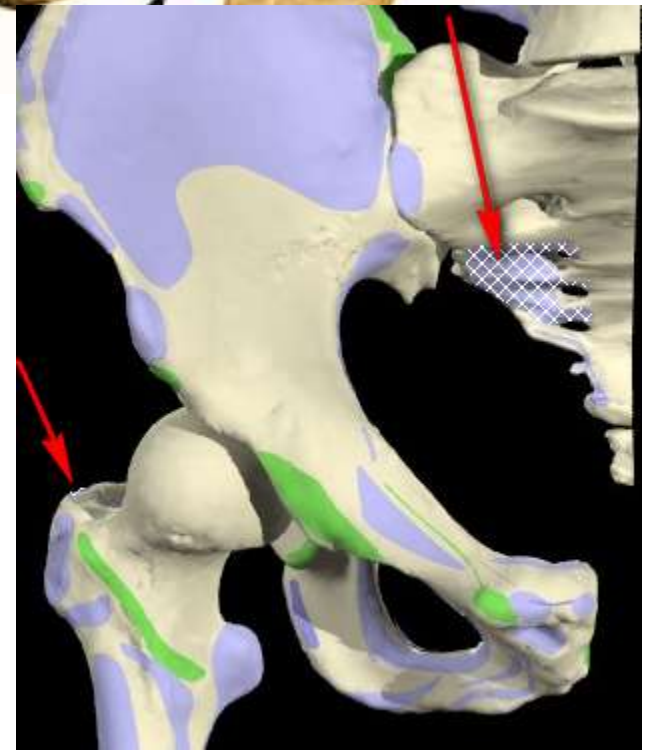
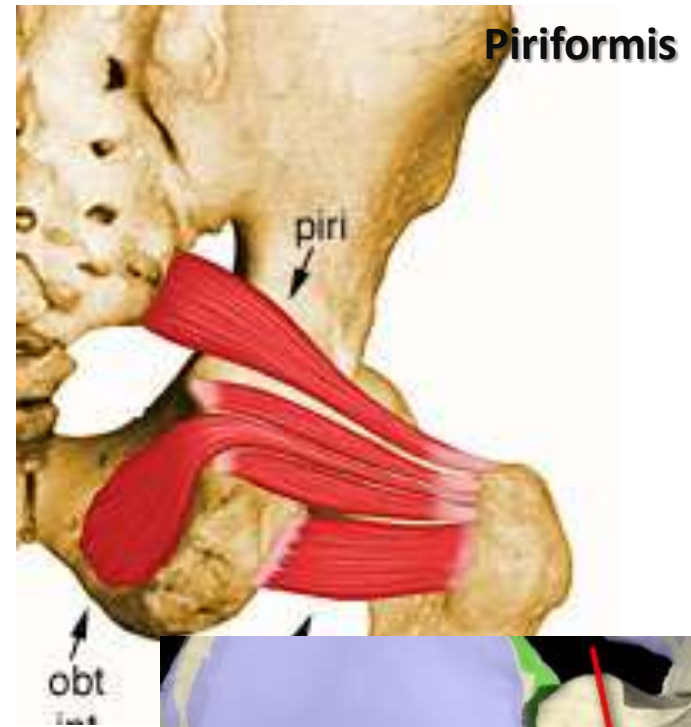
- Consists of bones and muscles and ligaments
- Bones:
  - Sacrum and coccyx posteriorly
  - Pelvic bone (os coxae) laterally and anteriorly
- Ligaments
  - Sacrospinous
  - Sacrotuberous
- Muscles
  - Piriformis
  - Obturator internus muscle

# The pelvic wall



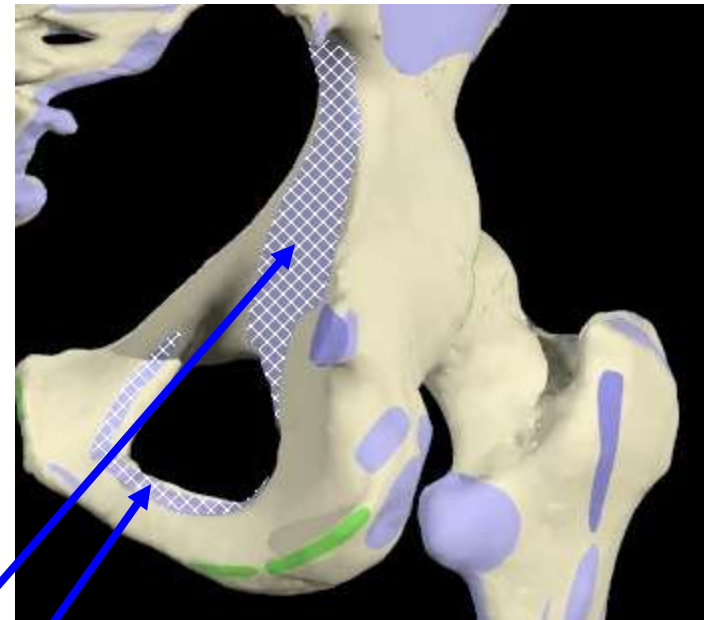
# Piriformis

- **O**: Pelvic surface of 2<sup>nd</sup> to 4<sup>th</sup> sacral segment lateral to the pelvic sacral foramina
- **I**: Medial side of greater trochanter of femur
- **A**: Laterally rotates the extended femur at hip joint; abducts flexed femur at hip joint
- **N**: Nerve to obturator internus (L5, S1)

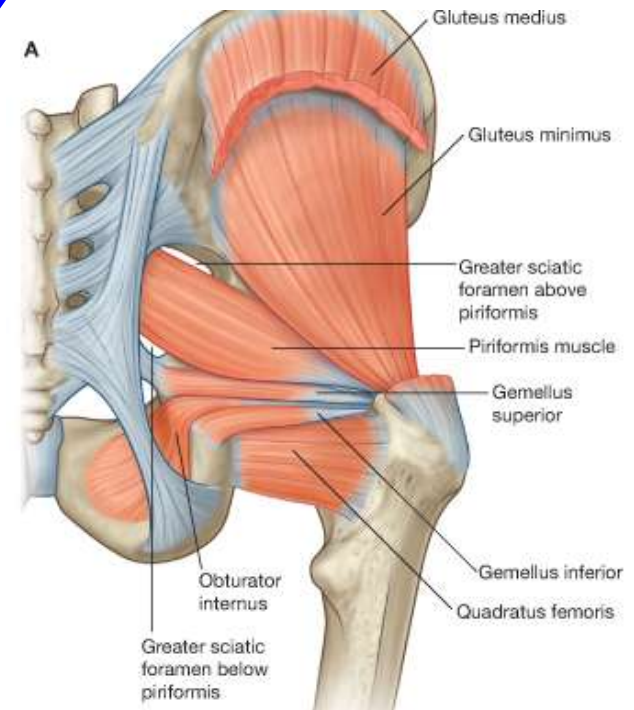


# Obturator internus

- **O**: Inner surface of the obturator membrane and the bone surrounding the obturator foramen
- **I**: Medial side of greater trochanter above the trochanteric fossa
- **A**: Laterally rotates the extended femur at hip joint; abducts flexed femur at hip joint
- **N**: Nerve to the obturator internus (S1,S2)

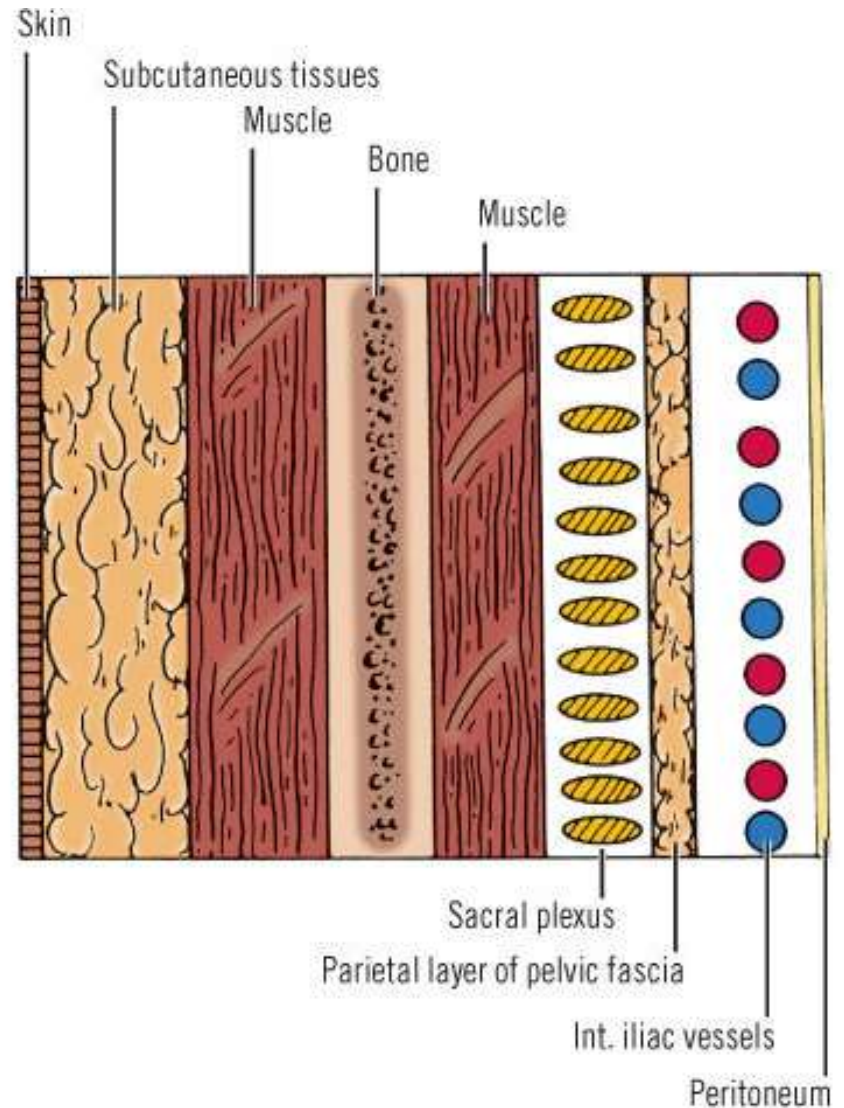
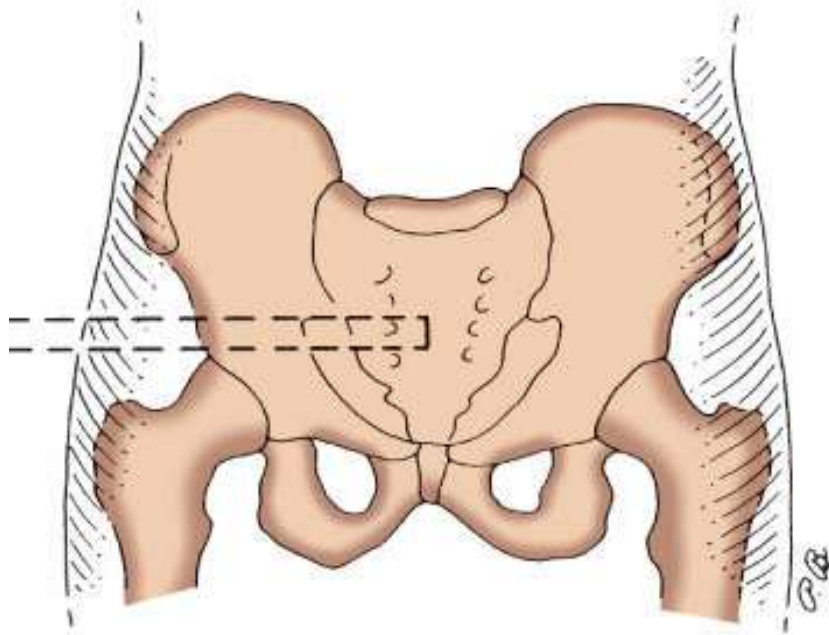


**Obturator Internus**





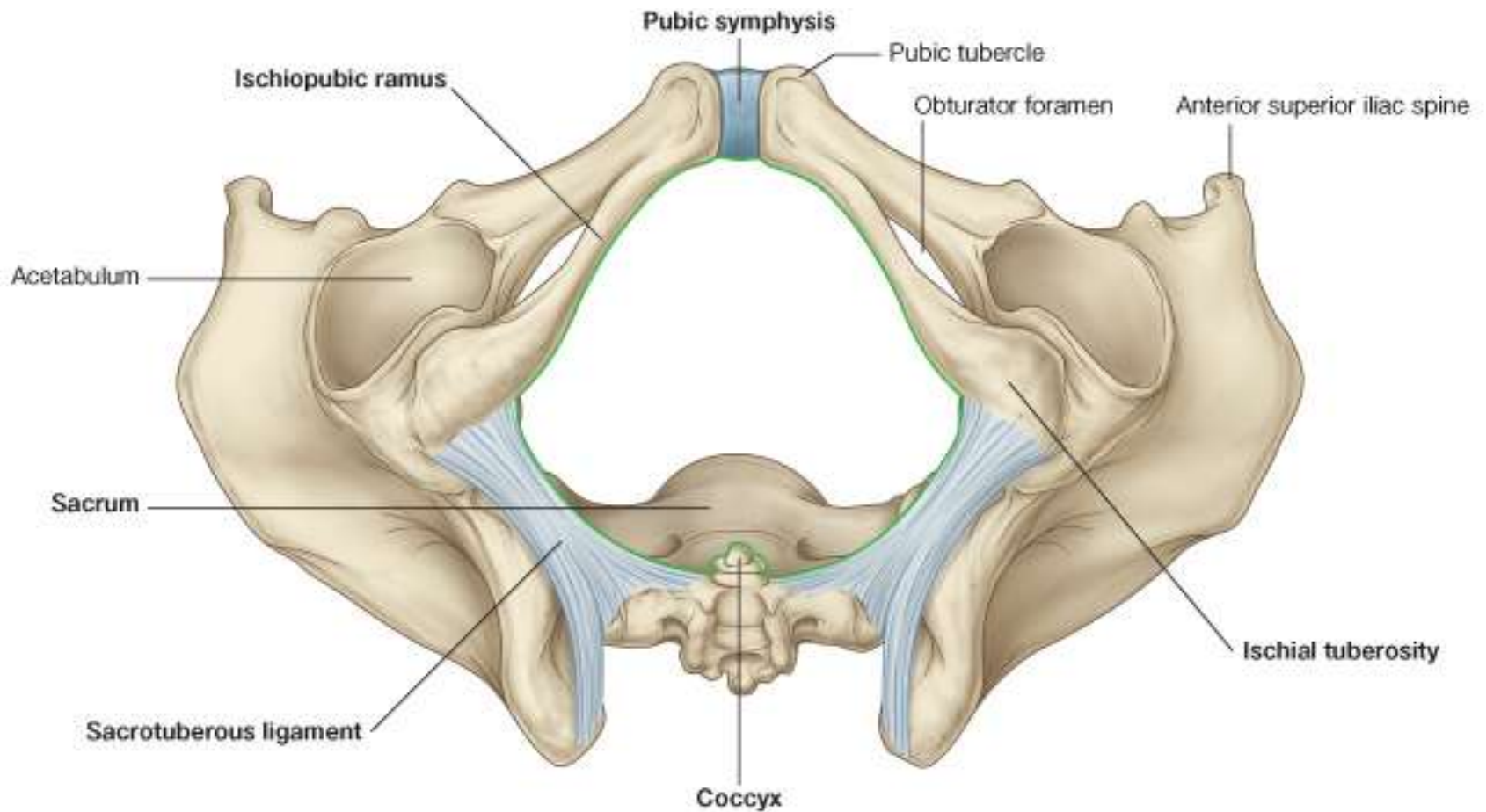
# The layers of the pelvic wall



# The pelvic outlet

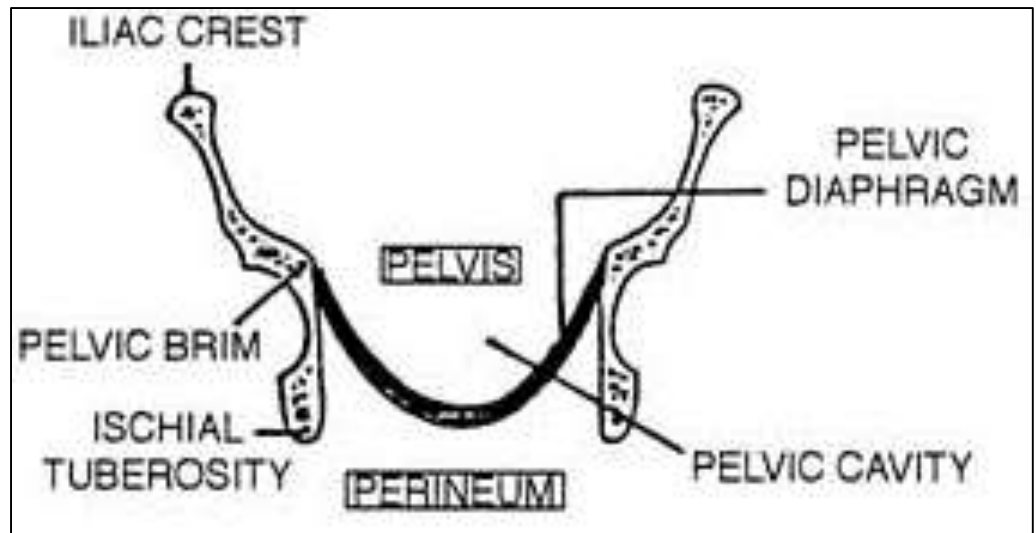
- Diamond shaped
- Bounded:
  - Anterior half by:
    - The pubic arch
      - i. Pubic symphysis
      - ii. Ischiopubic rami
    - Ischial tuberosity
  - Posterior half by:
    - sacrotuberous ligaments on either sides
    - Coccyx posteriorly

# The Pelvic outlet



# The pelvic floor

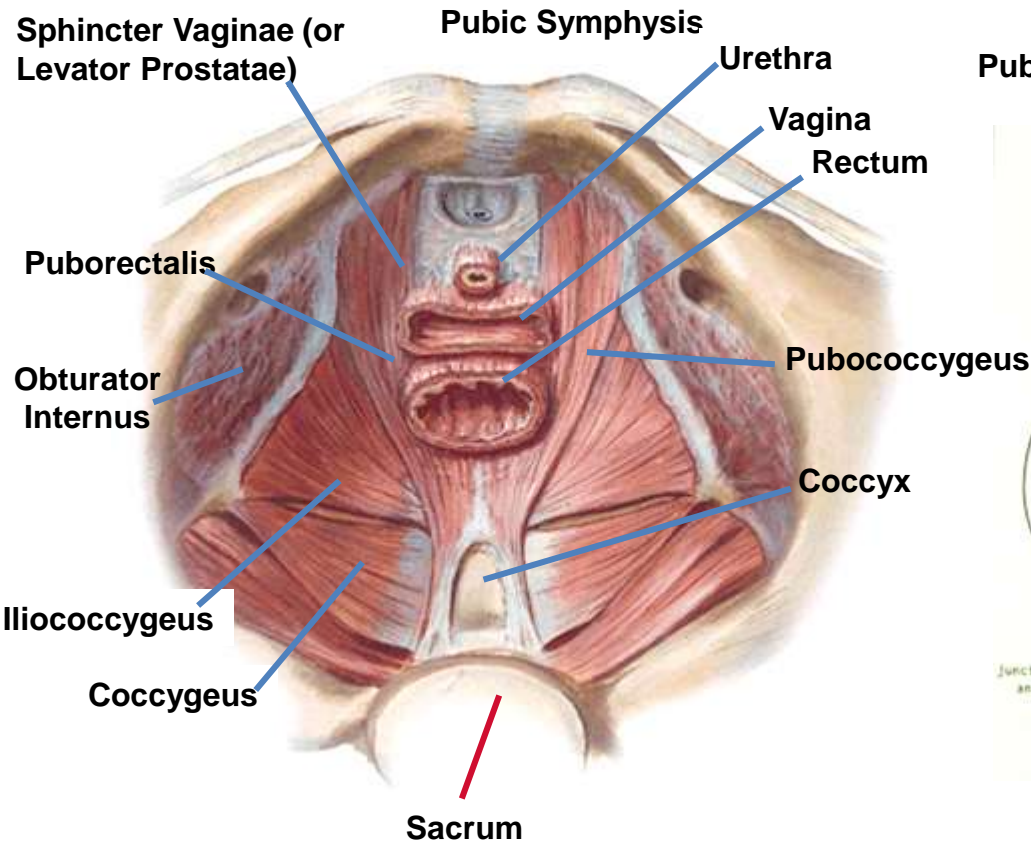
- Separates the pelvis from the perineum
- Formed by the bowl shaped pelvis diaphragm



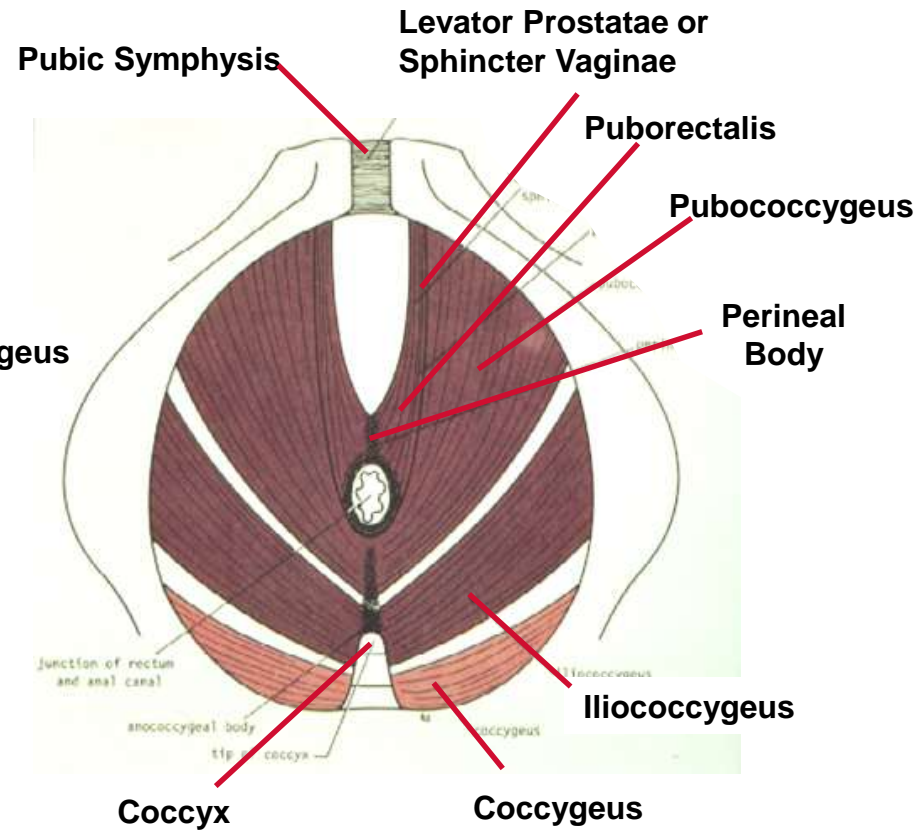
# Pelvic diaphragm

- Consists of the
  - i. Coccygeus
  - ii. Levator ani muscles
  - iii. The fascias covering the superior and inferior aspects of these muscles

# Pelvic diaphragm



Superior View



Inferior View



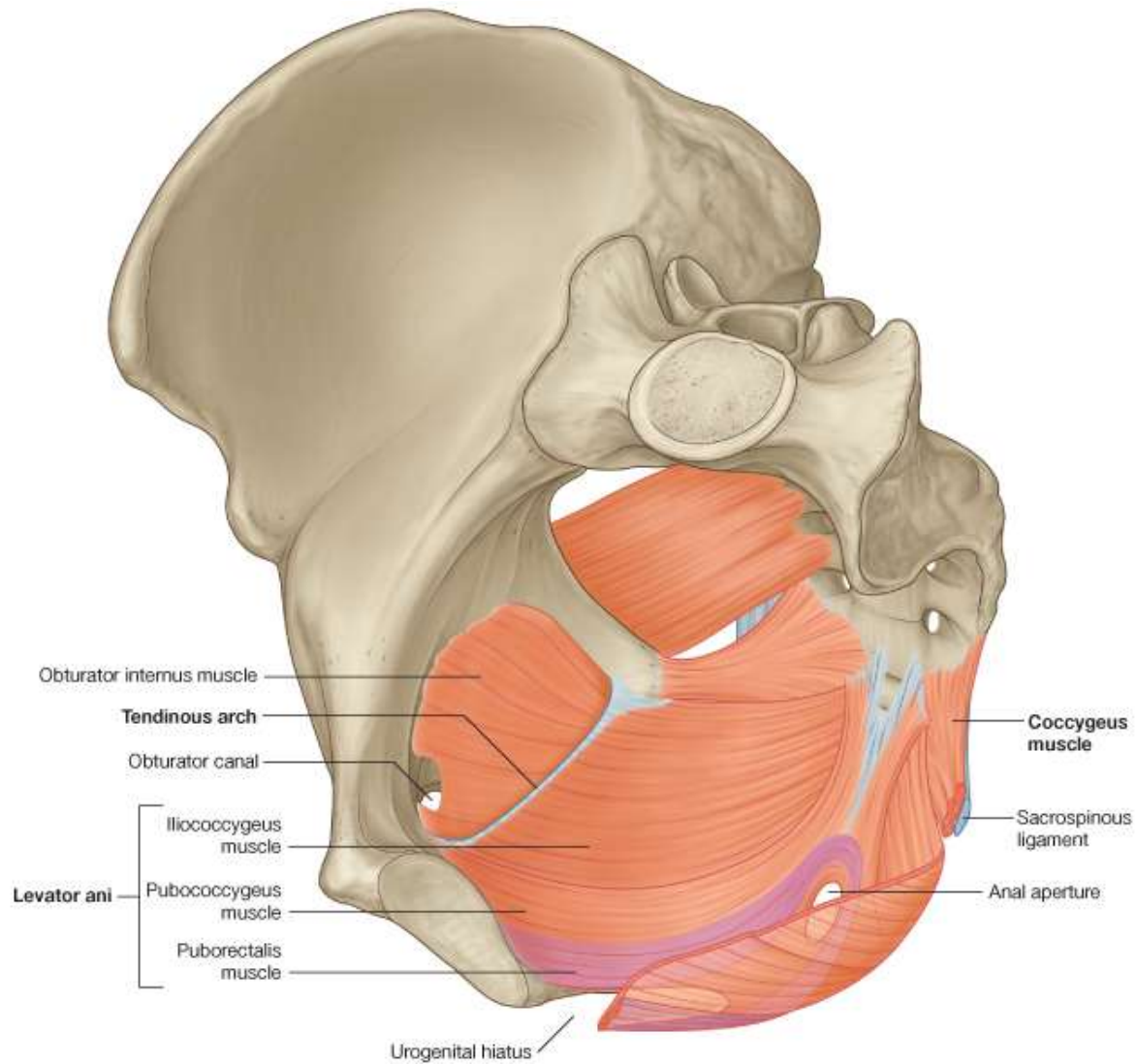
# Levator ani

- Originates from the pelvis sidewall thus:
  - The posterior aspect of the body of the pubic bone
  - Tendinous arch of the obturator internus muscle fascia covering
  - Ischial spine.
- Both descend medially and inferiorly to join together in the midline (Raphe)

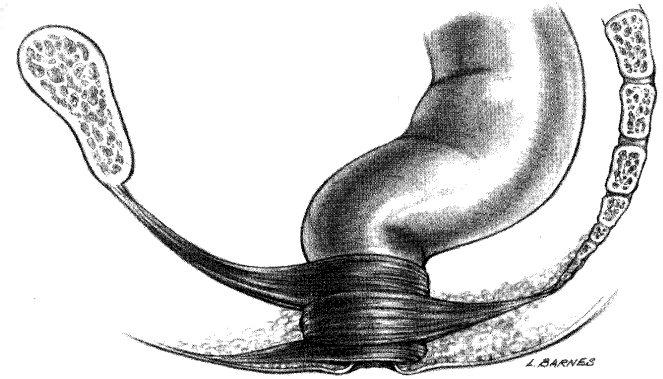
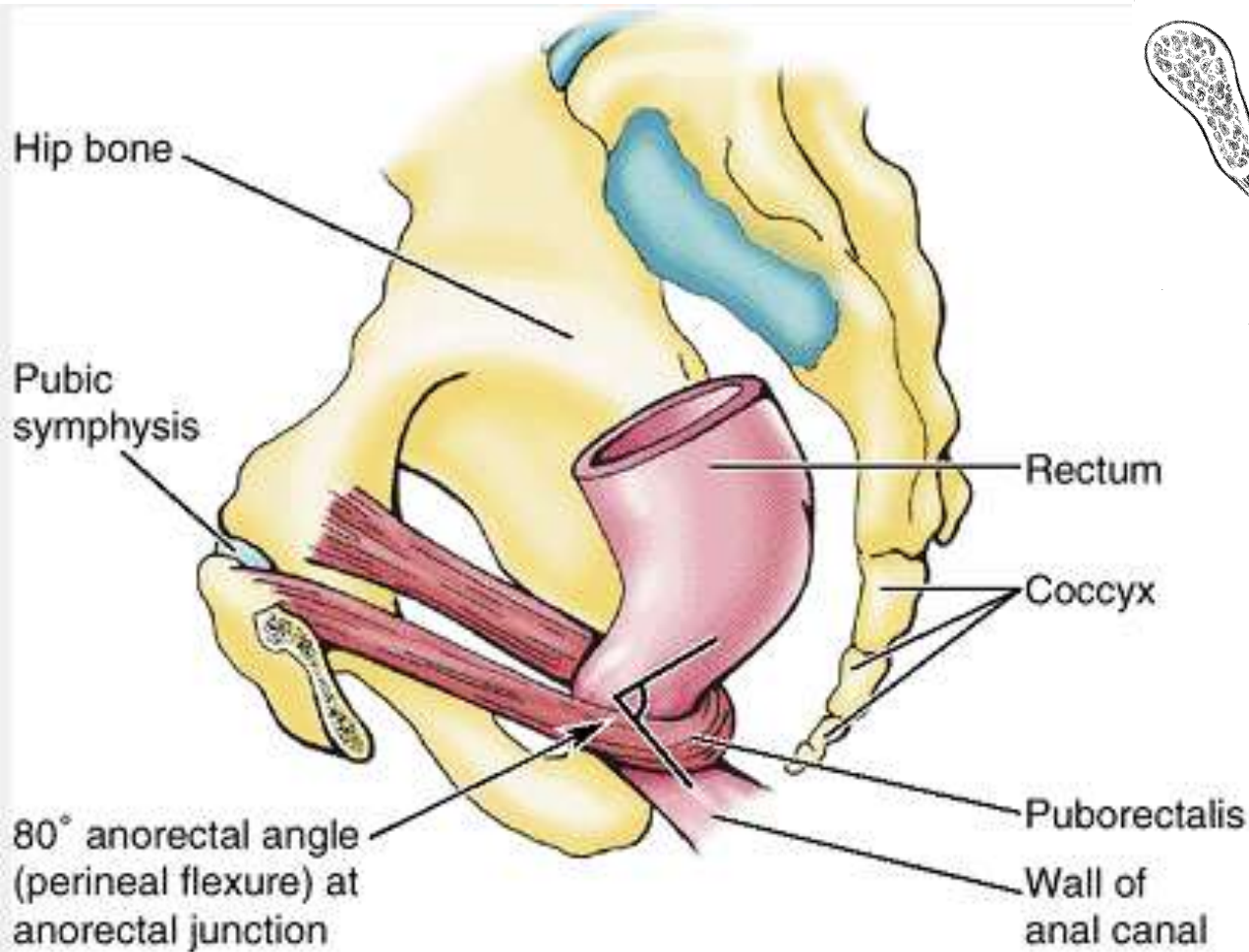
# Parts of the levator ani

- On the basis of origin and attachment , the muscle has three divisions
  - i. The **pubococcygeus** originates from the body of the pubis and courses posteriorly to attach along the midline as far back as the coccyx.
  - ii. **Puborectalis** originates from the pubis and passes inferiorly on each side to form a sling around the rectum. This forms the **perineal flexure**, at the anorectal junction. This angle functions as part of the mechanism that keeps the end of the gastrointestinal system closed.
  - iii. **Iliococcygeus** which originates from the fascia that covers the obturator internus muscle. It joins the same muscle on the other side in the midline to form a ligament or raphe that extends from the anal aperture to the coccyx.

# Levator ani



# Puborectalis

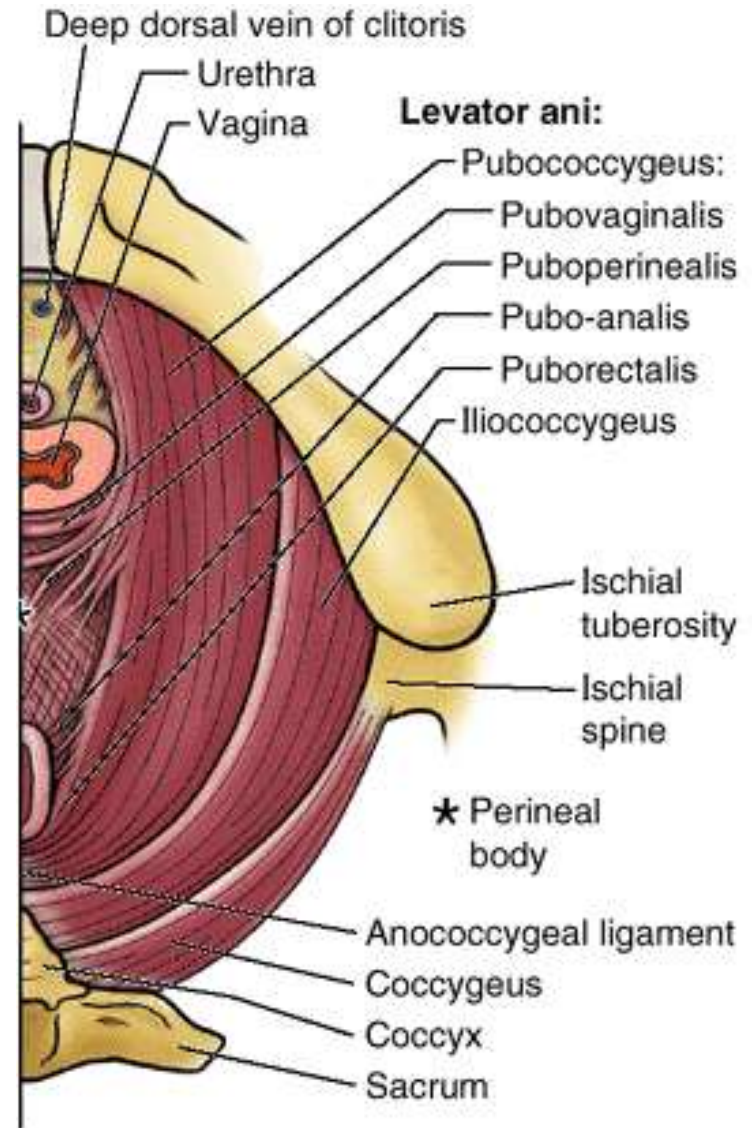


# Function of the levator ani

- Forms a dynamic floor for supporting the abdominopelvic viscera.
- It is tonically contracted most of the time to support the abdominopelvic viscera and to assist in maintaining urinary and fecal continence.
- Actively contracts during activities that increases abdominal pressure e.g. coughing, sneezing, and lifting of loads, so as to support the viscera
- Contributes to anal continence through the puborectalis
- Must relax to allow defecation and micturition
- They are innervated directly by branches from the anterior ramus of S4 and by branches of the pudendal nerve (S2 to S4).

# Coccygeus

- Two muscles: one on each side
- Triangular in shape
- Overlies the sacrospinous ligaments
- Together they complete the posterior part of the pelvic diaphragm
- Attached by their apices to the tips of the ischial spines and, by their bases, to the lateral margins of the coccyx and adjacent margins of the sacrum.
- Innervated by branches from the anterior rami of S4 and S5 and participate in supporting the posterior aspect of the pelvic floor.





# Pelvic diaphragm: Insertion

- Both muscles of the diaphragm meet in the midline
- Form apertures through which structures pass from pelvis to the perineum
  - Anal aperture for the anus posteriorly
  - Urogenital hiatus for urethra and vagina anteriorly
  - Posterior to the anus, the muscles come together as the anococcygeal ligament (anococcygeal body) which attaches to the coccyx

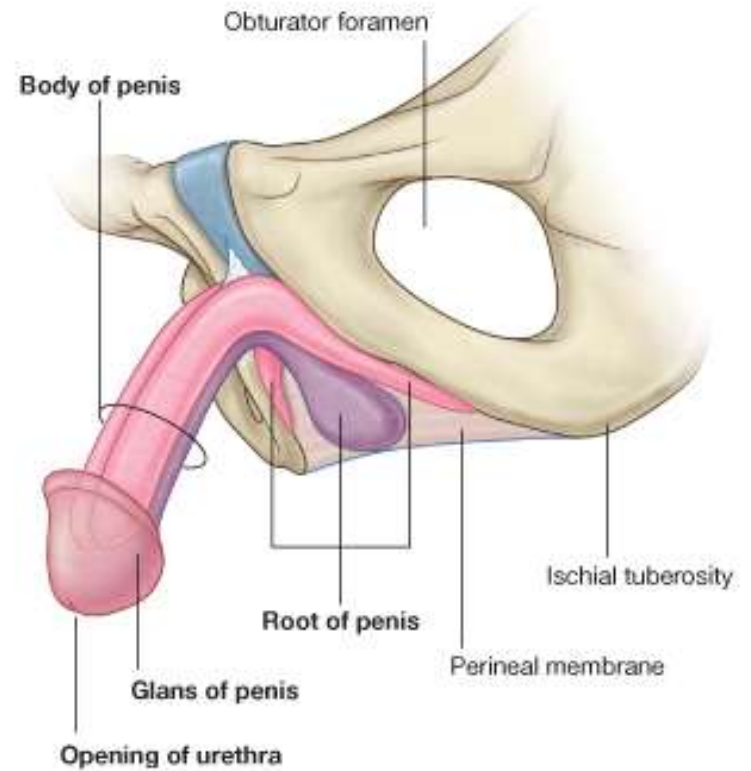
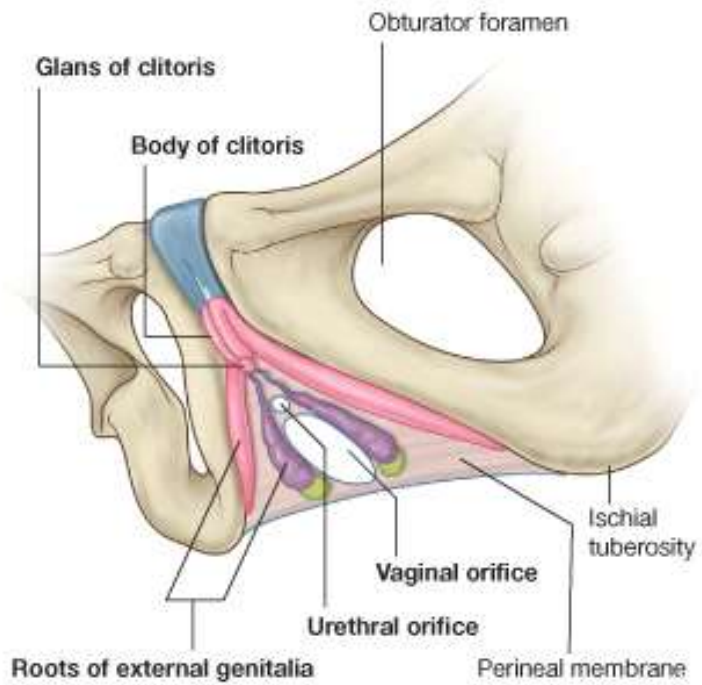
# Pelvic cavity

- Lined by peritoneum which is continuous with the peritoneum of the abdominal cavity.
- The pelvic viscera are located in the midline of the pelvic cavity
- The bladder anteriorly
- Rectum posteriorly
- In females the uterus lies between the rectum and the bladder.
- Vessels and nerves lie deep to the peritoneum on either the pelvic walls or the viscera

# Perineum

- Lies below the pelvic floor
- Refers to the surface of the trunk between the thighs and the buttocks, extending from the coccyx to the pubis
- Divided into two by an imaginary line between the ischial tuberosities into:
  - i. **Urogenital triangle** contains the roots of the external genitalia and, in women, the openings of the urethra and the vagina. In men, the distal part of the urethra is enclosed by erectile tissues and opens at the end of the penis
  - ii. The **anal triangle** contains the anal aperture posteriorly.

# Perineum



# The pelvic peritoneum

- Is a continuation of the peritoneum lining the abdominal wall.
- Descends into the pelvis but does not reach the pelvic floor due to the presence of the pelvic viscera
- Only the ovaries and the uterine tubes are completely enclosed by the peritoneum
- The remaining viscera are covered by peritoneum only on their superior surfaces

# The pelvic peritoneum

- Superior to the bladder, the peritoneum is loosely bounded to the anterior abdominal wall
- This allows it to easily lift off the underlying fascia
- Creating a space, the supravescica fossa, which the bladder fills while it is filling up with urine
- Covers convex superior surface (roof) of bladder and slopes down sides of roof to ascend lateral wall of pelvis creating paravesical fossae on each side



# Pelvic peritoneum

## Male

- Descends posterior surface of bladder as much as 2 cm
- Laterally, forms fold over ureters (ureteric fold), ductus deferens, and superior ends of seminal glands

## Female

- Reflects from bladder roof onto body of uterus forming vesicouterine pouch
- Covers body and fundus of uterus and posterior fornix of vagina; extends laterally from uterus as double fold or mesentery (broad ligament) that engulfs uterine tubes, ovaries, and round ligaments of uterus

# Pelvic peritoneum

## Male

- Reflects from bladder and seminal glands onto rectum, forming rectovesical pouch
- Rectovesical pouch extends laterally and posteriorly to form pararectal fossae on each side of rectum

## Female

- Reflects from vagina onto rectum, forming rectouterine pouch
- Rectouterine pouch extends laterally and posteriorly to form pararectal fossae on each side of rectum

# Pelvic peritoneum

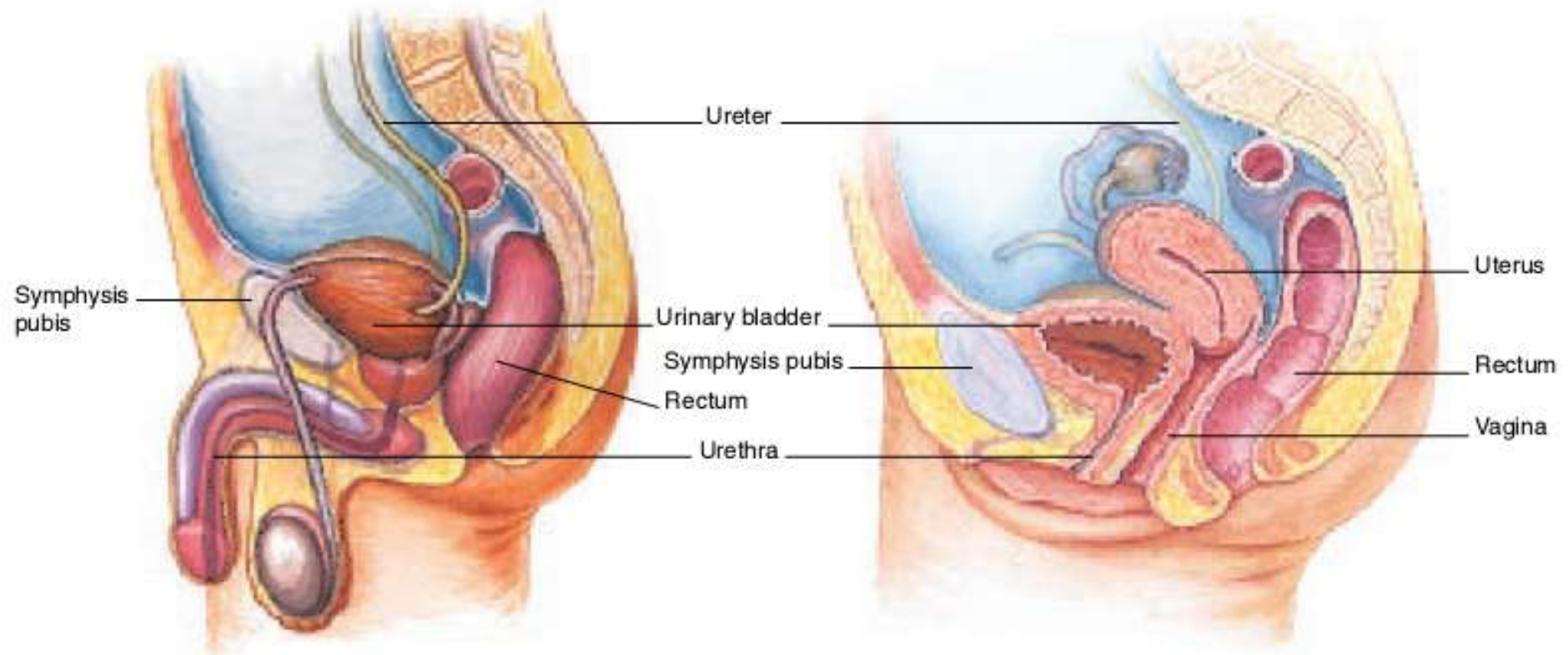
## Male

- Ascends rectum; from inferior to superior, rectum is subperitoneal and then retroperitoneal
- Engulfs sigmoid colon beginning at rectosigmoid junction

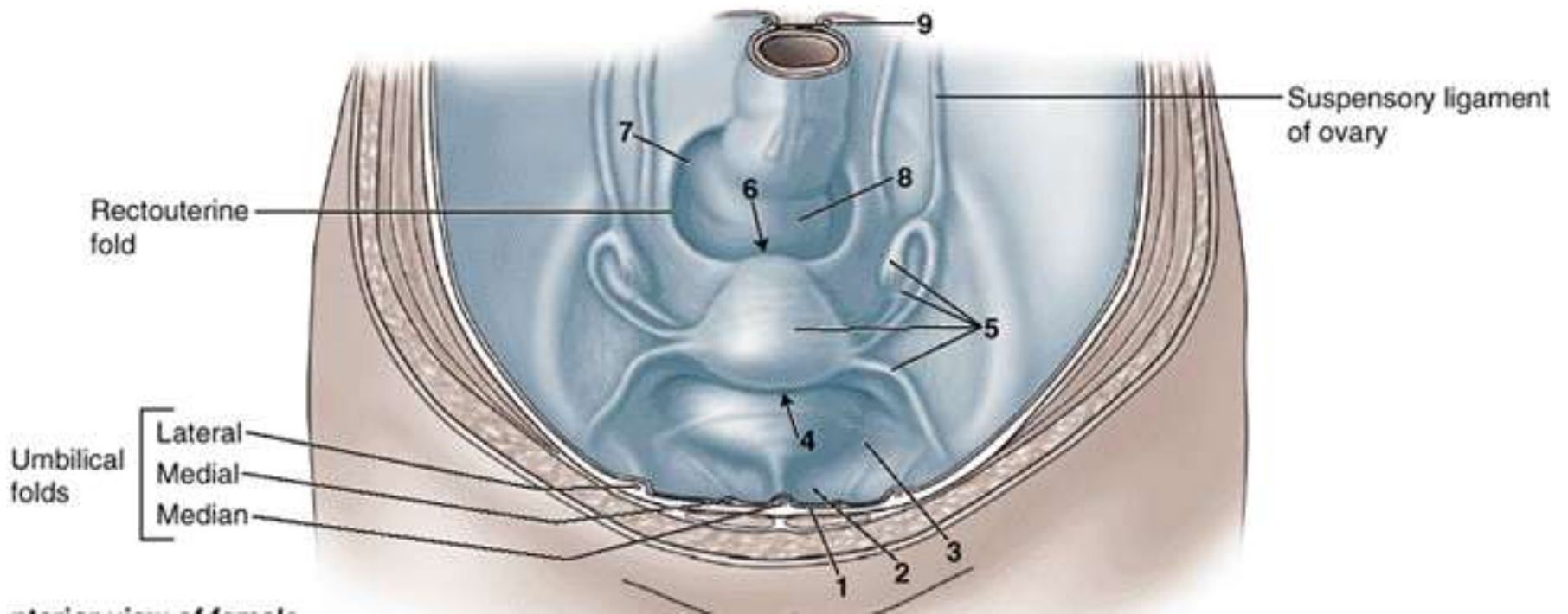
## Female

- Ascends rectum; from inferior to superior, rectum is subperitoneal and then retroperitoneal
- Engulfs sigmoid colon beginning at rectosigmoid junction

# Pelvic peritoneum



# Pelvic peritoneum



# Thank you.

- **Question?**

