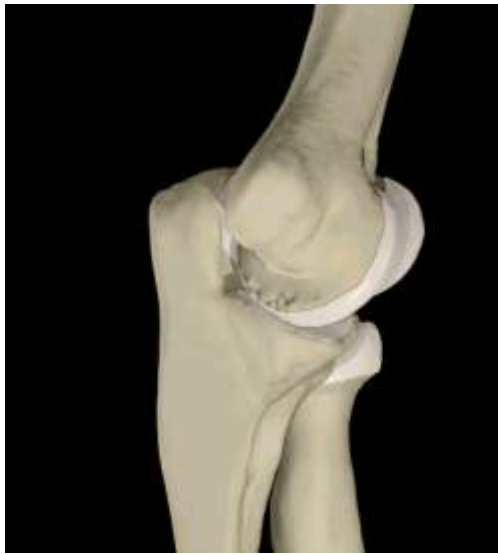



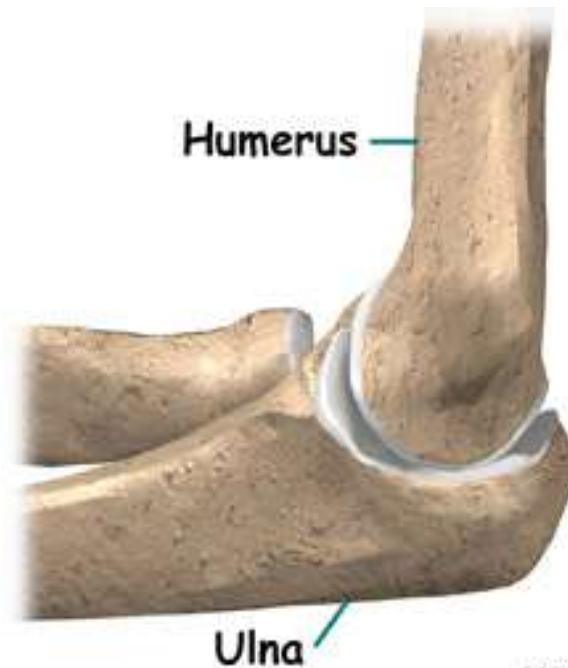
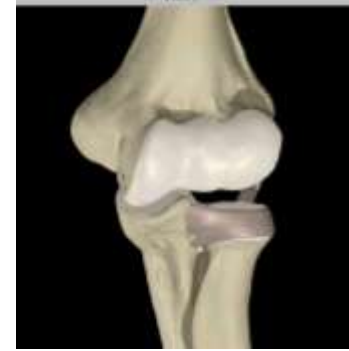The Elbow and the cubital fossa

Prof Oluwadiya Kehinde

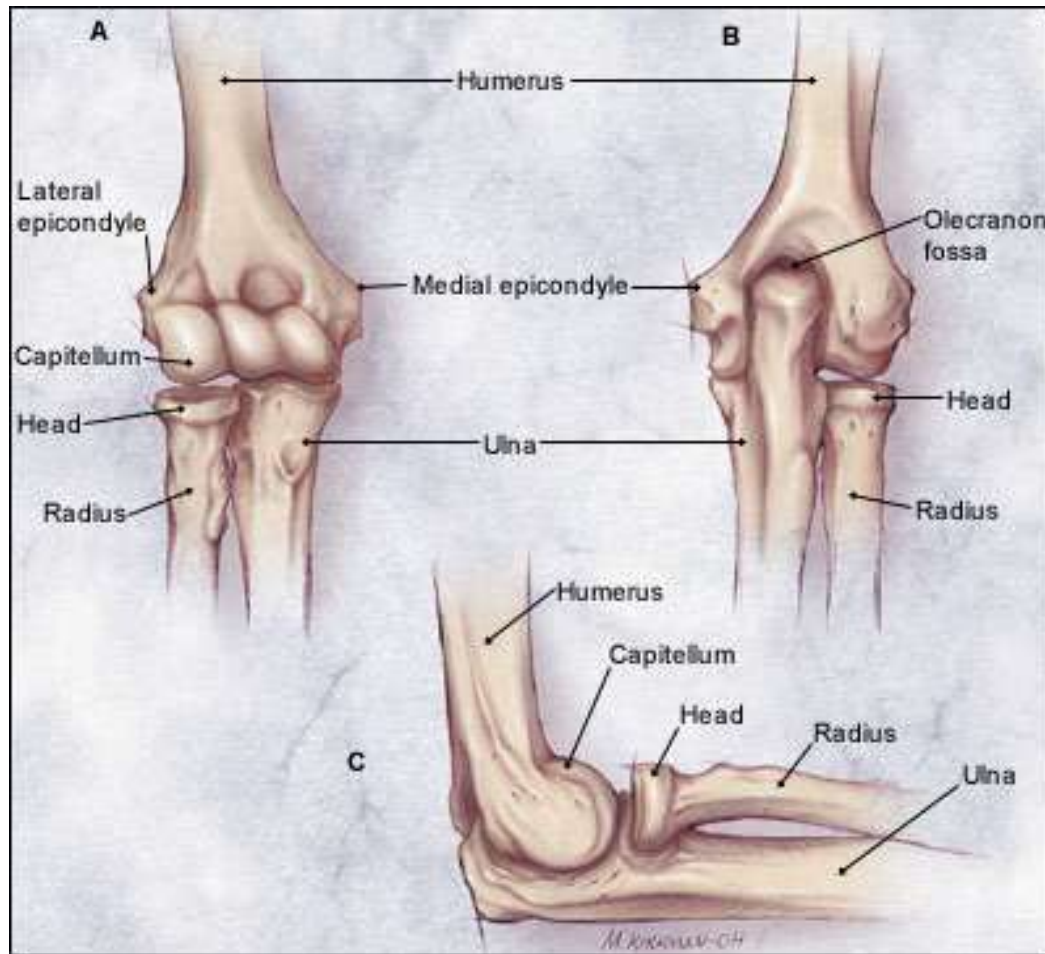
www.oluwadiya.com

Elbow and Forearm Anatomy

- The elbow joint is formed by the humerus, radius, and the ulna



Bony anatomy of the elbow



Distal Humerus

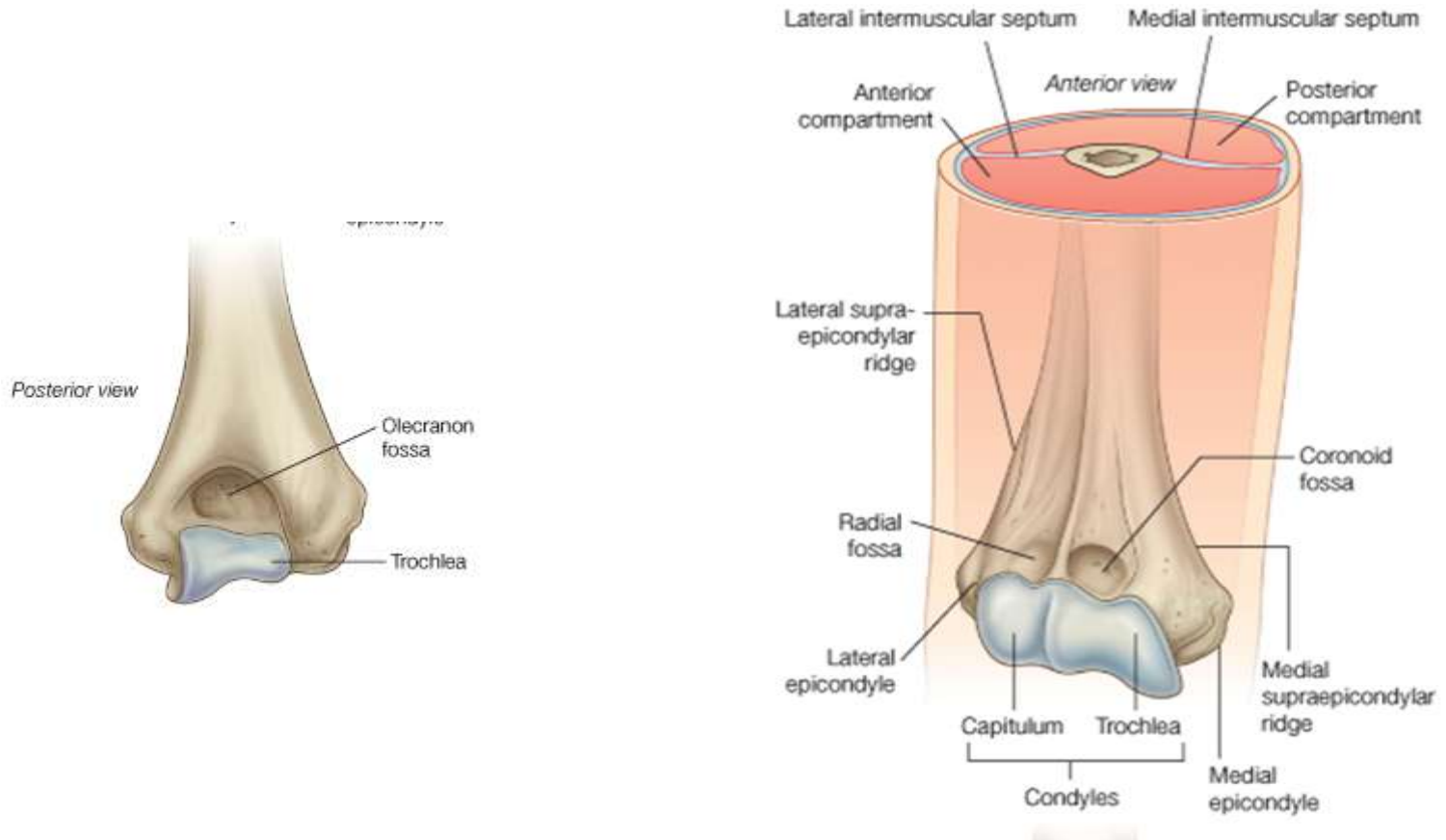
➤ Medial side

- Distal anteromedial border: trochlea
- Conoid fossa: Immediately above trochlear anteriorly to accept ulna coronoid process during flexion
- Olecranial fossae: corresponding place posteriorly to accept the olecranium during extension
- Medial Epicondyle
 - Epicondyle serves as axis of rotation of ulna

➤ Lateral side

- Capitulum (means little head), articulates with the radial head
- Lateral Epicondyle
- Radial Fossa
 - Immediately above capitulum to accept radial head during elbow flexion

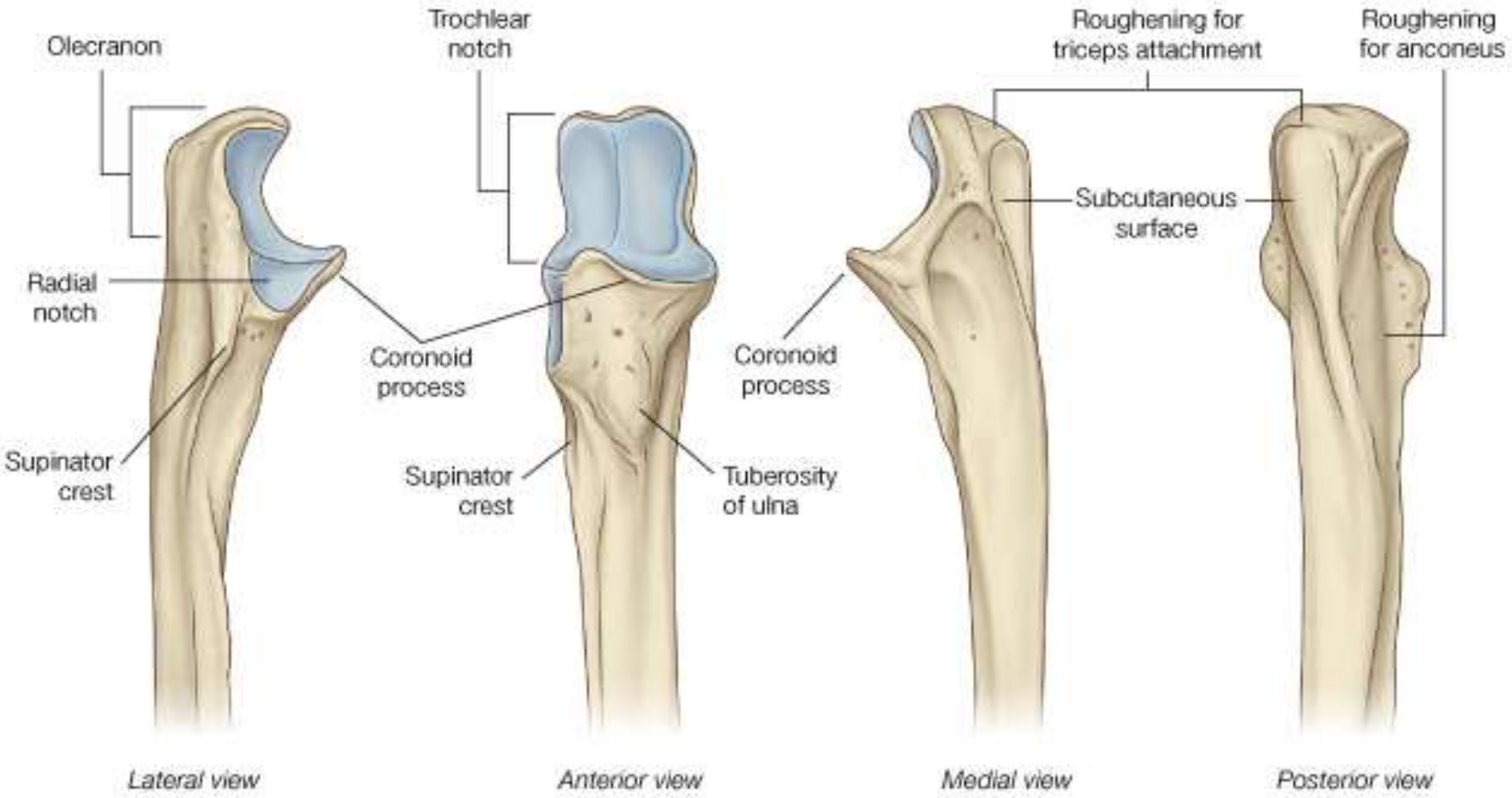
The Distal Humerus



Ulna

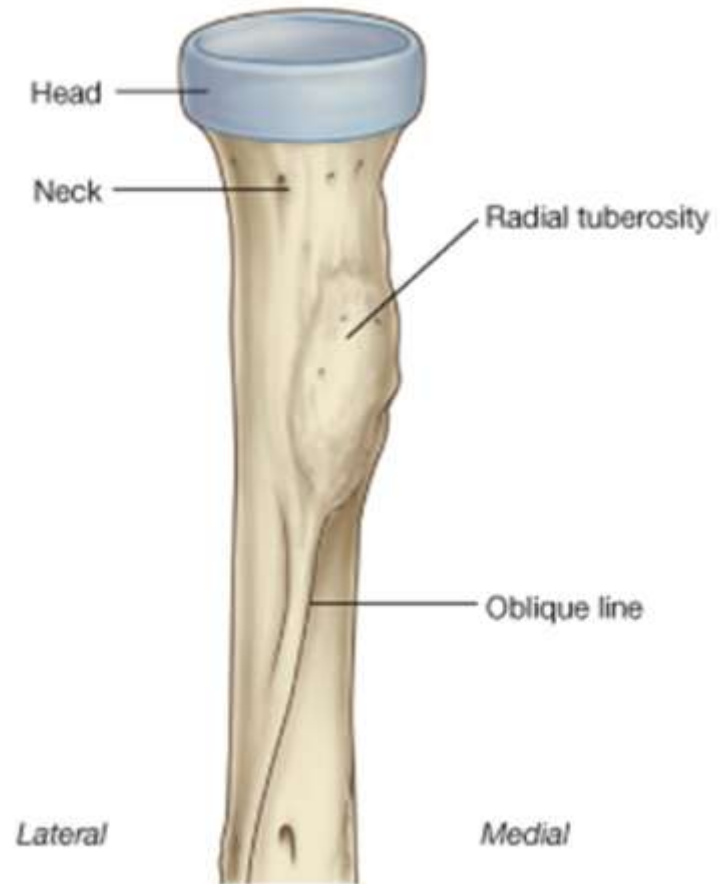
- Forms medial border of forearm
- Trochlear notch
 - Lined with articular cartilage and fits snugly around trochlea of the humerus
- Olecranon Process
 - Forms the proximal border of ulna
 - Fits into humeral olecranon fossa at full extension
- Coronoid process
 - Distal border of the trochlear fossa. Fits into coronoid fossa of the humerus during elbow flexion
- Radial notch
 - Indentation that accepts radial head to form proximal radioulnar joint

The Proximal Ulna



Radius

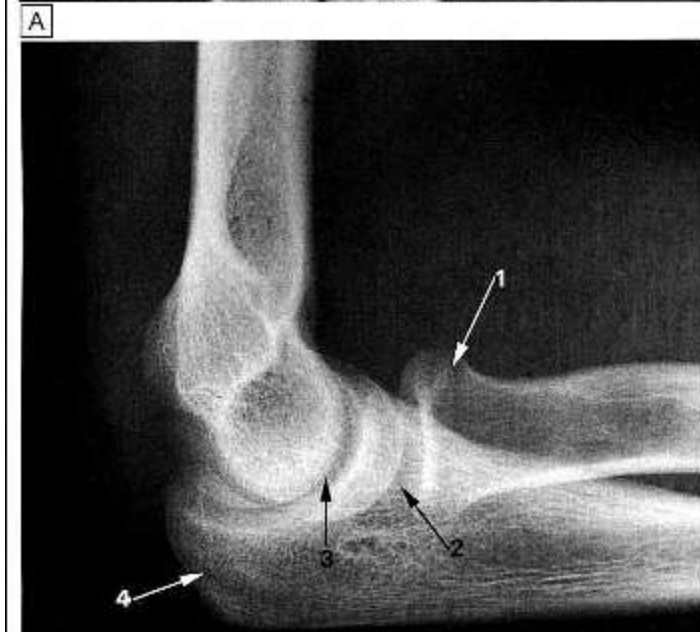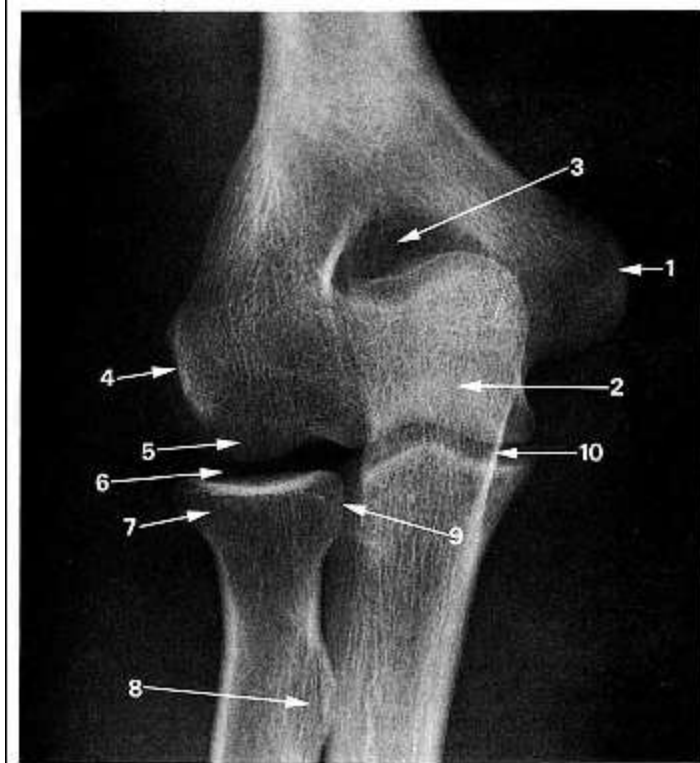
- Lateral aspect of elbow when in anatomical position
- Bicipital tuberosity (radial tuberosity)
 - Insertion site for bicep brachii



Joints of the Elbow

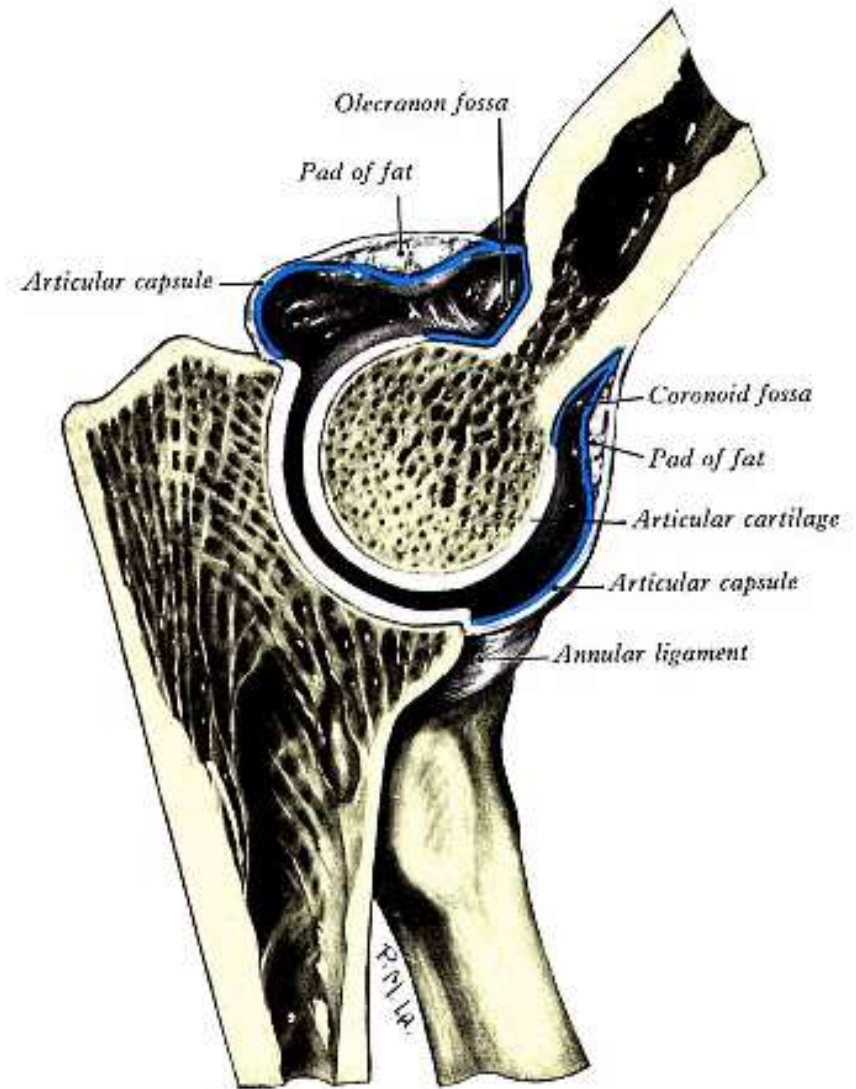
Hinge joint

- Composed of 3 articulations:
 1. Humeroulnar joint
 2. Humeroradial joint
 3. Radioulnar joint



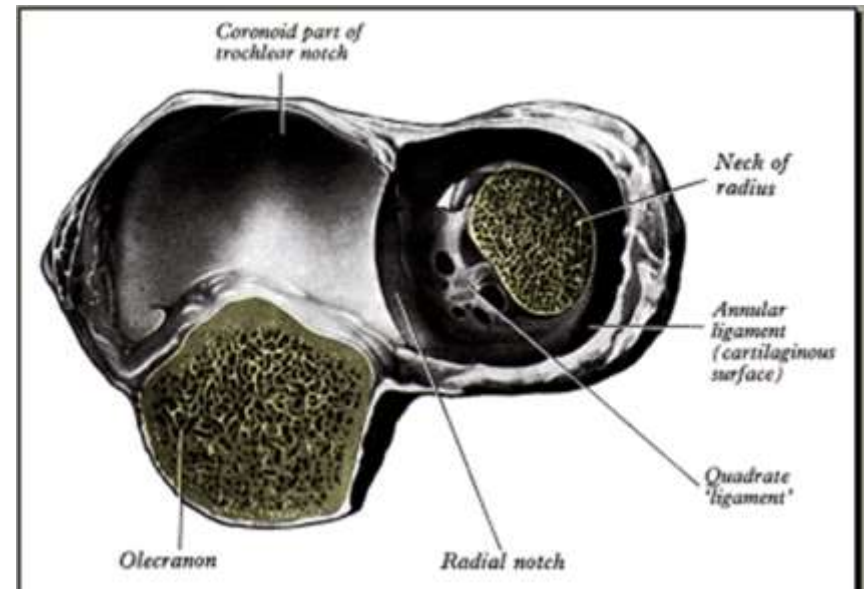
Humeroulnar

- Modified Hinge joint
- Allows for axis of motion:
 - Flexion
 - Extension



Proximal Radioulnar

- Formed by convex head of the radius and concave radial notch of the ulna
- Allows for axis of movement also:
 - Pronation
 - Supination



The Joint Capsule

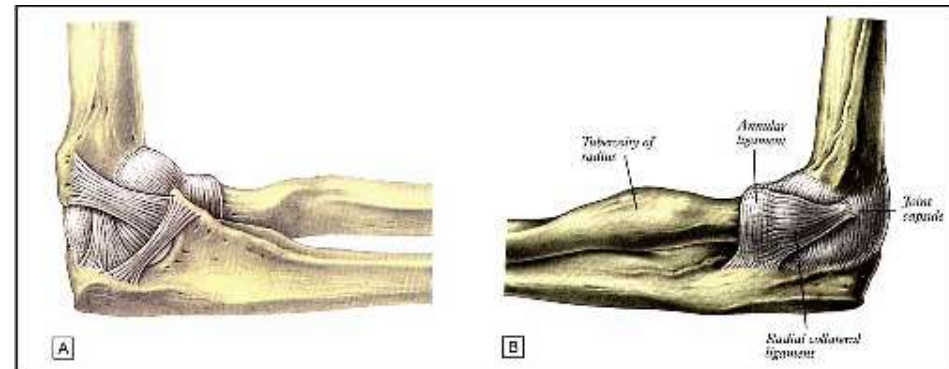
- Thin anteriorly and posteriorly

Proximal attachment

- Above coronoid and radial fossa anteriorly
- Above olecranal fossa posteriorly

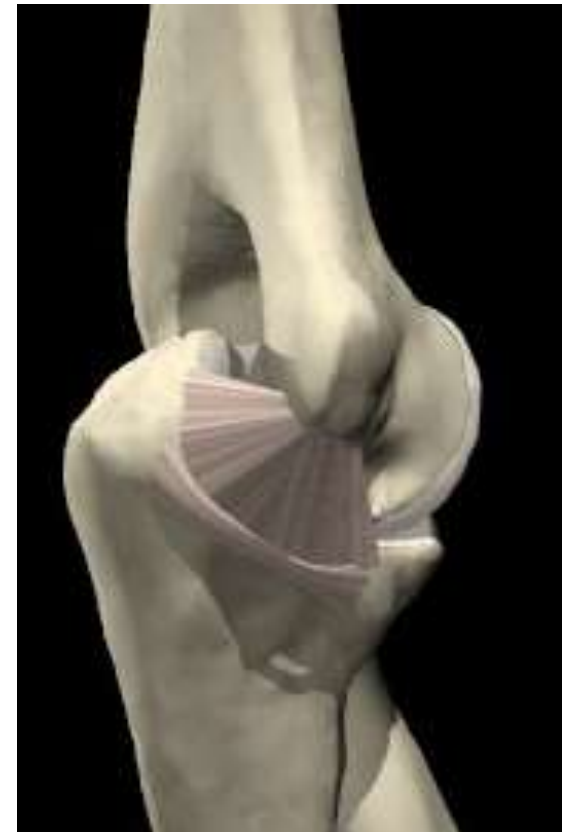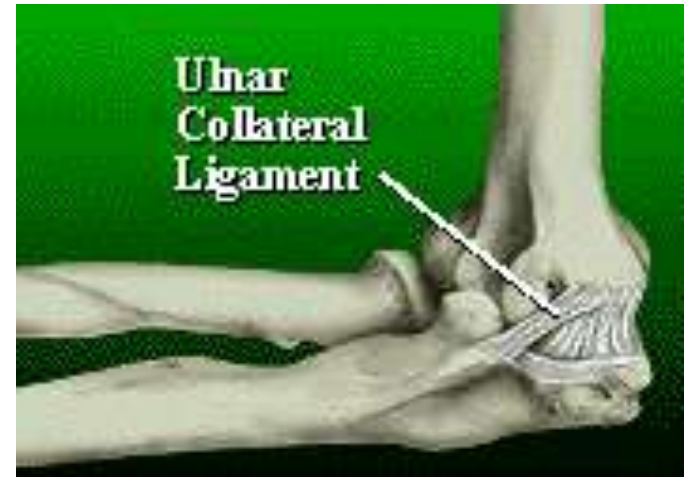Distal attachment

- Superior margin of olecranium process posteriorly
- Blends with annular ligament laterally
- Edge of the conoid process anteriorly



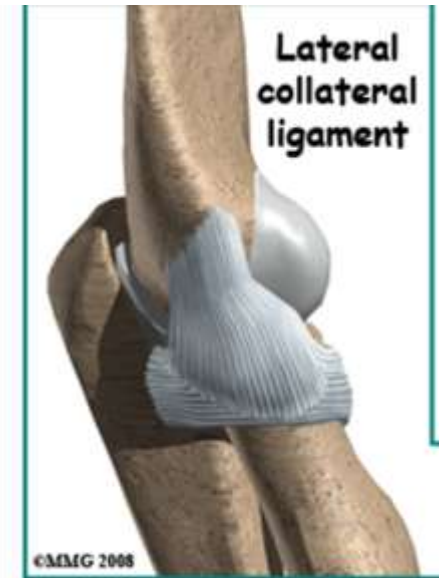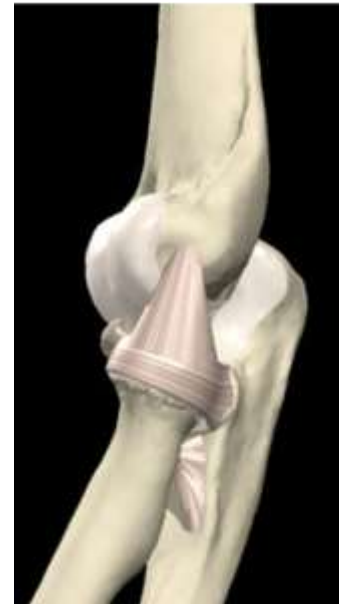Ulnar Collateral Ligament (UCL)

- Medial
- Supports against valgus force
- Composed of three components or bands:
 - i. Anterior band
 - ii. Posterior band
 - iii. Oblique band



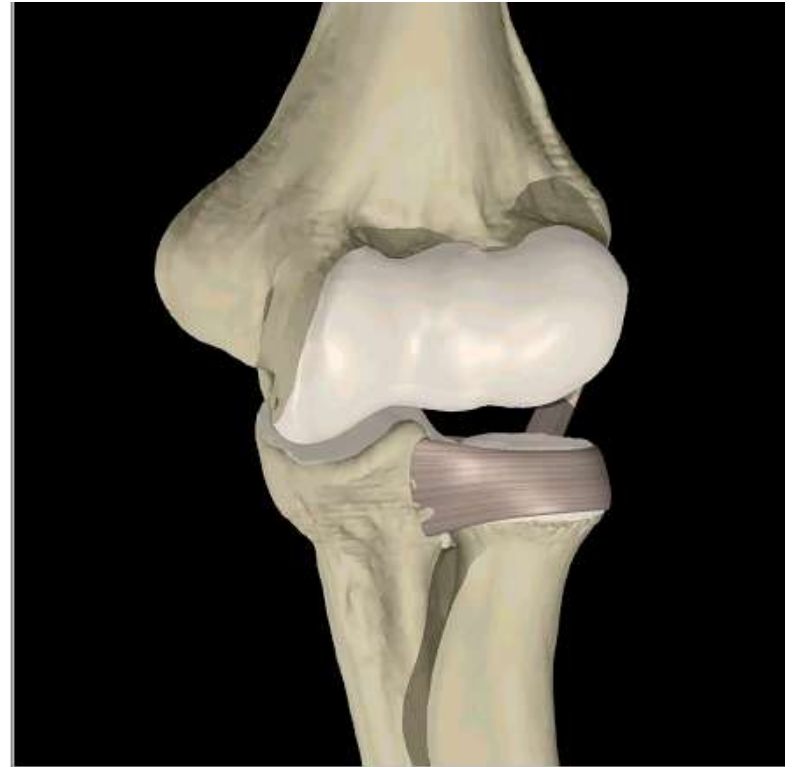Radial Collateral Ligament (RCL)

- Thickened area in lateral joint capsule between the lateral epicondyle and annular ligament
- Resists varus stress
- Helps to maintain the relationship between humeral and radial head



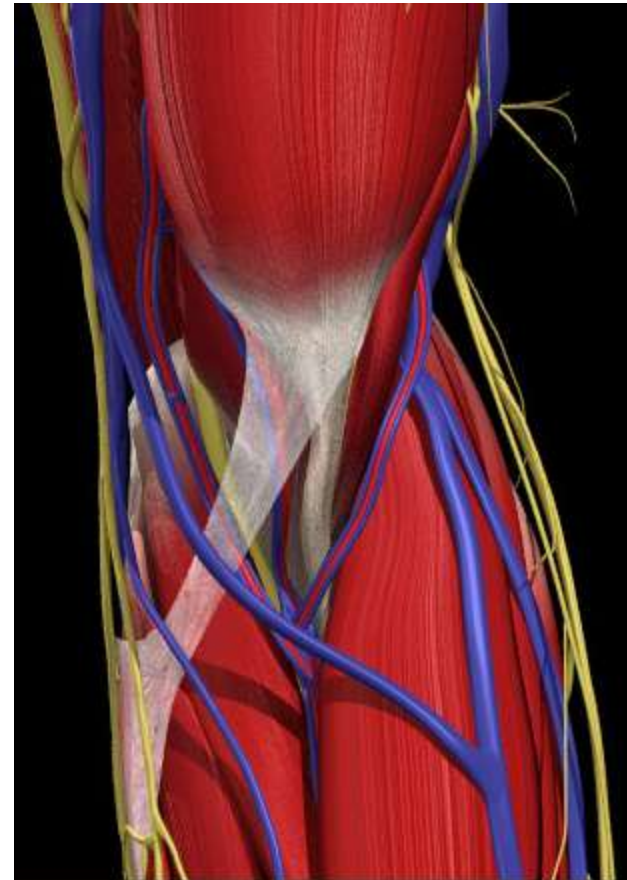
Annular Ligament

- Permits rotation of radial head within the radioulnar articulation
- Attaches to anterior & posterior rims of the radial notch of the ulna
- Serves as attachment to radial collateral ligament
- Proximally blends with the elbow capsules



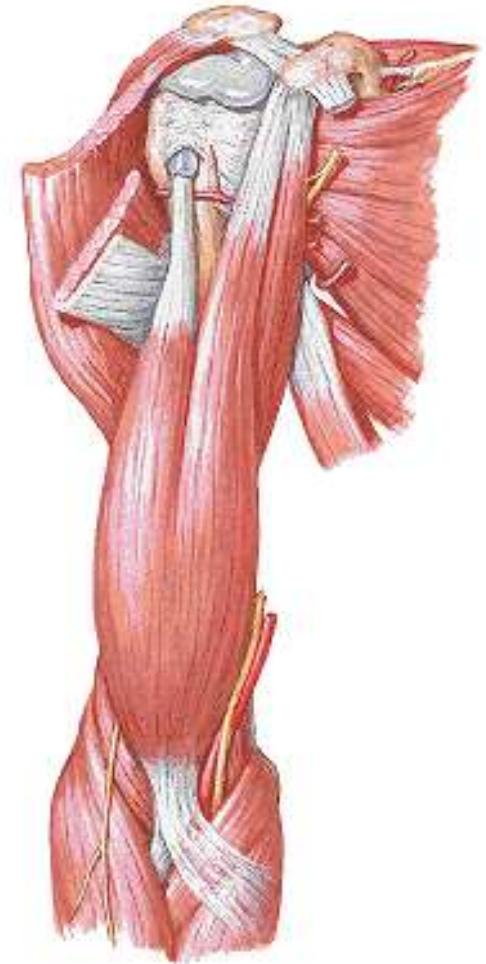
Muscles acting across the elbow

- ◎ Anterior group
 - i. Biceps brachii
 - ii. Brachialis
 - iii. Brachioradialis
 - iv. Pronator teres
 - v. Pronator quadratus
 - vi. Flexor carpi radialis
 - vii. Palmaris longus
 - viii. Flexor carpi ulnaris
- ◎ Posterior group
 - i. Triceps
 - ii. Anconeus
 - iii. Supinator
 - iv. Extensor carpi radialis
 - v. Extensor carpi ulnaris



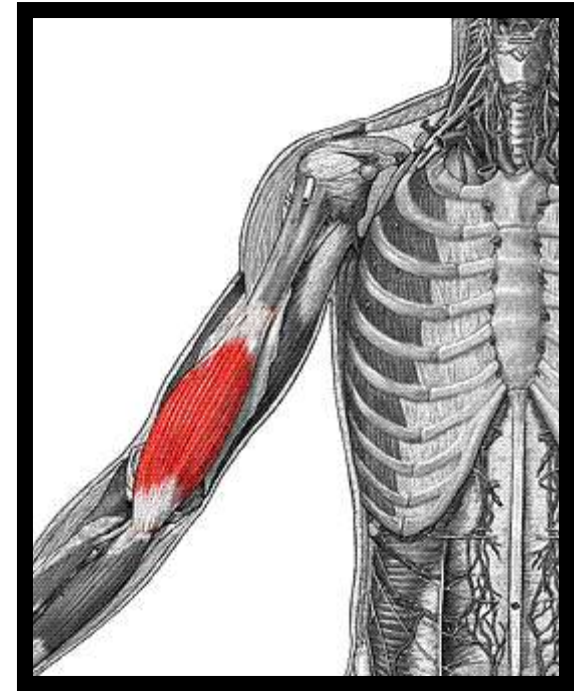
Anterior Group: Biceps Brachii

- **O**: Long head: superior glenoid
– Short head: coracoid
- **I**: Radial tuberosity of the ulna
- **A**: Elbow flexion & supination, shoulder flexion
- **N**: Musculocutaneous



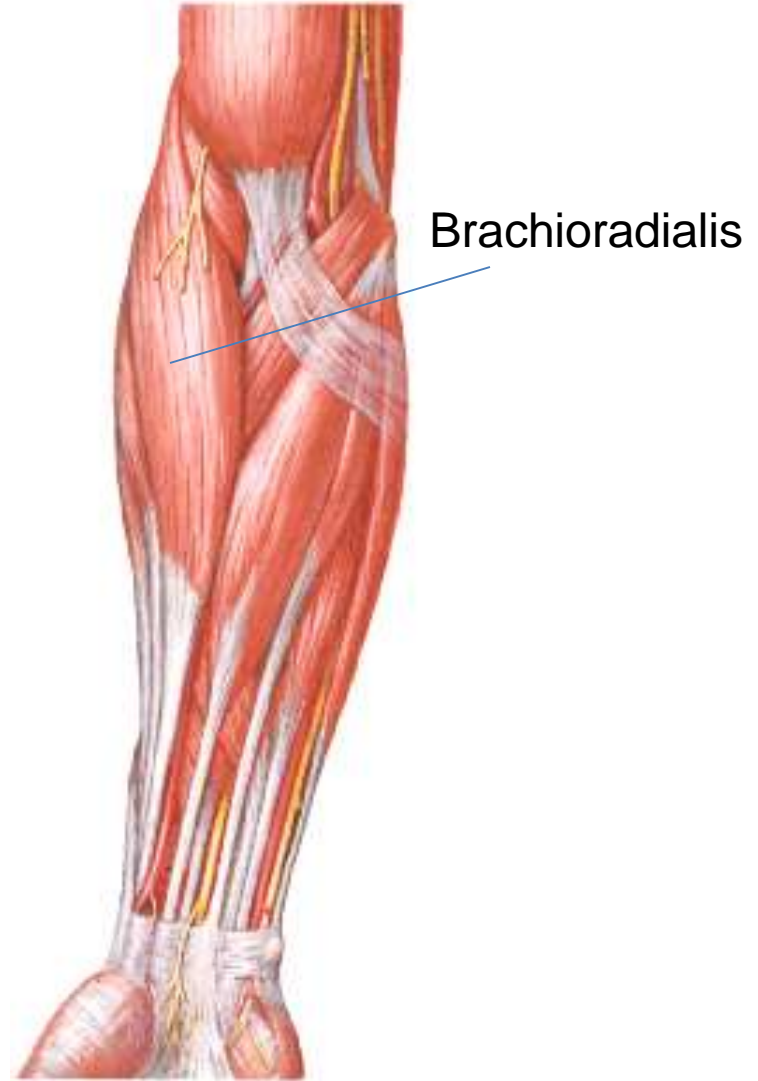
Anterior Group: Brachialis

- **O**: Anterior surface: Distal humerus
- **I**: Tuberosity of the ulna
- **A**: Elbow flexion
- **N**: Musculocutaneous



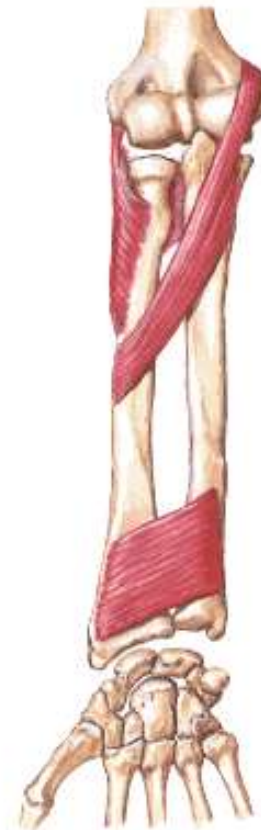Anterior Group: Brachioradialis

- **O**: Lateral supracondylar ridge of the distal humerus
 - **I**: Styloid process of the radius
 - **A**: Elbow flexion
 - **N**: Radial Nerve
- ▶ **Note:**
- i. In the forearm, the brachioradialis overlies the radial nerve and artery
 - ii. Developmentally, brachioradialis belongs to the extensor (Posterior) group of muscles



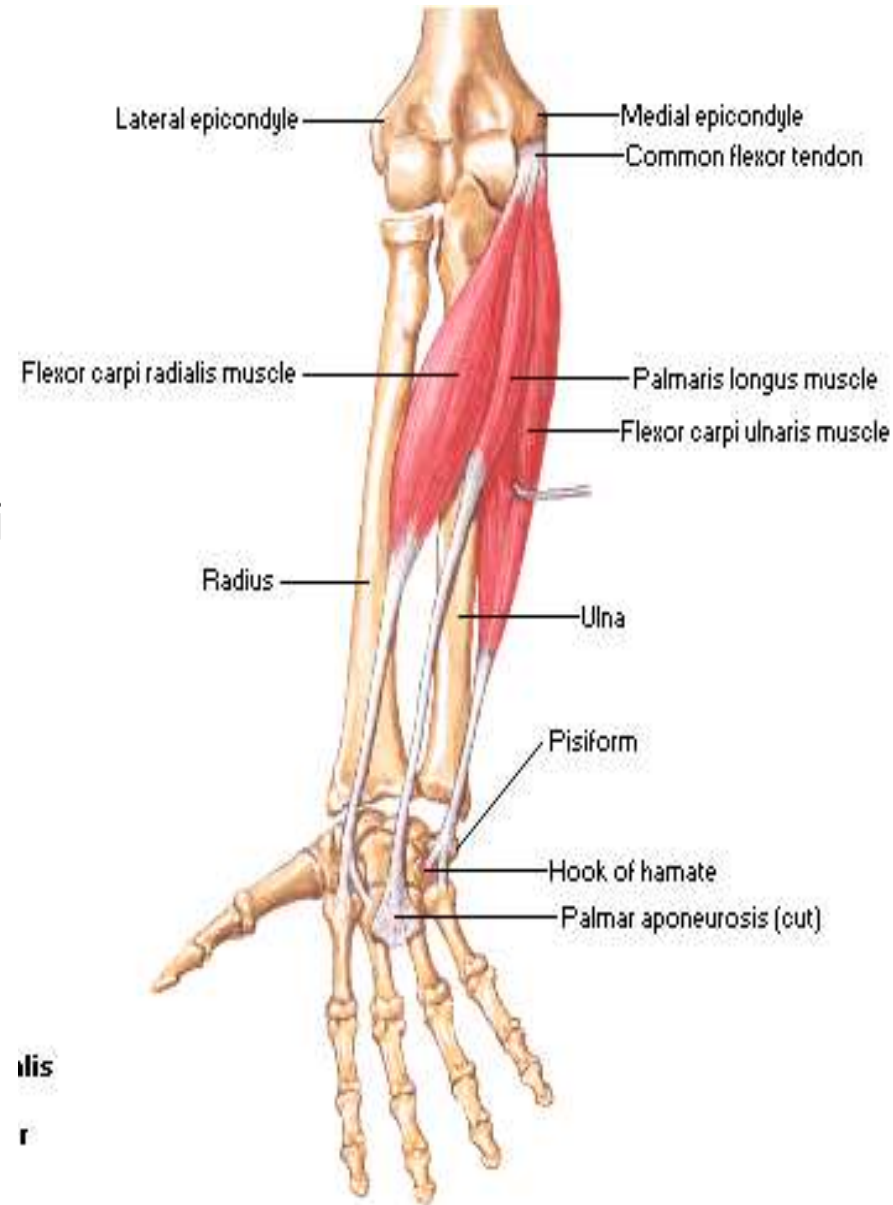
Anterior Group: Pronator Teres

- **O**: Medial distal humerus (condyle) & medial aspect of coronoid process of ulna
- **I**: Lateral aspect of radius; middle 1/3
- **A**: Elbow pronation & flexion
- **N**: Median Nerve
- Note:
 - a) It is the most superficial of the muscles arising from the medial side of the humerus
 - b) It forms the medial border of the cubital fossa



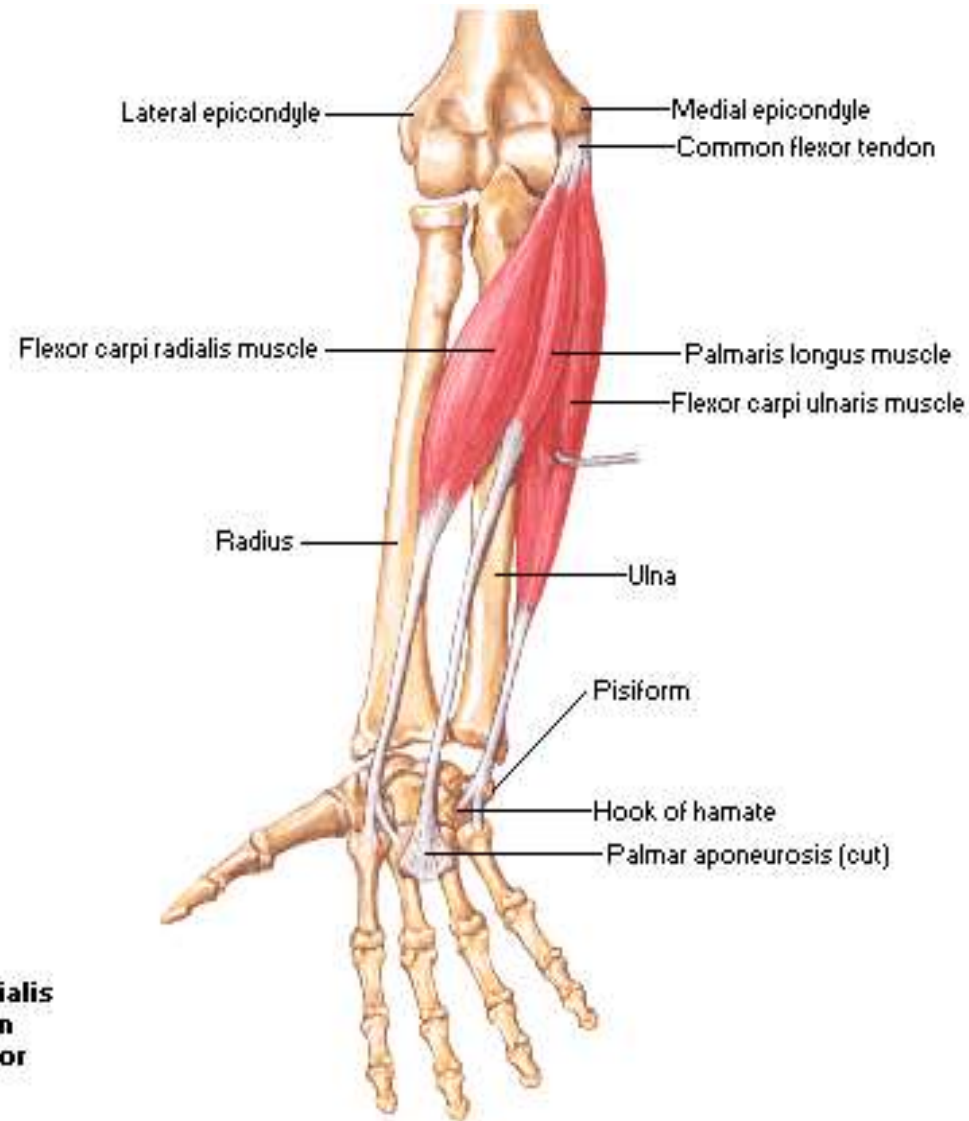
Anterior Group: Flexor Carpi Radialis

- **O**: Medial epicondyle (Common flexor origin)
- **I**: Palmar aspect of base of second metacarpal
- **A**:
 - i. Flexion of the wrist: in conjunction with the Flexor Carpi Ulnaris
 - ii. Abduction of the Wrist: in conjunction with Extensor Carpi Radialis
 - iii. Simultaneously flexes and abducts the wrist when acting alone
- **N**: Median Nerve



Anterior Group: Palmaris Longus

- **O**: Medial epicondyle (Common flexor origin)
- **I**: palmar aponeurosis and part of the flexor retinaculum
- **A**: Flexion of the wrist
- **N**: Median
- **Note:**
 - i. It is absent in about 14-15% of the population
 - ii. At the wrist, it is medial to the Median nerve



Palmaris longus

Anterior Group: Flexor Carpi Ulnaris

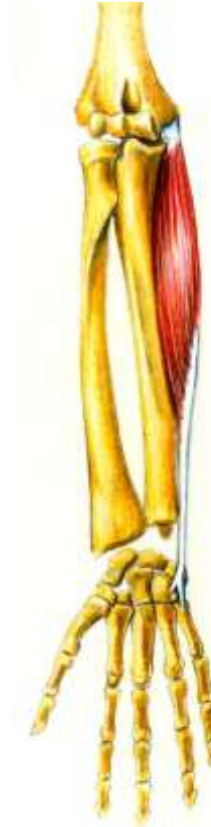- **O**: Humeral head: Medial epicondyle (Common flexor origin)
Ulna head: Olecranium
- **I**: Pisiform, hook of hamate and base of 5th metacarpal
- **A**:
 - i. Flexion of the wrist: in conjunction with the Flexor Carpi Radialis
 - ii. Adduction of the Wrist: in conjunction with Extensor Carpi Ulnaris
 - iii. Simultaneously flexes and adducts the wrist when acting alone
- **N**: Ulnar
- **Note**:
 - i. The most medial of the superficial flexor muscles
 - ii. The ulnar nerve enters the forearm by passing between the humeral and the ulnar heads of its proximal attachment
 - iii. It is the only muscle of the anterior compartment that is FULLY innervated by the ulna nerve

Anterior Group: Flexor Carpi Ulnaris

Posterior view



Anterior view



Posterior Group: Triceps Brachii

○ O:

- i. Long head: infraglenoid tubercle of scapula
- ii. Lateral head: posterior humerus, proximal to the radial groove
- iii. Medial head: posterior humerus, distal to the radial groove

○ I: Olecranal process

○ A:

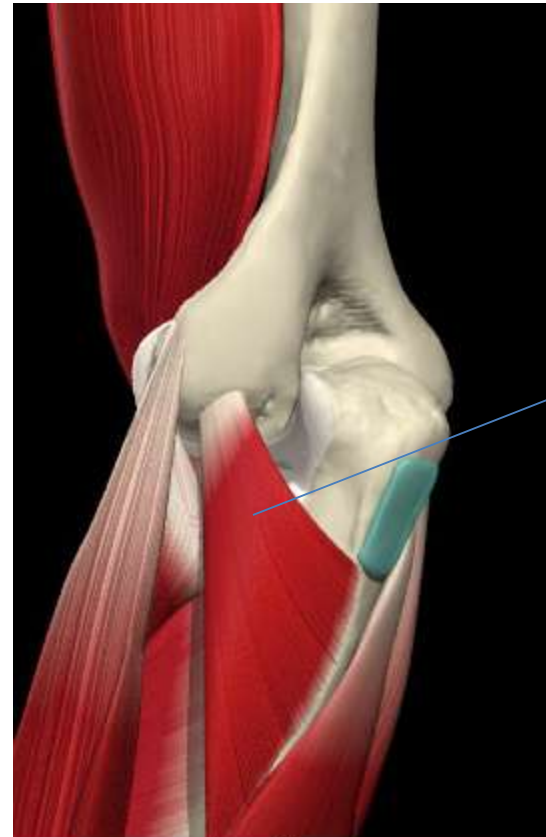- i. Elbow extension,
- ii. weak shoulder extension
- iii. Supports the humeral head in shoulder abductic

○ N: Radial Nerve



Posterior Group: Anconeus

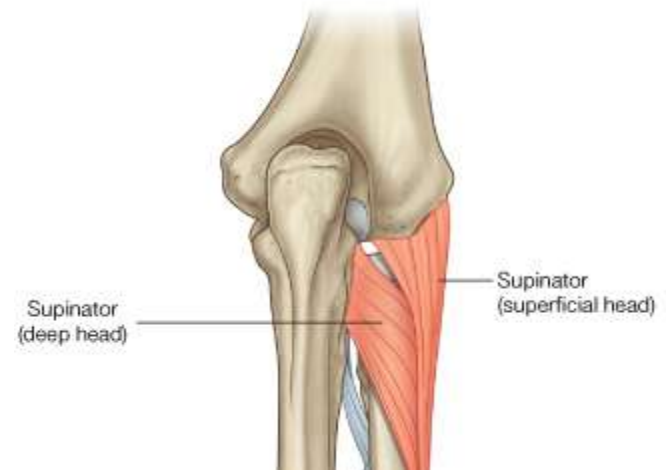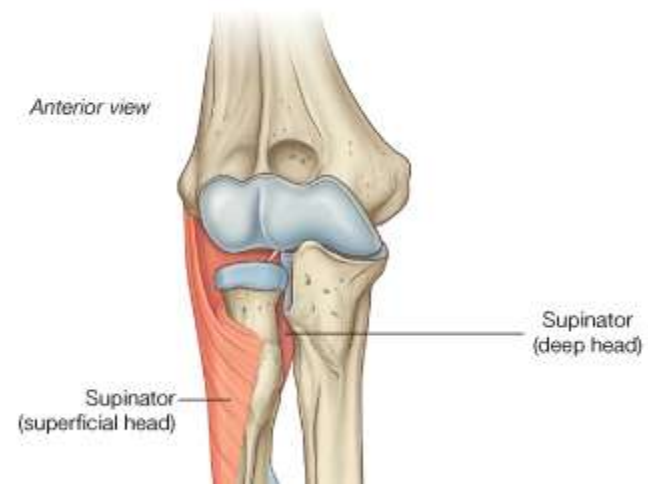
- **O**: Lateral epicondyle of the humerus
- **I**: Lateral surface of the olecranon
- **A**: Assists the Triceps in elbow extension
- **N**: Radial Nerve



Anconeus

Posterior Group: Supinator

- **O: Superficial Head** from lateral epicondyle of humerus
Deep head from supinator crest of ulna
 - **I:** Wraps round the proximal radius to be inserted on its anterior surface
 - **A:** Supination of the forearm
 - **N:** Radial Nerve
-
- **NOTE:**
 - i. Deep branch of radial nerve enters the posterior compartment by passing through the space between the two heads
 - ii. Forms part of the floor of the cubital fossa



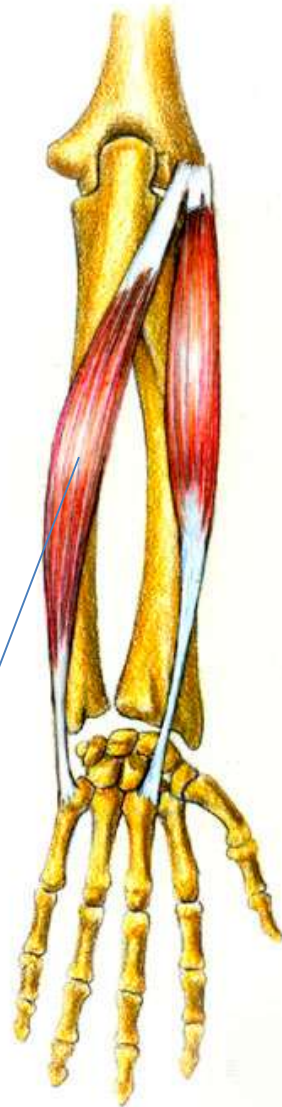
Posterior Group: Extensor Carpi Radialis

- **O:** Lateral supra epicondylar ridge
- **I:** Dorsum of the base of 2nd metacarpal
- **A:**
 - Extension and abduction of the hand at the wrist (When acting alone)
 - Pure extension of the Wrist: in conjunction with Extensor Carpi Ulnaris
 - Pure abduction of the Wrist: in conjunction with Flexor Carpi Radialis
- **N:** radial



Posterior group: Extensor Carpi Ulnaris

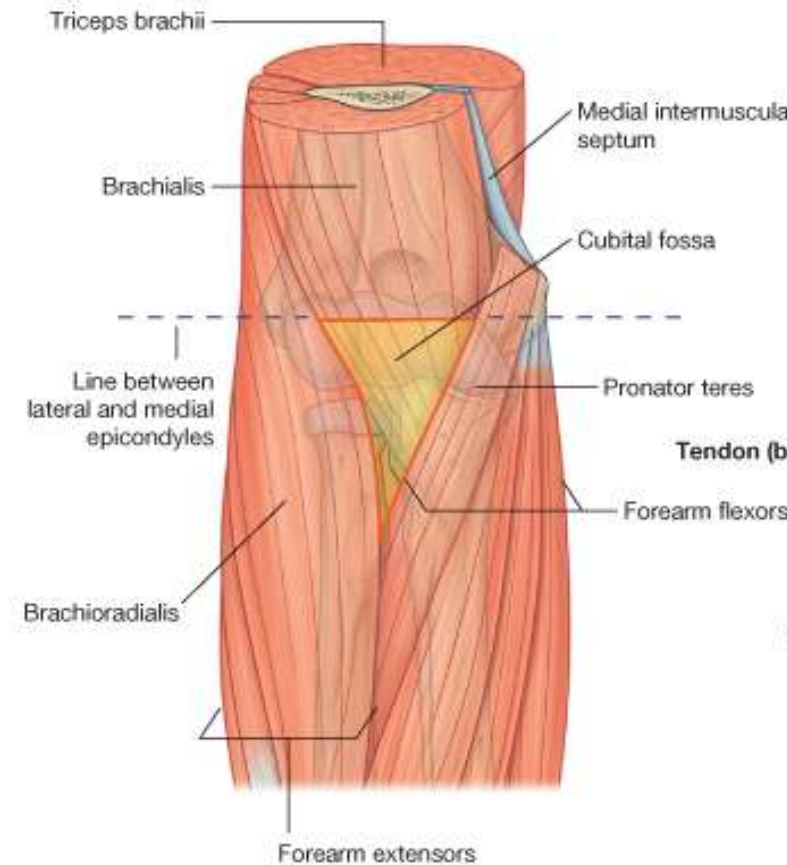
- **O:**
 - **Humeral Head:** Lateral epicondyle (Common extensor origin)
 - **Ulna head:** Posterior border of the ulna through aponeurotic attachment
- **I:** Dorsal aspect of base of 5th metacarpal
- **A:**
 - Extension and adduction of the wrist (When acting alone)
 - Pure extension of the Wrist: in conjunction with Extensor Carpi Radialis
 - Pure adduction of the Wrist: in conjunction with Flexor Carpi Ulnaris
- **N:** Radial nerve



Extensor Carpi Ulnaris

Cubital Fossa

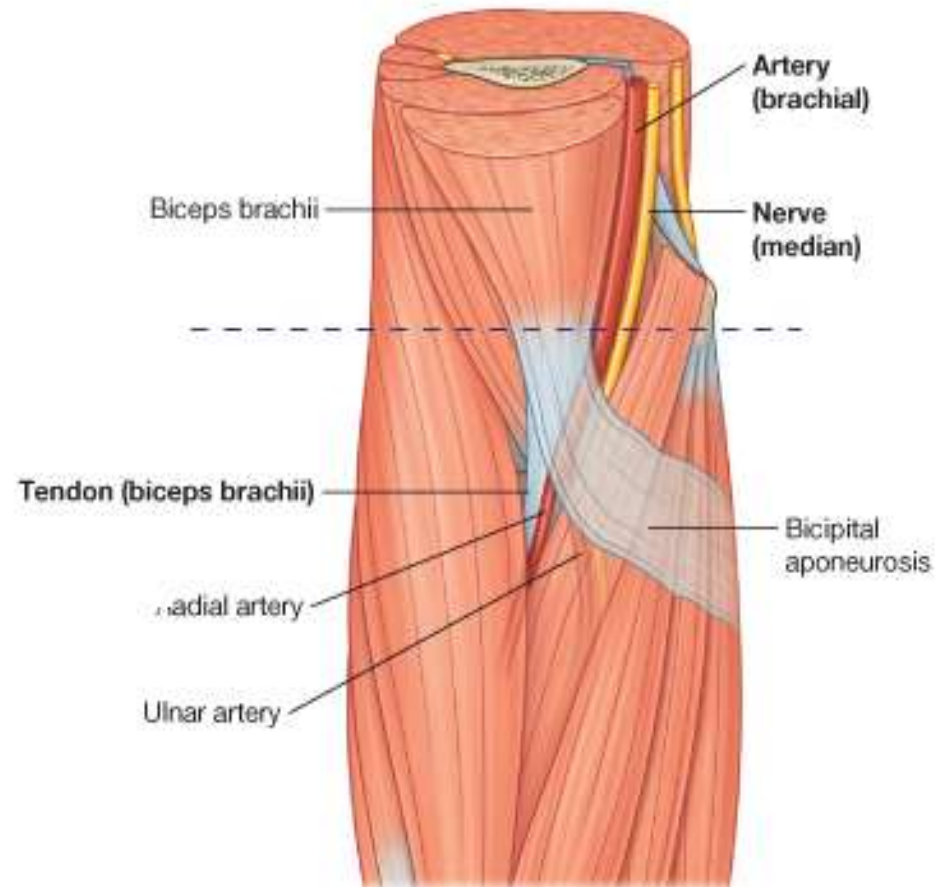
- Triangular area anterior to the elbow and between:
 - Brachioradialis muscle originating from the lateral supracondylar ridge of the humerus
 - Pronator teres muscle originating from the medial epicondyle of the humerus
 - Base of the triangle is an imaginary horizontal line between the medial and lateral epicondyles
- Floor is the brachialis muscle.
- Roof is formed by superficial fascia and skin



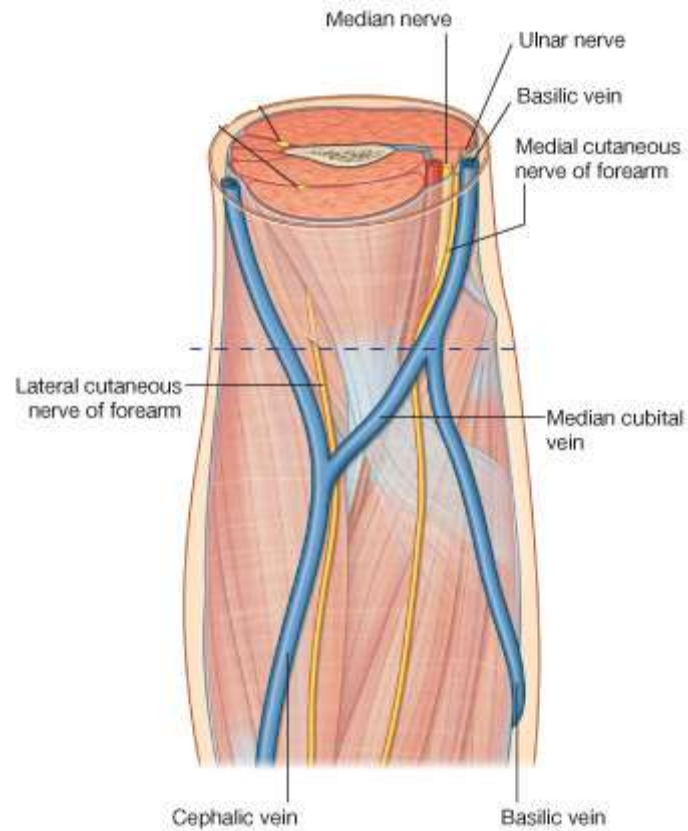
Cubital Fossa: Contents

From lateral to medial:

1. Tendon of the biceps brachii muscle
 2. Brachial artery
 3. Median nerve
- Crossed on the lower part by the bicipital aponeurosis
 - Within the roof are:
 1. Median cubital vein
 2. Medial cutaneous nerve of the forearm
 3. Lateral cutaneous nerves of the forearm

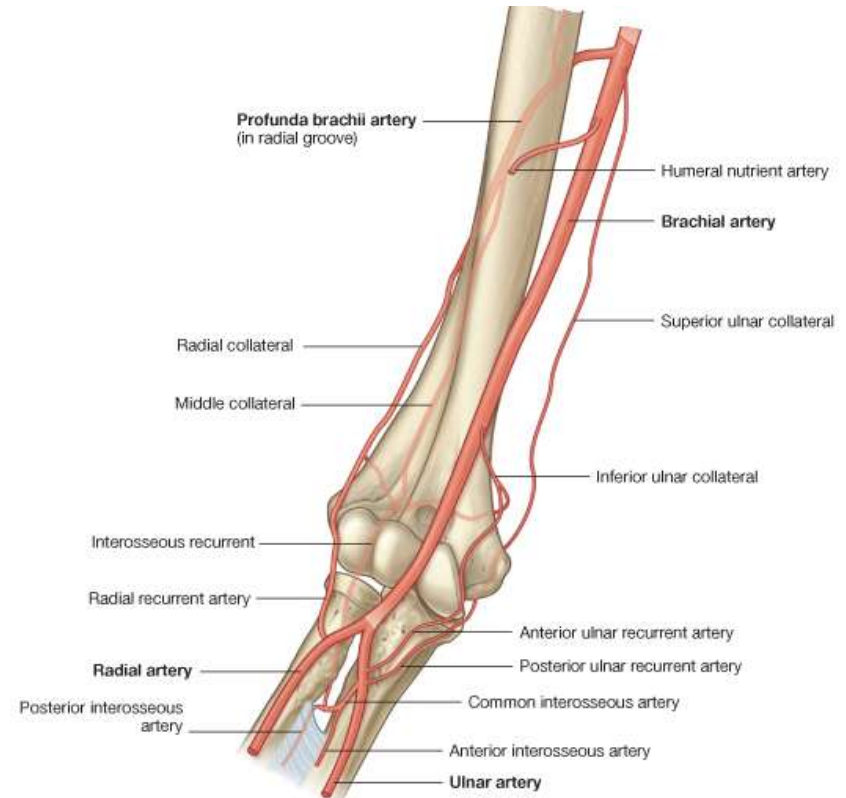


Cubital Fossa: Superficial contents



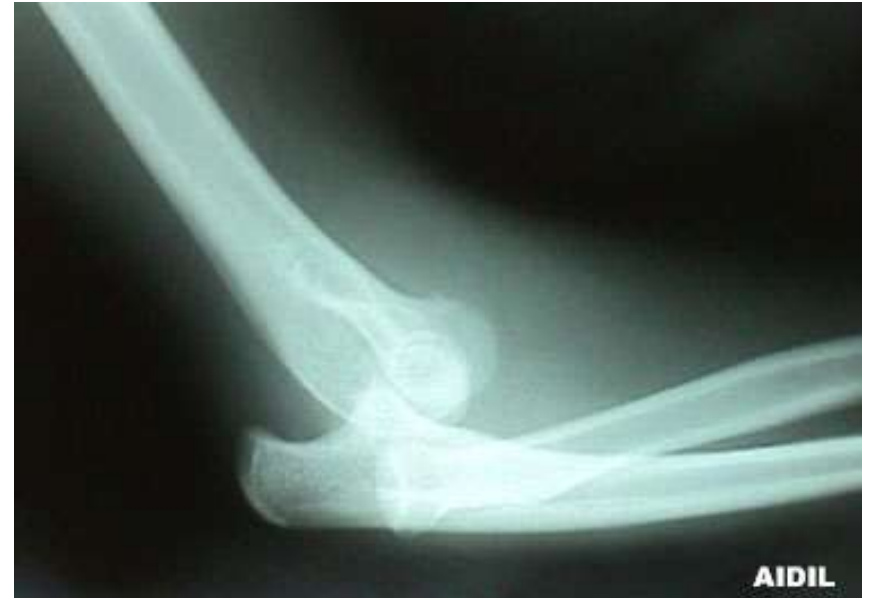Elbow: Blood supply

- The elbow anastomosis is made up of 8 arteries:
 - 2 Branches of Brachial artery: Superior and Inferior ulna collateral arteries
 - 2 branches of Profunda brachii: Radial and Middle Collateral arteries
 - 2 Branches of Ulna Artery: Anterior and Posterior Ulna Recurrent Arteries
 - 1 from Radial Artery: Radial Recurrent artery
 - 1 from Common Interosseus Artery: Interosseous Recurrent Artery



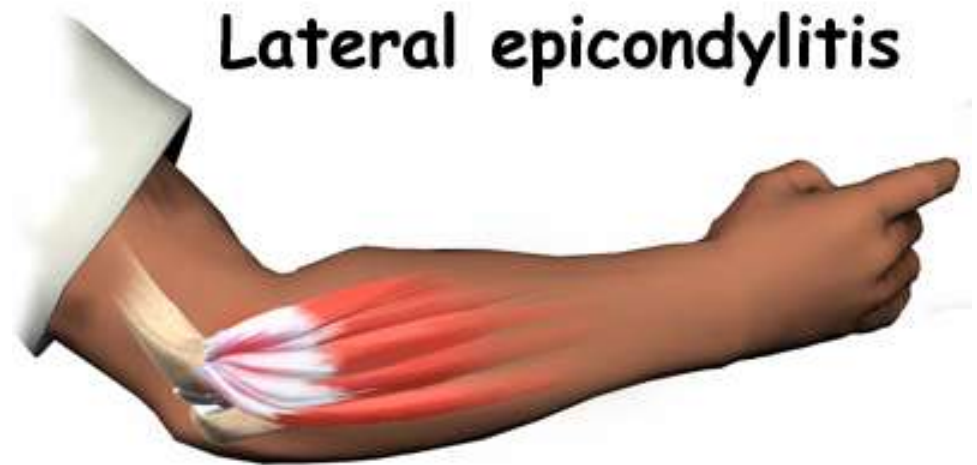Clinical Anatomy 1

- Dislocation of the Elbow
 - This occurs when the trochlear shifts from the trochlear fossa
 - Usually as the result of severe trauma
 - Diagnosis usually confirms by x-ray



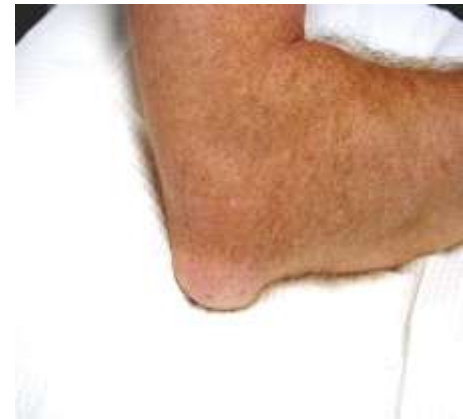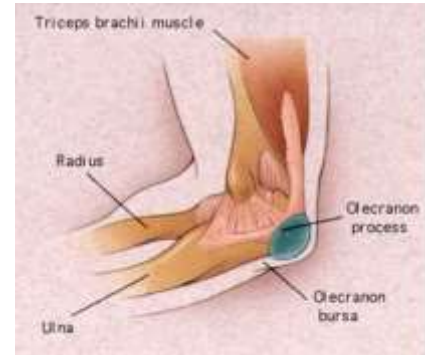Lateral Epicondylitis

- “Tennis Elbow”
- Caused by excessive wrist extension, especially with a clenched fist
- Pain over outer part of the elbow



Olecranon Bursitis

- A collection of fluid in the olecranon bursa that covers the posterior tip of the elbow.
- It is the result of direct trauma to the elbow



Radial Head Dislocation (Pulled Elbow)



Wrong Way!

Radial Head Dislocation (Pulled Elbow)

- The radial head may be displaced forward, backward or outward
- Children under 5 are prone to subluxation of the radial head due to a “pulling” on the forearm
- Commonly called “pulled elbow” or “Nursemaid’s arm”

Merci

