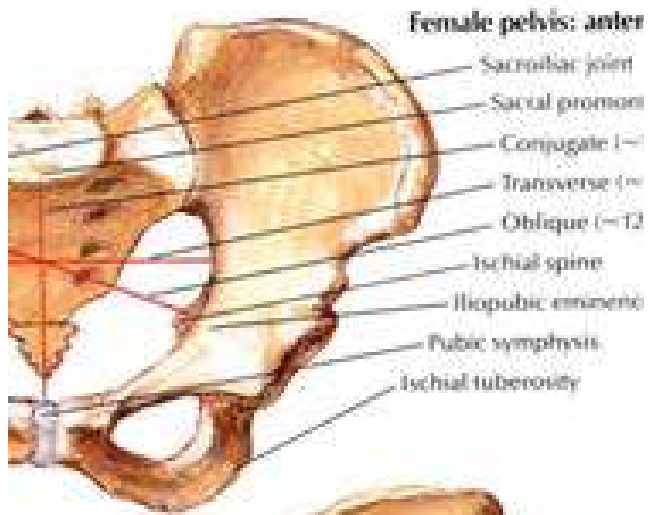
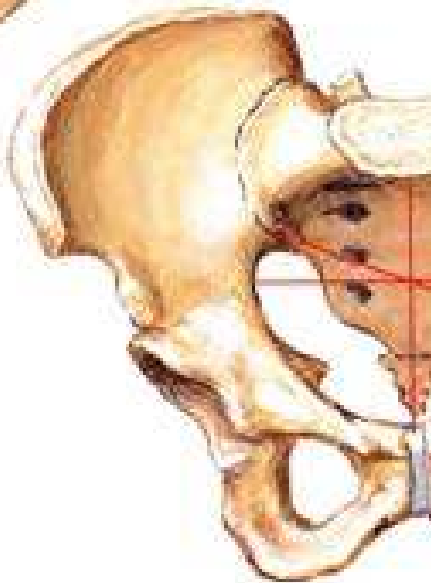


APPLIED ANATOMY OF THE PELVIS

Dr Oluwadiya
Kehinde Sunday
www.oluwadiya.com



anterior view



Functions of the bony pelvis

- Protects the pelvic viscera
- Supports and transmits body weight to the lower limbs
- Provides attachment for muscles
- Provides bony support for the birth canal in the females
- The side to side swing of the pelvis during locomotion helps in smoothening the gait

Gender Differences in the Pelvis

- The differences between the bony pelvis in males and females are basically for two reasons:
 - i. The heavier build and stronger muscles in the male account for the stronger bone structure and better defined muscle markings in the male
 - ii. The need for a wide canal to accommodate fetus in labour accounts for the comparatively wider and shallower pelvic cavity in the female.

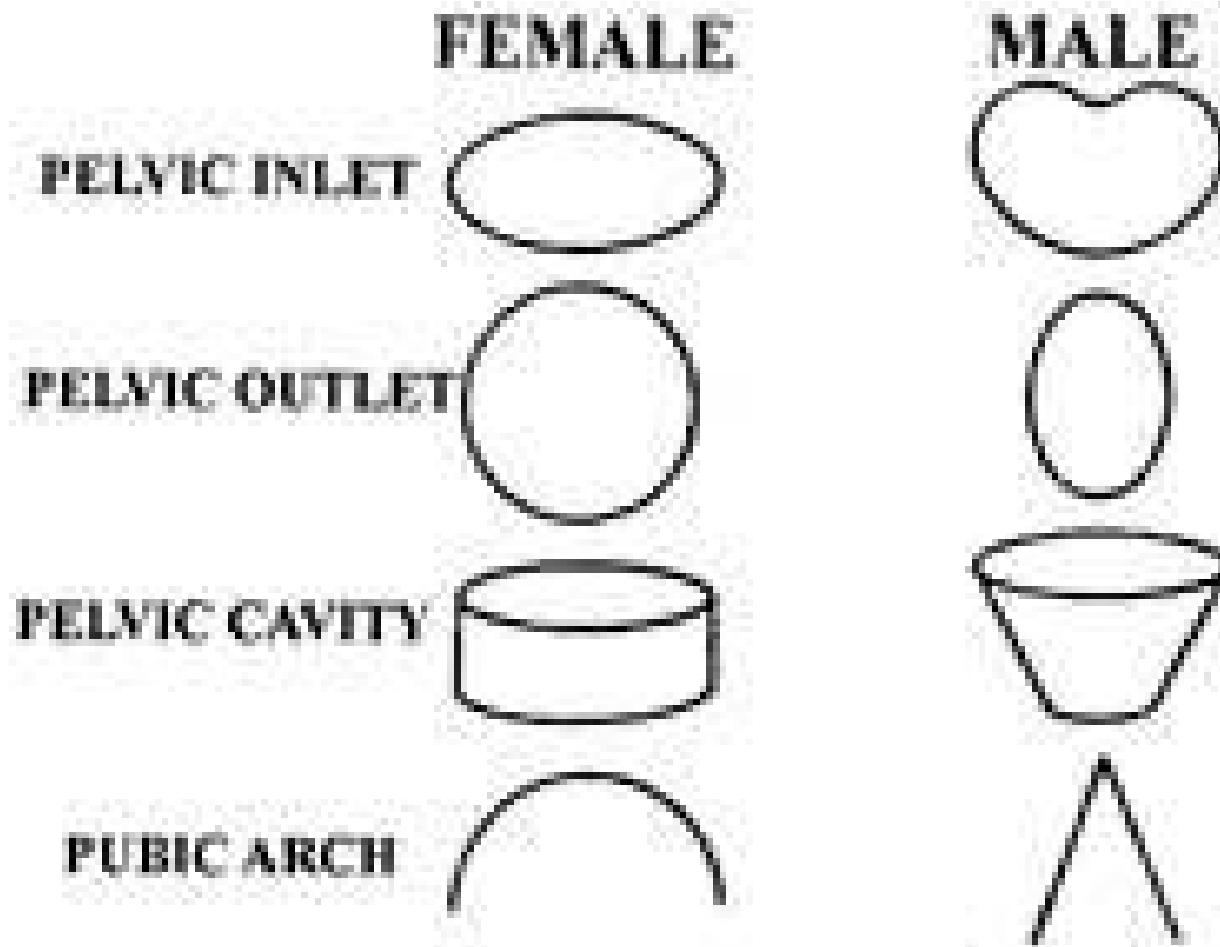
Gender Differences in the Pelvis

- Of course, the most important clinical correlate of the gender differences in the pelvis is that the female pelvis is adapted for childbirth
- The other important reason is that the shape helps forensic pathologists to determine the sex of the skeleton in missing persons cases

The Pelvis: Gender Differences

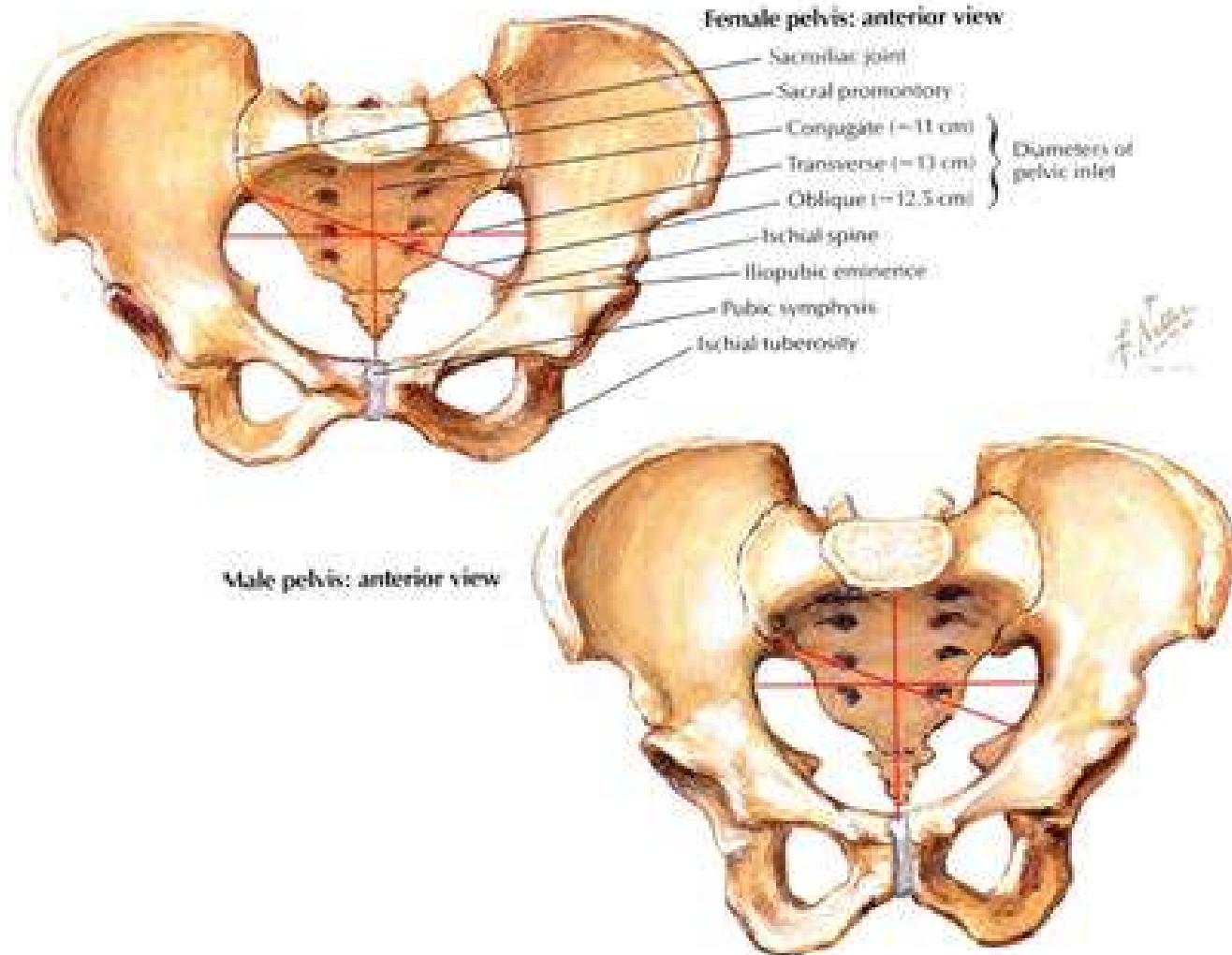
MALE	CHARACTERISTIC	FEMALE
Less forward	Tilt	Far forward
Heavier	Thickness	Lighter
Large, closer together	Acetabulum	Small, farther apart
Acute, 50-60 degrees	Pubic arch	Less acute 80-90 degrees
Narrow, longer	Sacrum	Wider, shorter
Narrow, heart shaped	Pelvic inlet	Wider, oval
Narrow	Pelvic outlet	wider

The Pelvis: Gender Differences



The Pelvis: Gender Differences

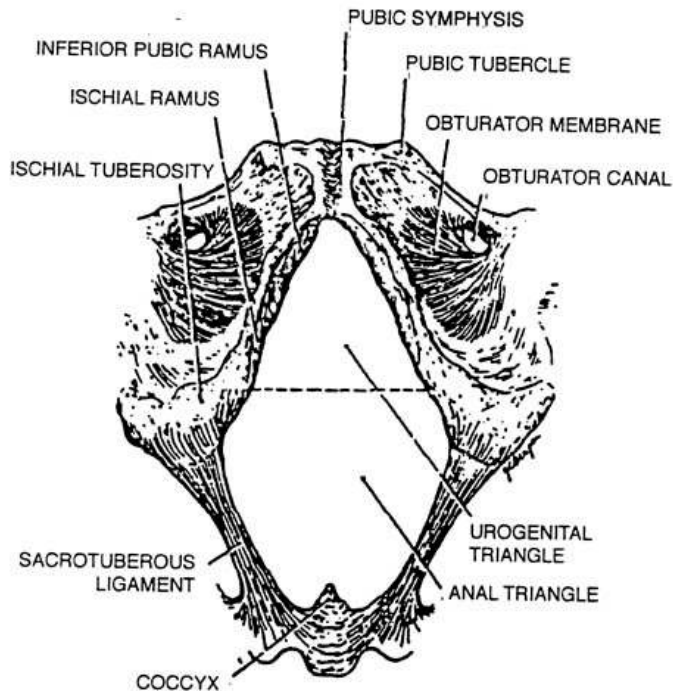
1. PELVIC INLET



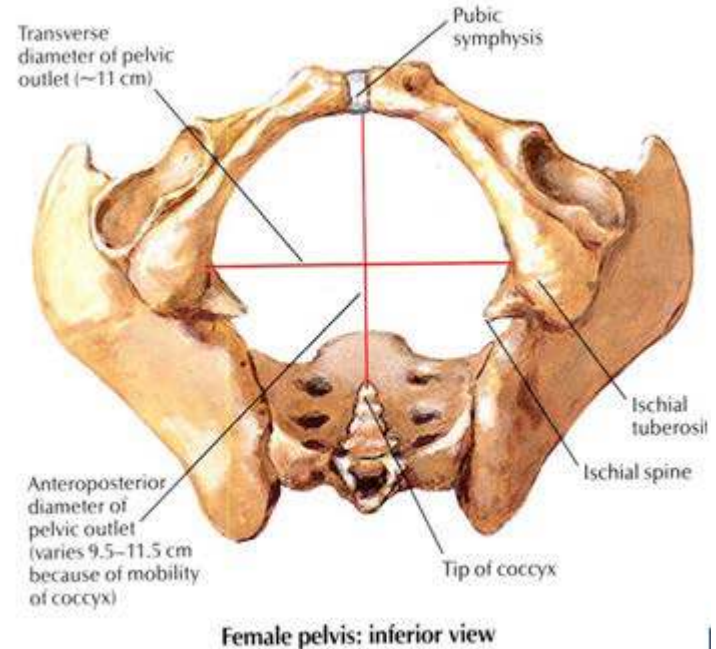
The Pelvis: Gender Differences

2. PELVIC OUTLET

MALE

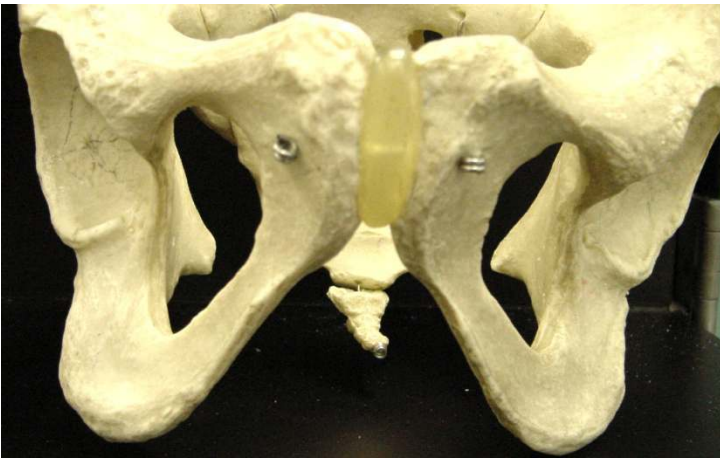


FEMALE

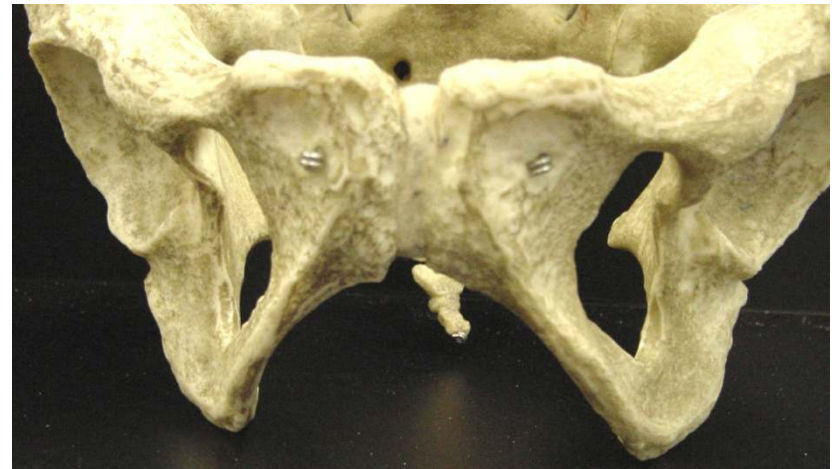

The Pelvis: Gender Differences

3. PUBIC ARCH AND ANGLE



MALE

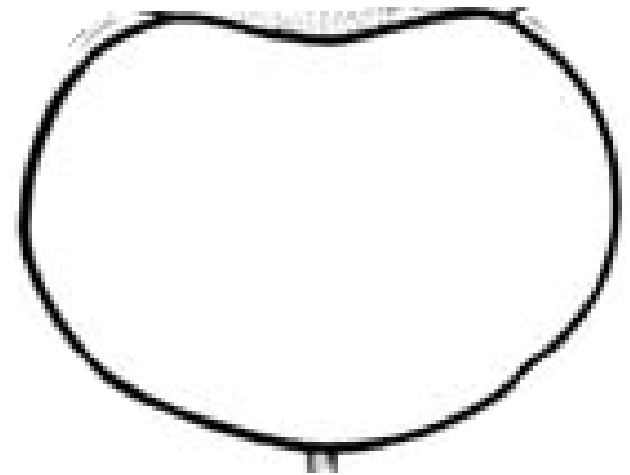


FEMALE

Female Pelvic Shapes

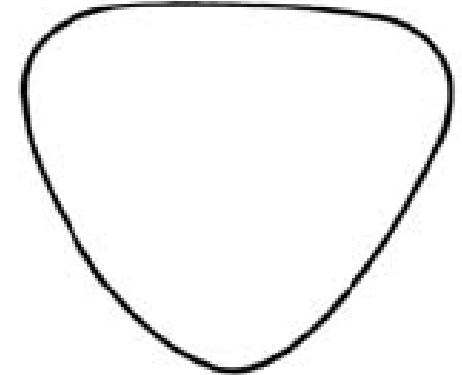
1-GYNECOID

- Typical female pelvis found in about 50% of women
- Rounded—slightly oval inlet
- Straight pelvic sidewalls with roomy pelvic cavity
- Good sacral curve
- Ischial spines are not prominent
- Pubic arch is wide



Female Pelvic Shapes

2-ANDROID




- It is a male type pelvis.
- Seen in about 20% of women. More common in Whites
- Inlet is triangular or heart-shaped with anterior narrow apex.
- Side walls are converging (funnel pelvis) with projecting ischial spines.
- Sacro-sciatic notch is narrow.
- Subpubic angle is narrow $<90^\circ$

Female Pelvic Shapes

3-ANTHROPOID

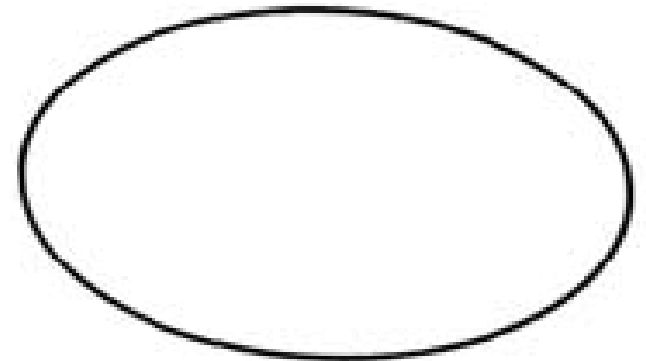
- Ape-like type
- Seen in 25% of women (More common among non-White races)
- All anteroposterior diameters are long.
- All transverse diameters are short.
- Sacrum is long and narrow.
- Sacro-sciatic notch is wide.
- Subpubic angle is narrow



Female Pelvic Shapes

4-PLATYPELLOID

1. 3-5% of women
2. It is a flat female type.
3. All anteroposterior diameters are short.
4. All transverse diameters are long.
5. Sacro-sciatic notch is narrow.
6. Subpubic angle is wide.



Rectovesical/Rectouterine pouches

- These pouches are sacs within the posterior portions of the pelvic cavities.
- In males: RECTOVESICAL POUCH
- In females: RECTOUTERINE POUCH
- Debris can accumulate in these cavities and be a source of infection.

Rectovesical/Rectouterine pouches

- It is much easier to evacuate accumulated fluid (pus, blood) from the pouch in females.
- This will be through the posterior fornix of the vagina.
- In males, such feat will have to be accomplished through the abdomen (laparotomy)

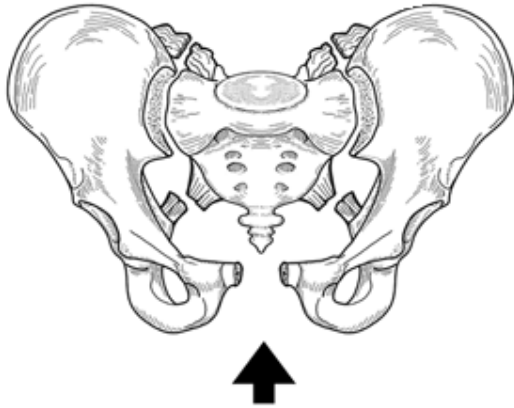
Trauma

- i. Fractures
- ii. Soft tissue injuries
 - Lower urinary tract
 - Vascular injuries
 - Viscera injuries
- iii. Combination of the two

Fractures and dislocations

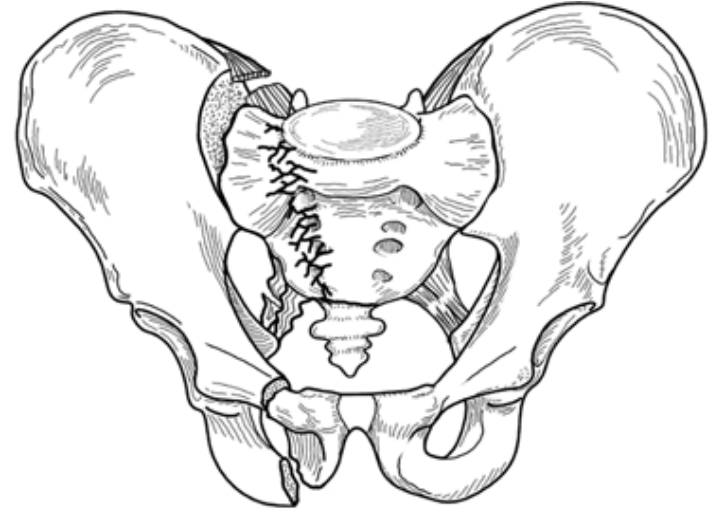
- Can affect any of the pelvic bones (ilium, pubis, ischium, sacrum or the coccyx)
- Can result from minor or major force
- May be accompanied by major and life-threatening soft tissue injuries

Fractures and dislocations



Source: Simon RR, Sherman SC, Koenigsknecht SJ: *Emergency Orthopedics, The Extremities*, 5th Edition: <http://www.accessmergencymedicine.com>

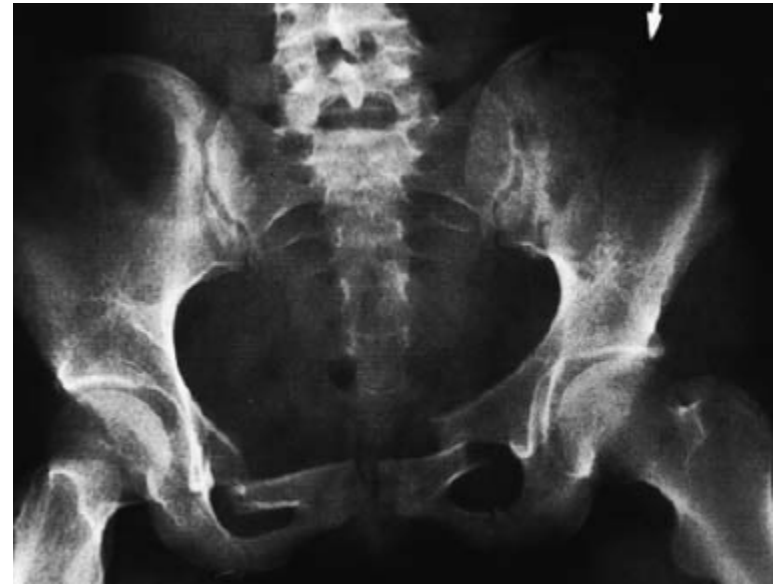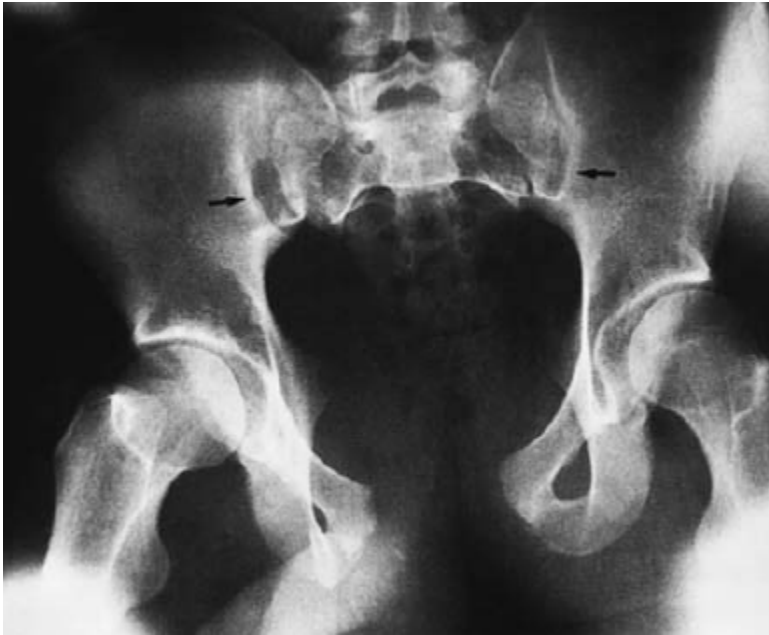Copyright © The McGraw-Hill Companies, Inc. All rights reserved.



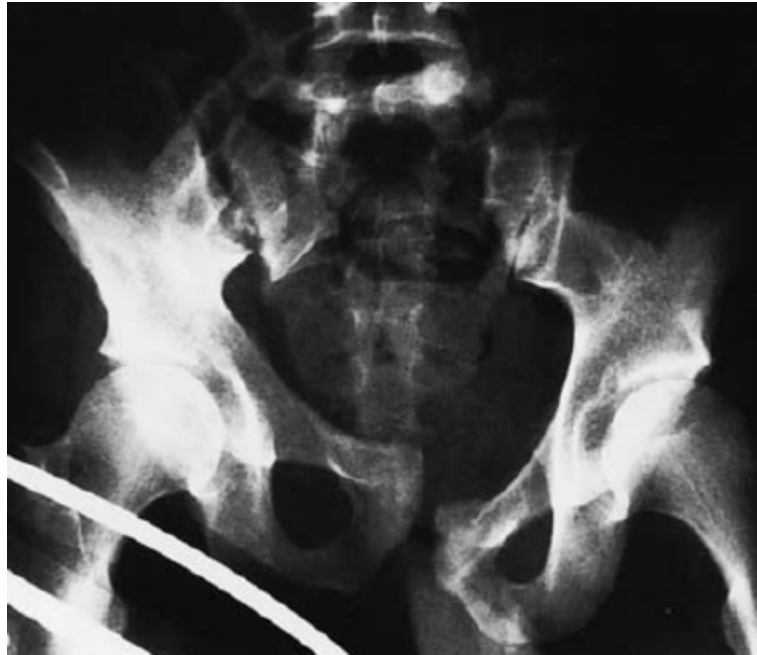Source: Simon RR, Sherman SC, Koenigsknecht SJ: *Emergency Orthopedics, The Extremities*, 5th Edition: <http://www.accessmergencymedicine.com>

Copyright © The McGraw-Hill Companies, Inc. All rights reserved.

Fractures and dislocations



Fractures and dislocations



Injuries of the Lower Urinary Tract

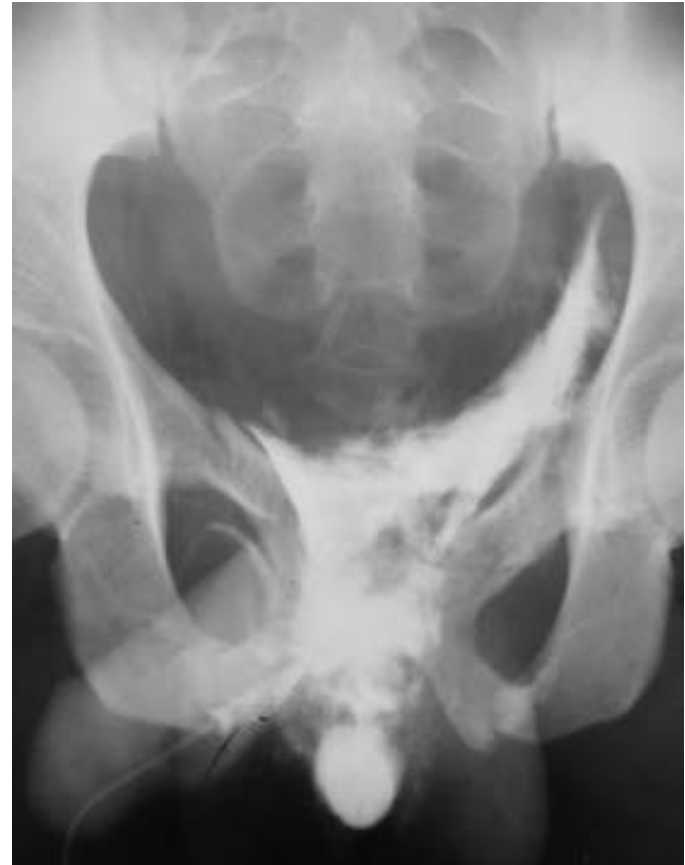- Urethra
- Bladder.
- May be complete or incomplete tears

Urethra Injuries

- Males are by far, more commonly affected
- Most commonly affected is the posterior urethra.
- Anterior urethra is less commonly affected
- Female urethra injuries rare.

Urethra Type Injuries

- Extravasation of urine:
Base of bladder, scrotum,
and lower anterior
abdominal wall.
- Urine does not get into
the thigh or posterior half
of the perineum (over the
anal triangle) due to the
attachment of the
Scarpal's fascia to the
posterior part of the
perineal membrane



Bladder Injuries

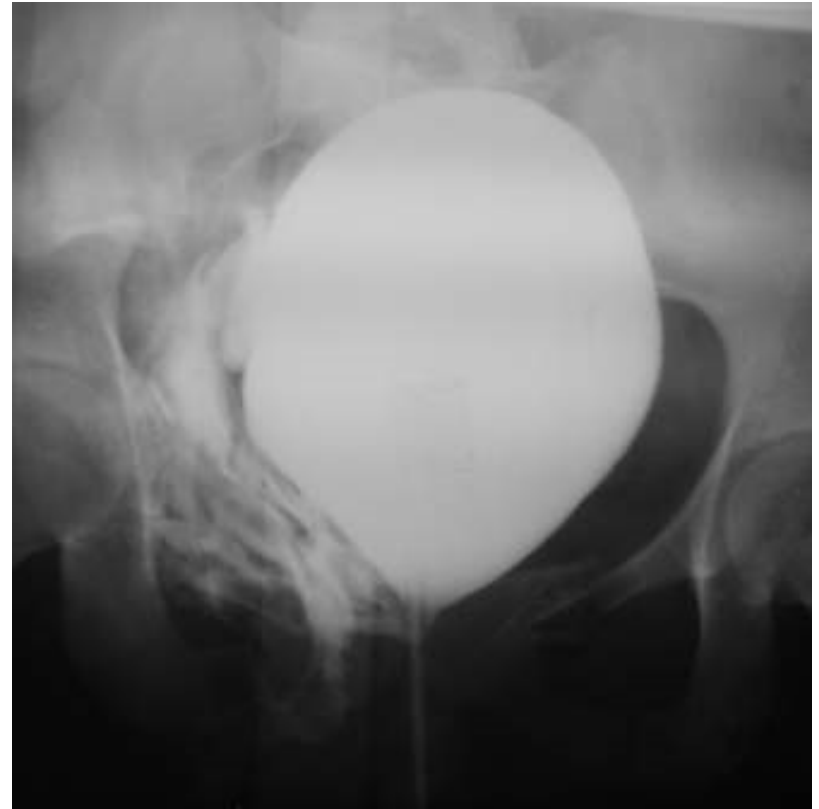
Extraperitoneal

Intraperitoneal

Combined

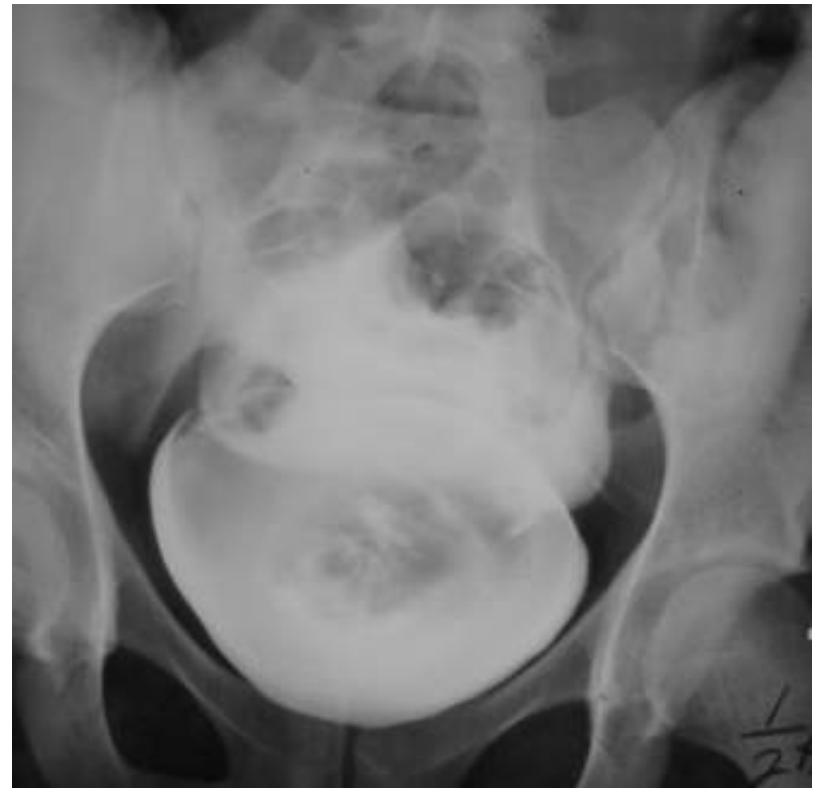Extraperitoneal Rupture

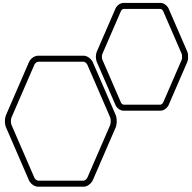
- 2-3 times more common than intraperitoneal injury
- Anterior pelvis fractures
- Injury is at bladder base
- Extravasation around base of bladder
- Management: Divert with suprapubic catheter and debride



Intraperitoneal Rupture

- Often no pelvis fractures, usually blow to full bladder
- Dome is injury site
- Contrast in paracolic gutters and around bowel
- May lead to peritonitis





PLEASE JOIN THE FORUM AT
WWW.OLUWADIYA.COM TO
ASK QUESTIONS

THE END