

Forearm Anatomy II The Extensor compartment

Prof. Oluwadiya KS
www.oluwadiya.com



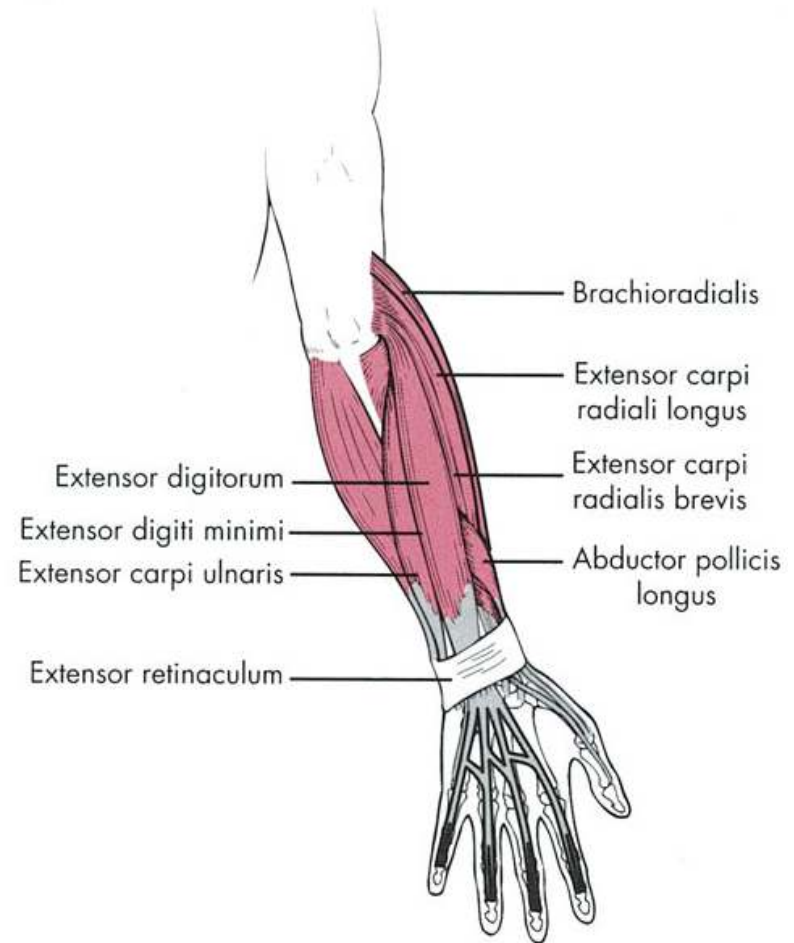
Muscles of the posterior compartment

Two layers:

- i. Superficial
- ii. Deep layer

Their functions

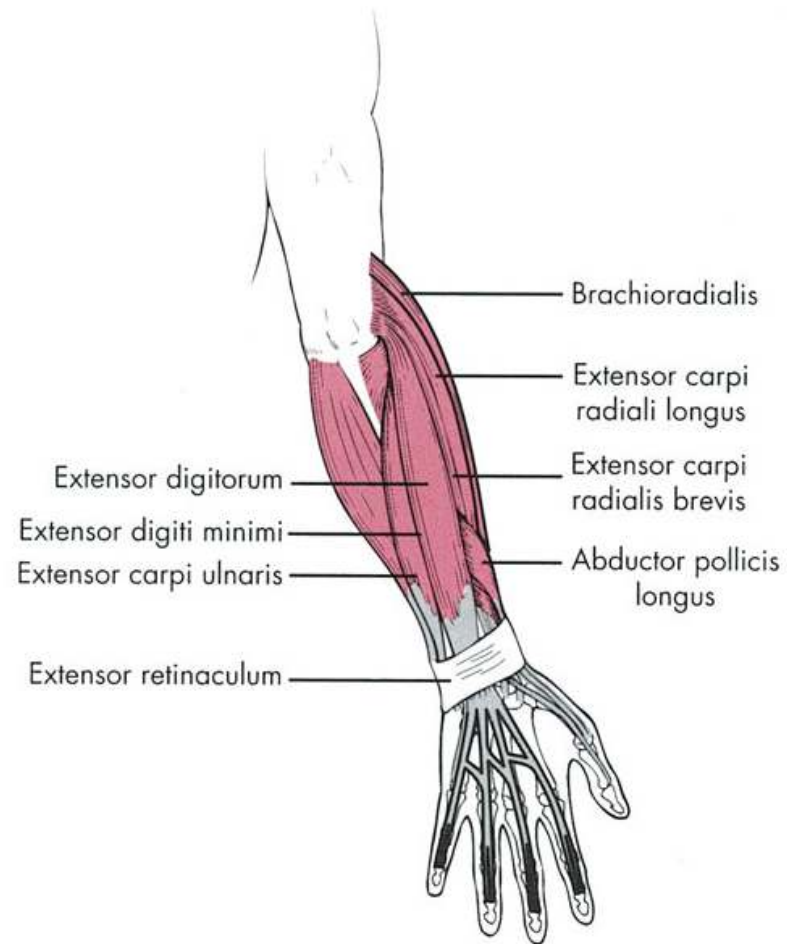
- i. Movement at the wrist joint
- ii. Extension of the fingers and thumb
- iii. Supination



Muscles of the posterior compartment: Superficial Layer

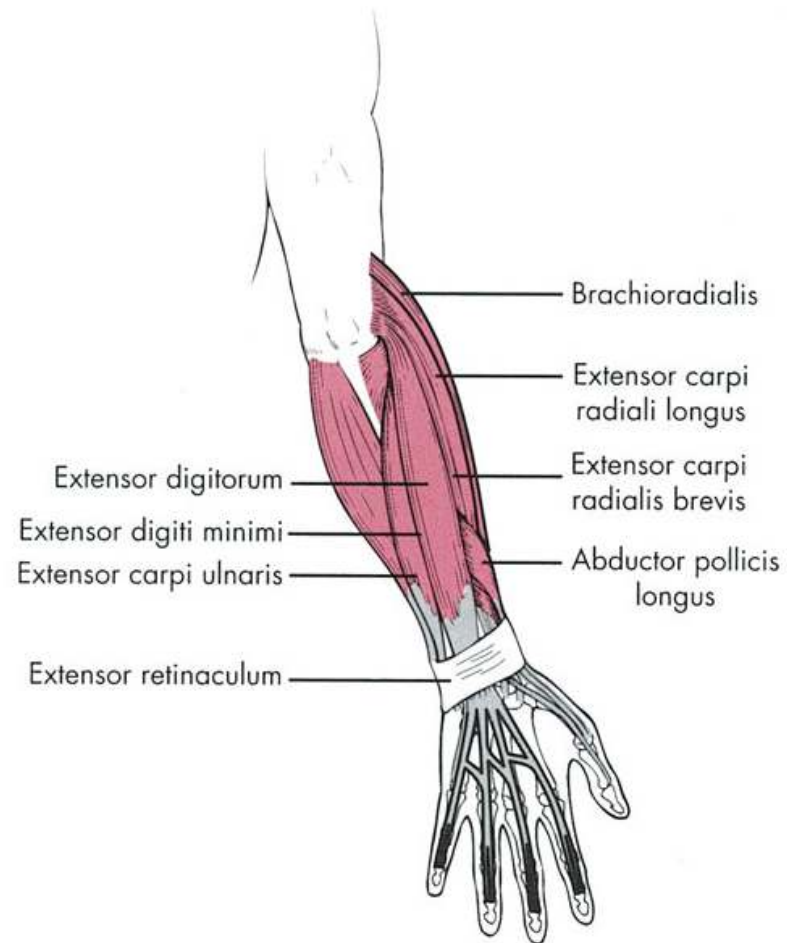
Seven Muscles

- i. Brachioradialis
- ii. Extensor carpi radialis longus
- iii. Extensor carpi radialis brevis
- iv. Extensor digitorum
- v. Extensor digiti minimi
- vi. Extensor carpi ulnaris
- vii. Anconeus



Muscles of the posterior compartment: Superficial Layer

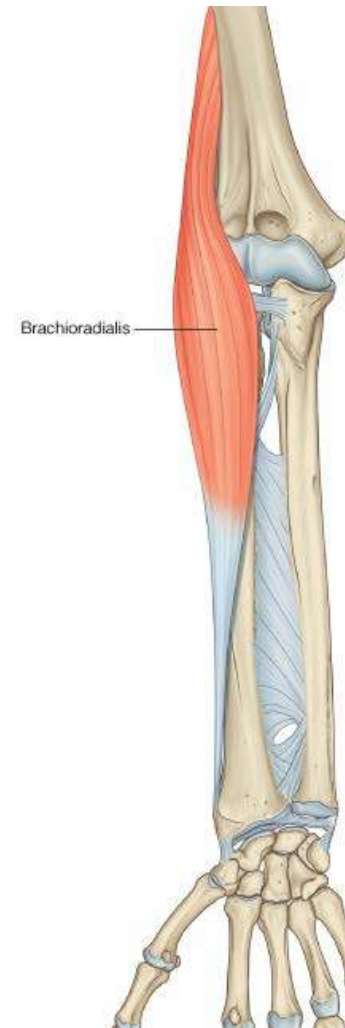- All 7 muscles have a common origin from the supraepicondylar ridge and lateral epicondyle of the humerus
- All are innervated by the Radial Nerve
- Except for the Anconeus and Brachioradialis; all cross the wrist joint to insert in the hand



Muscles of the posterior compartment:

Superficial Layer: Brachioradialis

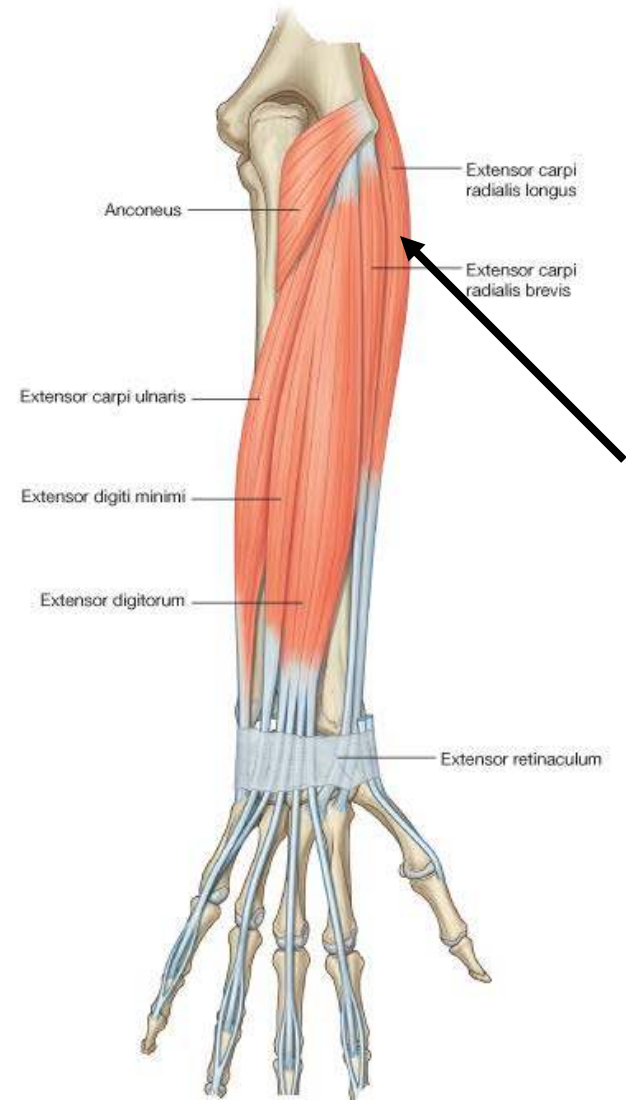
- O:** lateral supraepicondylar ridge of humerus
- I:** Lateral surface of distal end of radius
- A:** Elbow flexion especially with the arm in mid-pronation
- N:** Radial nerve



Muscles of the posterior compartment:

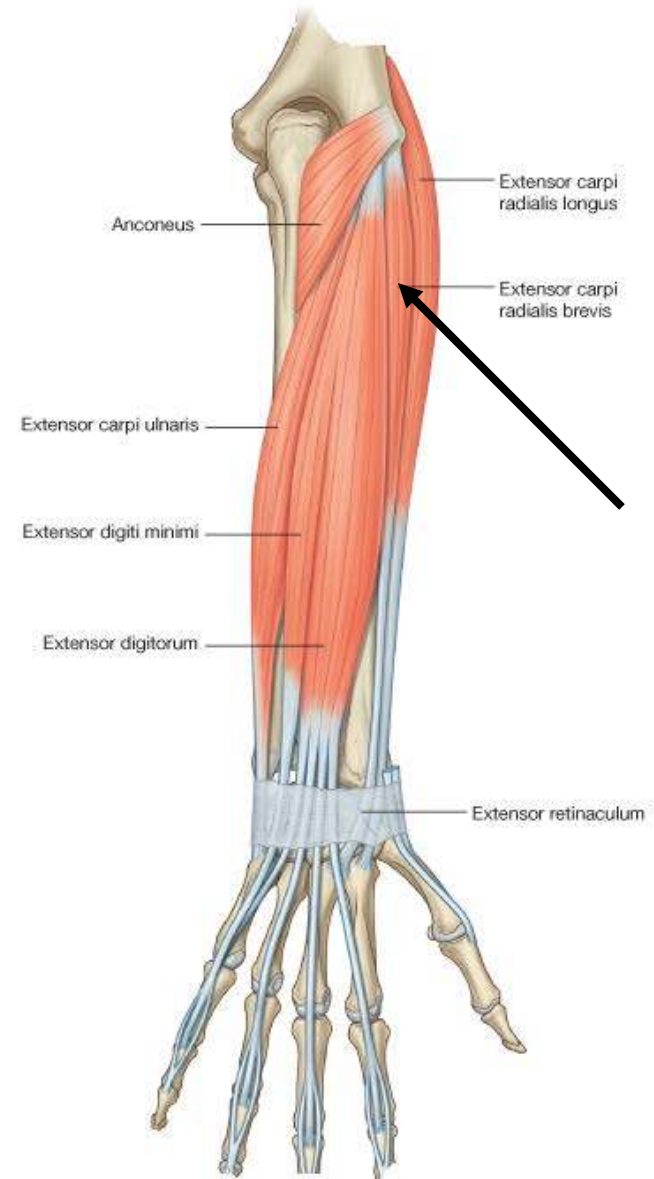
Superficial Layer: Extensor Carpi Radialis Longus

- O:** lateral supraepicondylar ridge of humerus
- I:** Dorsal surface of base of metacarpal II
- A:** Extends and abducts the wrist
- N:** Radial nerve



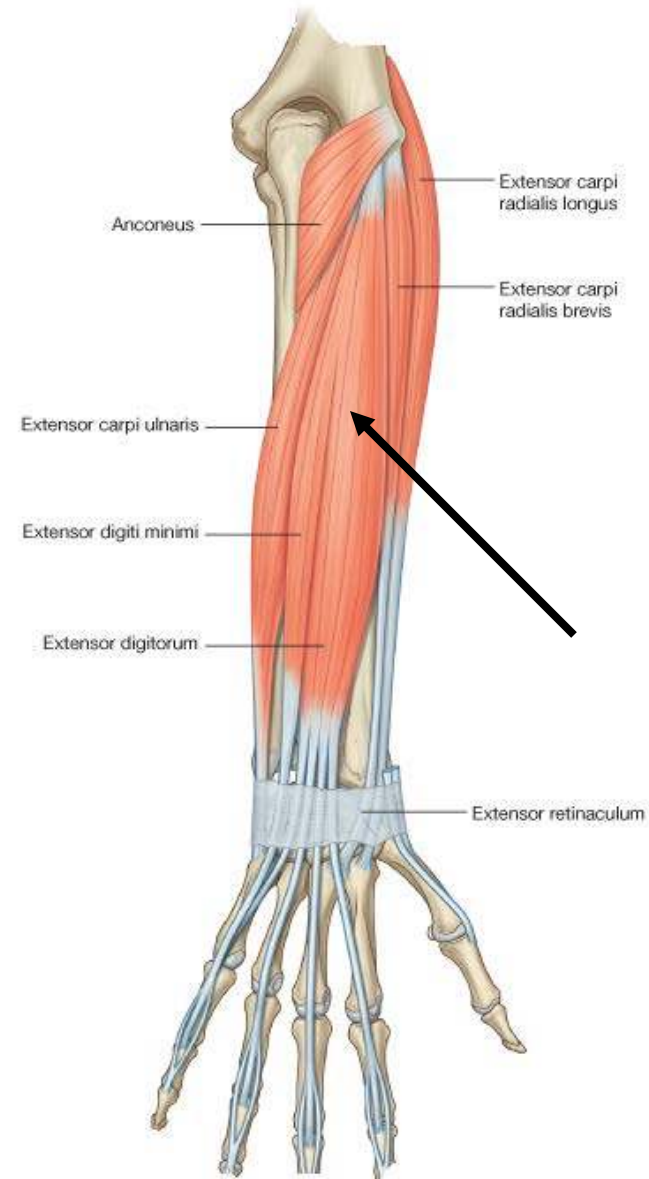
Muscles of the posterior compartment: Superficial Layer: Extensor Carpi Radialis Brevis

- O:** Lateral supraepicondylar ridge of humerus
- I:** Dorsal surface of base of metacarpal II & III
- A:** Extends and abducts the wrist
- N:** Radial nerve (Deep branch)



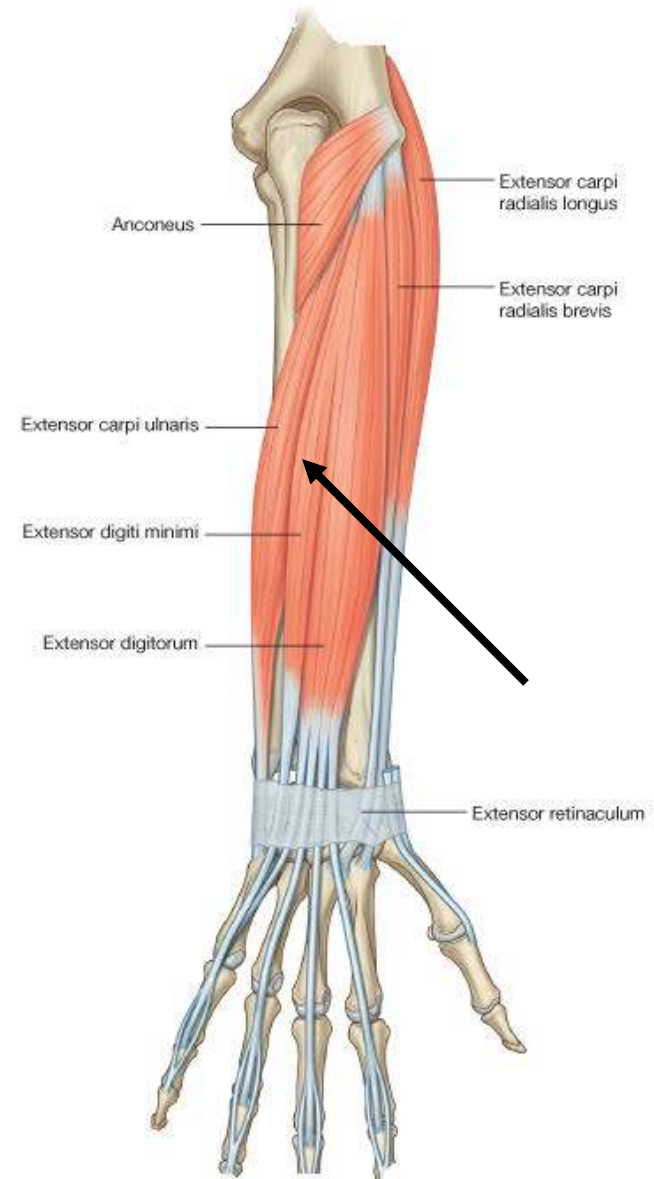
Muscles of the posterior compartment: Superficial Layer: Extensor Digitorum

- O**: Lateral supraepicondylar ridge of humerus
- I**: Four tendons, which insert via 'extensor hoods' into the dorsal aspects of the bases of the middle and distal phalanges of the index, middle, ring, and little fingers
- A**: Extends the index, middle, ring, and little fingers and the wrist
- N**: Radial nerve (Posterior Interosseus branch)



Muscles of the posterior compartment: Superficial Layer: Extensor Digiti Minimi

- O:** Lateral supraepicondylar ridge of humerus
- I:** Dorsal hood of the little finger
- A:** Extends the little finger
- N:** Radial nerve (Posterior Interosseus branch)



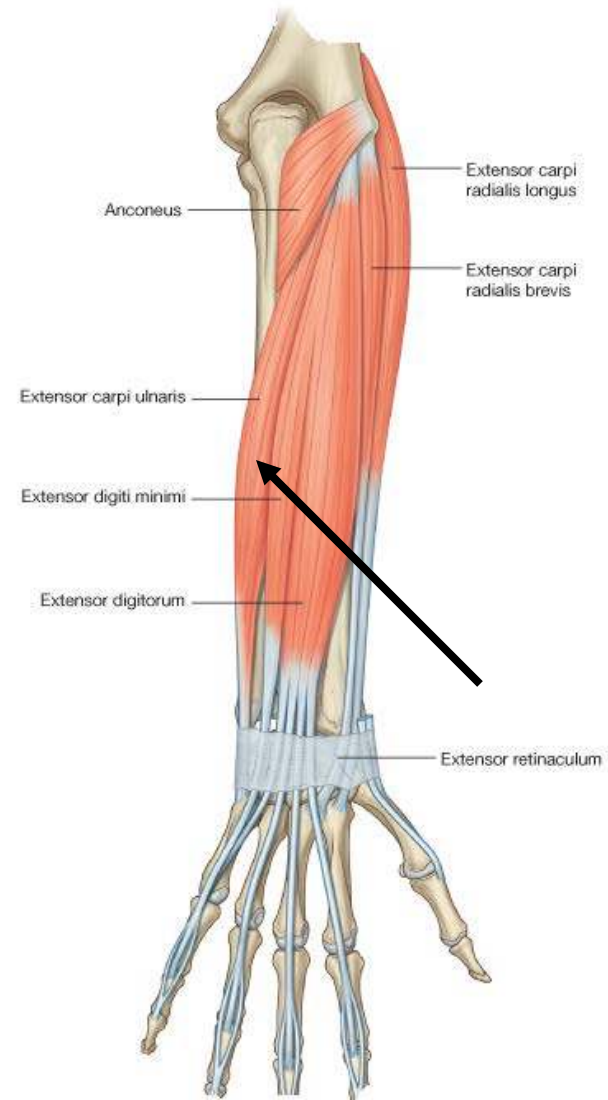
Muscles of the posterior compartment: Superficial Layer: Extensor Carpi Ulnaris

O: lateral supraepicondylar ridge of humerus

I: Tubercle on the base of the medial side of metacarpal V

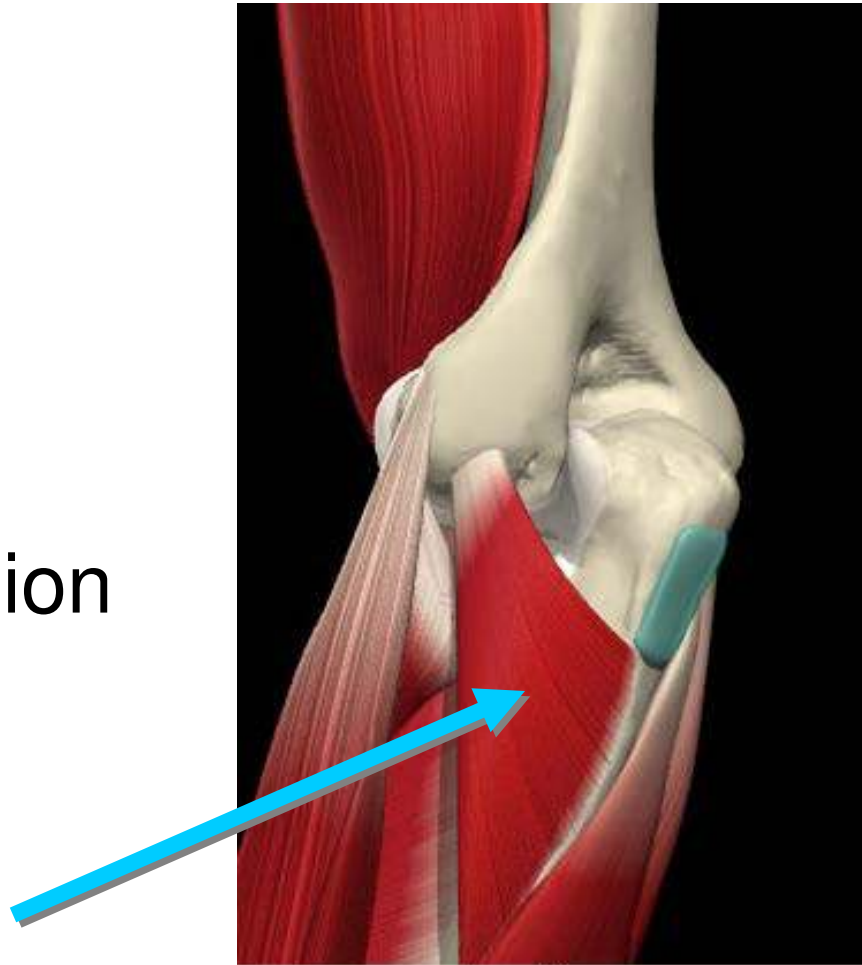
A: Extends and adducts the wrist

N: Radial nerve (Posterior Interosseus branch)



Muscles of the posterior compartment: Superficial Layer: Anconeus

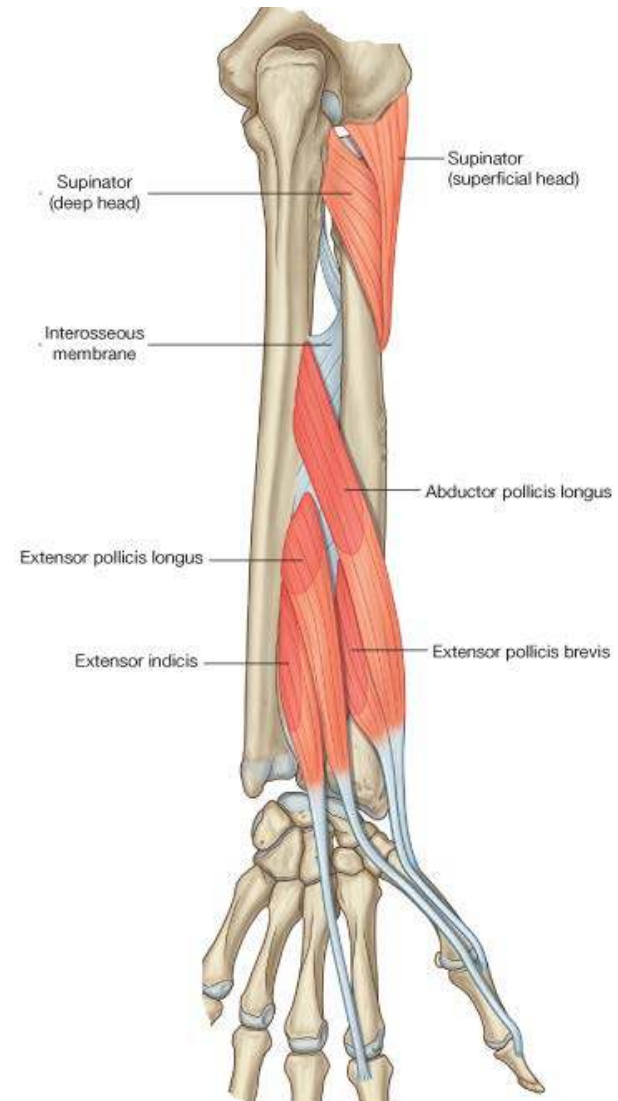
- **O**: Posterior humerus, lateral condyle
- **I**: Olecranon process
- **A**: Elbow extension
- **N**: Radial



Muscles of the posterior compartment: Deep Layer

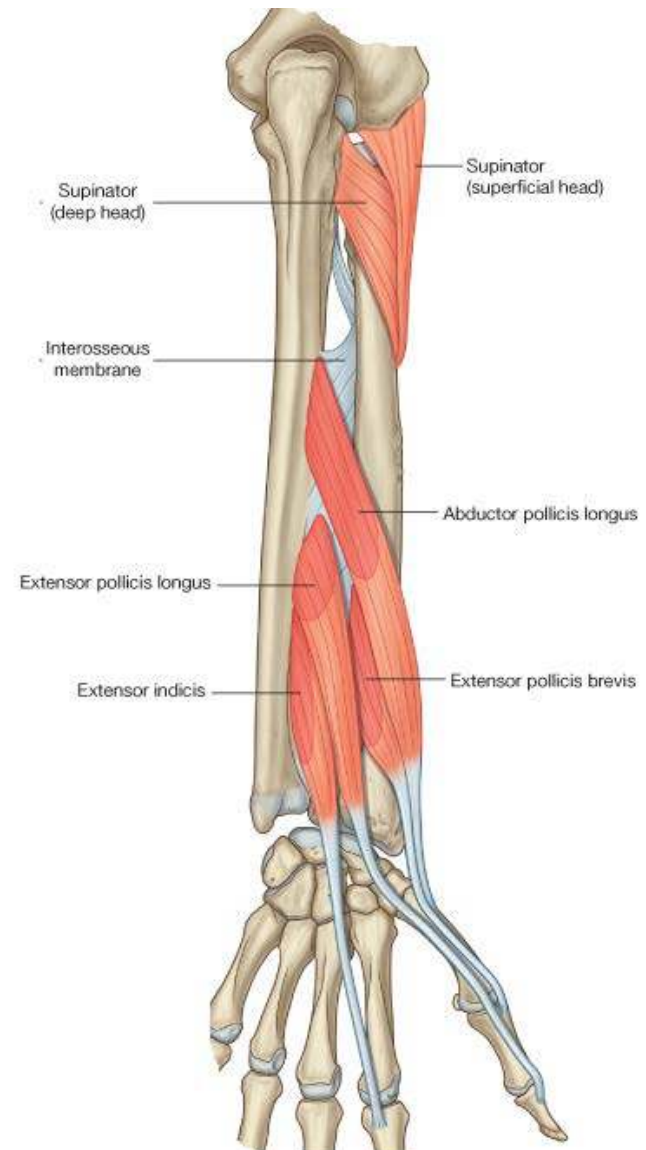
5 Muscles:

- i. Supinator
- ii. Abductor pollicis longus
- iii. Extensor pollicis brevis
- iv. Extensor pollicis longus
- v. Extensor indicis



Muscles of the posterior compartment: Deep Layer

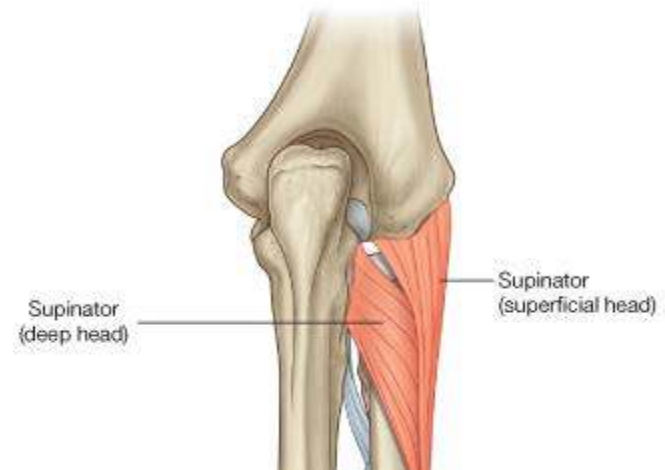
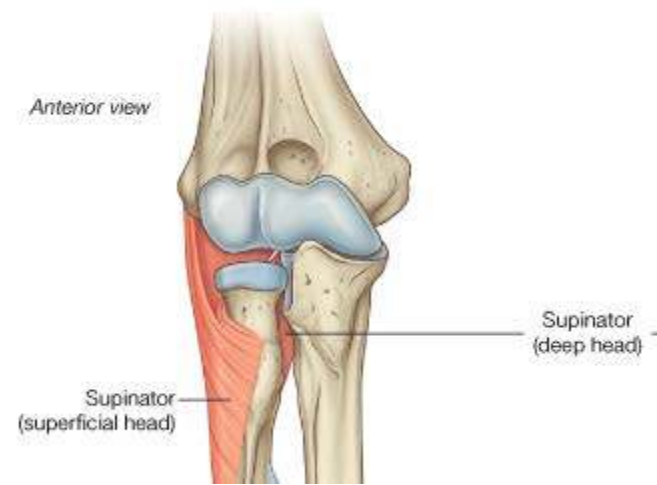
- All 5 are innervated by the posterior interosseous nerve, the continuation of the deep branch of the radial nerve
- Except for the supinator muscle, they all originate from the posterior surfaces of the radius, ulna, and interosseous membrane and pass into the thumb and index finger



Muscles of the posterior compartment:

Deep Layer: Supinator

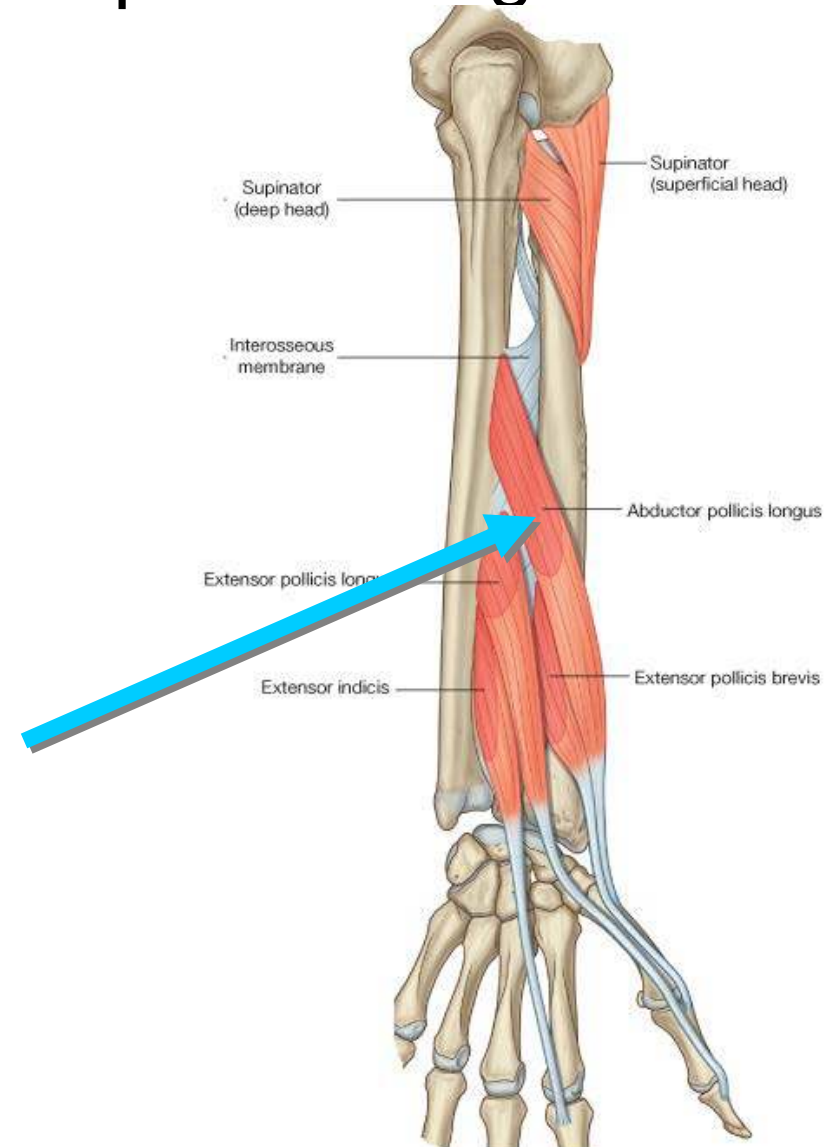
- **O: Superficial Head** from Lateral epicondyle of humerus
Deep head from supinator crest of ulna
- **I:** Lateral proximal radius
- **A:** Supination
- **N:** Radial
- **NOTE:** The deep branch of radial nerve enters the posterior compartment by passing through the space between the two heads



Muscles of the posterior compartment:

Deep Layer: Abductor policis longus

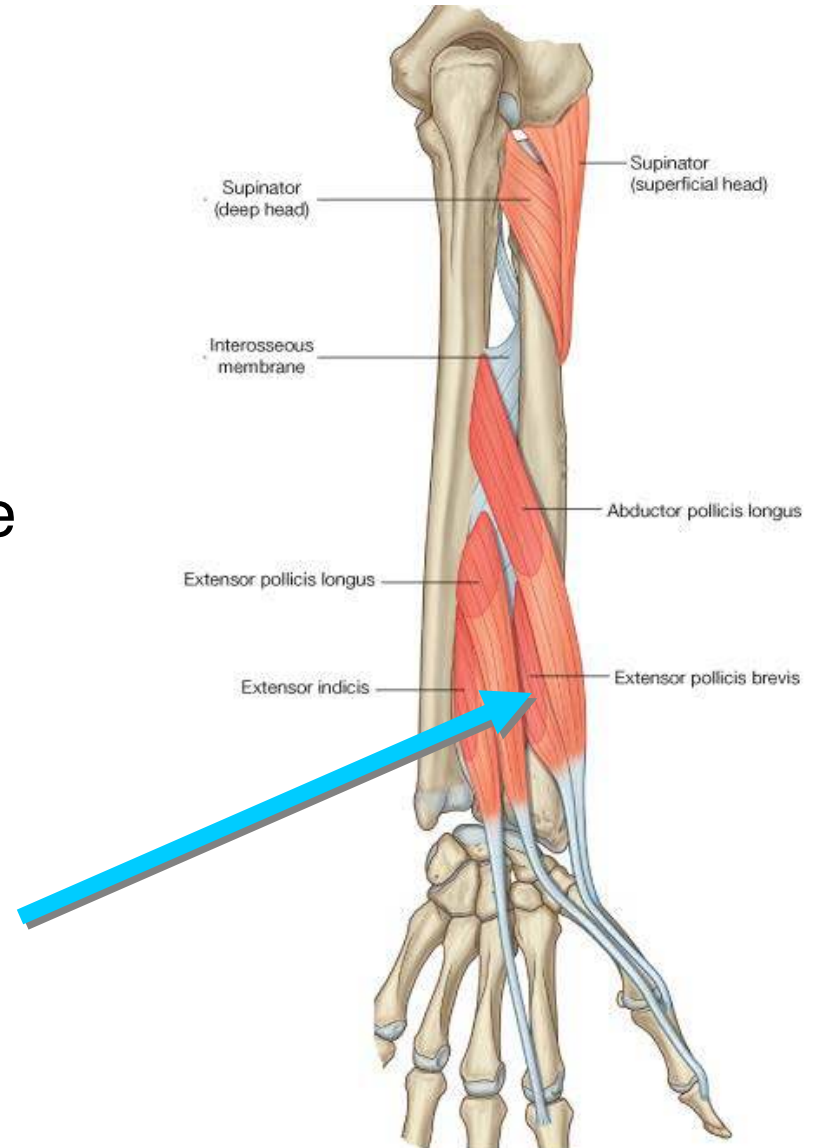
- **O**: Posterior surfaces of ulna and radius distal to the supinator and Anconeus
- **I**: Lateral side of base of first metacarpal
- **A**: Abducts carpometacarpal joint of thumb; accessory extensor of the thumb
- **N**: Posterior interosseous nerve
- **Note**: tendon contributes to the lateral border of the anatomical snuffbox at the wrist.



Muscles of the posterior compartment:

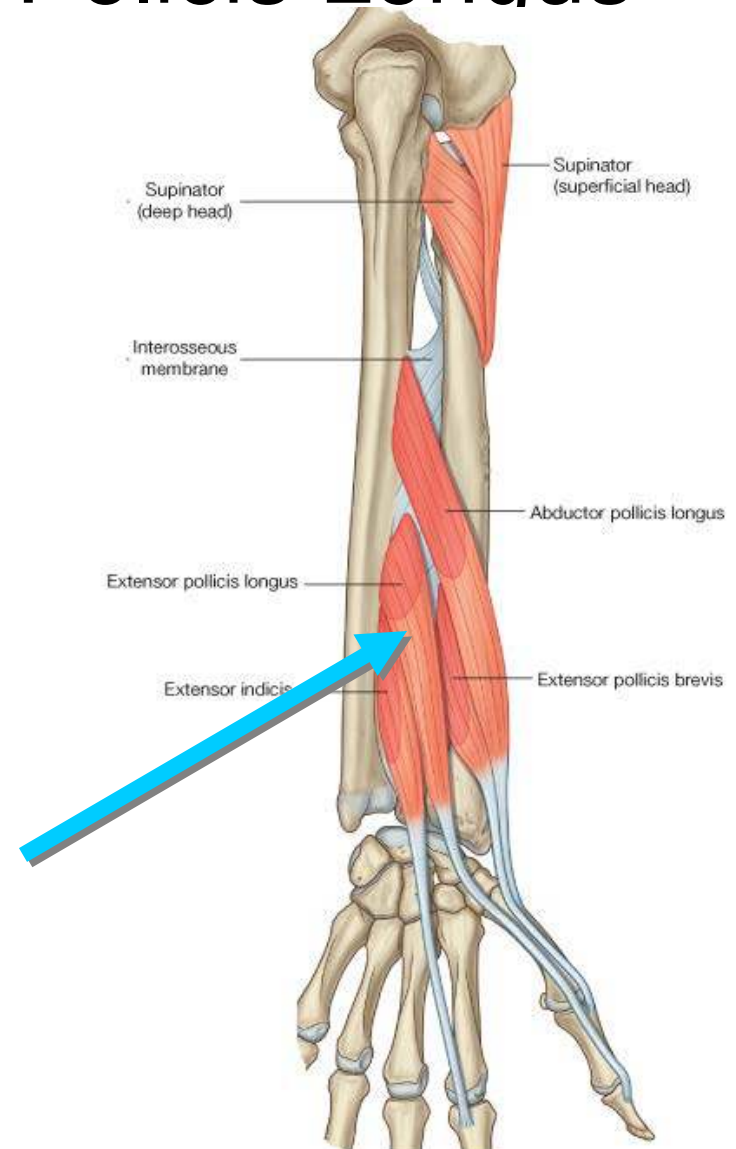
Deep Layer: Extensor Pollicis Brevis

- **O**: Posterior surfaces of radius distal to the Abductor Policis Longus
- **I**: Dorsal surface of base of proximal phalanx of the thumb
- **A**: Extends the metacarpophalangeal joint of the thumb; can also extend the carpometacarpal joint of the thumb
- **N**: Posterior interosseous nerve
- **Note**: tendon contributes to the lateral border of the anatomical snuffbox at the wrist.



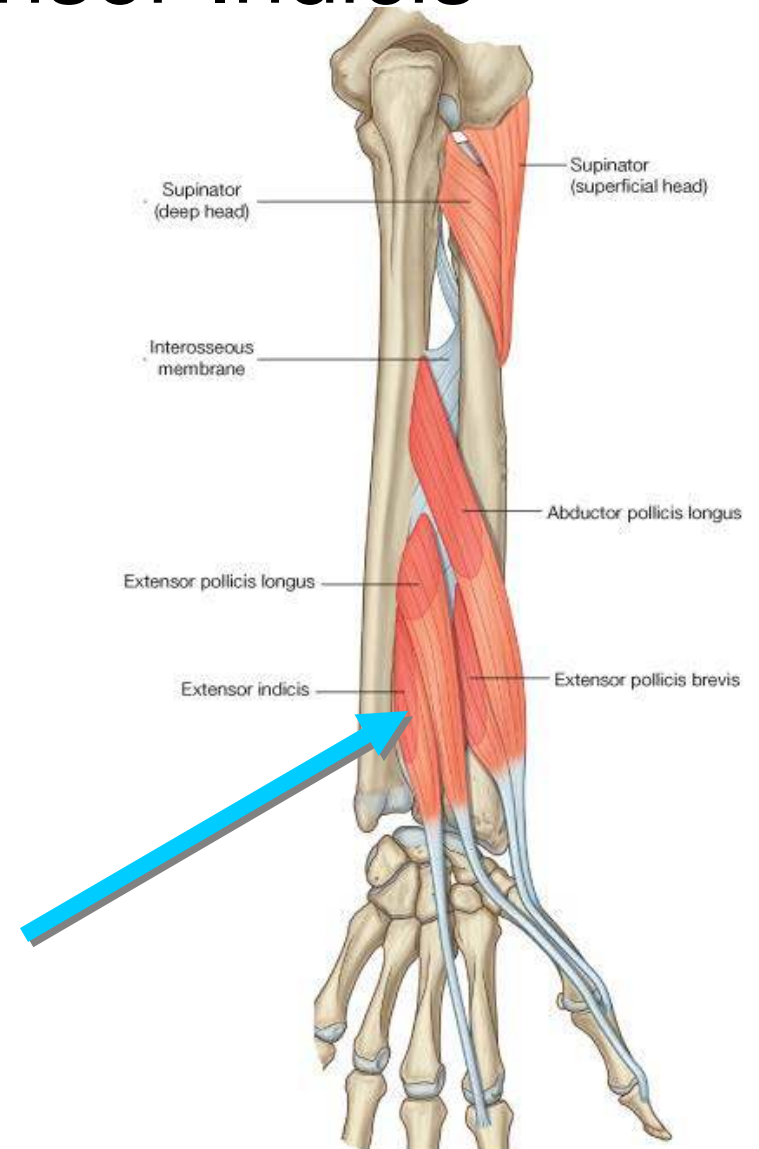
Muscles of the posterior compartment: Deep Layer: Extensor Pollicis Longus

- **O**: Posterior surfaces of ulna distal to the Abductor Pollicis Longus
- **I**: Dorsal surface of base of distal phalanx of the thumb
- **A**: Extends all joints of the thumb
- **N**: Posterior interosseous nerve
- **Note**: tendon forms the medial border of the anatomical snuffbox at the wrist.

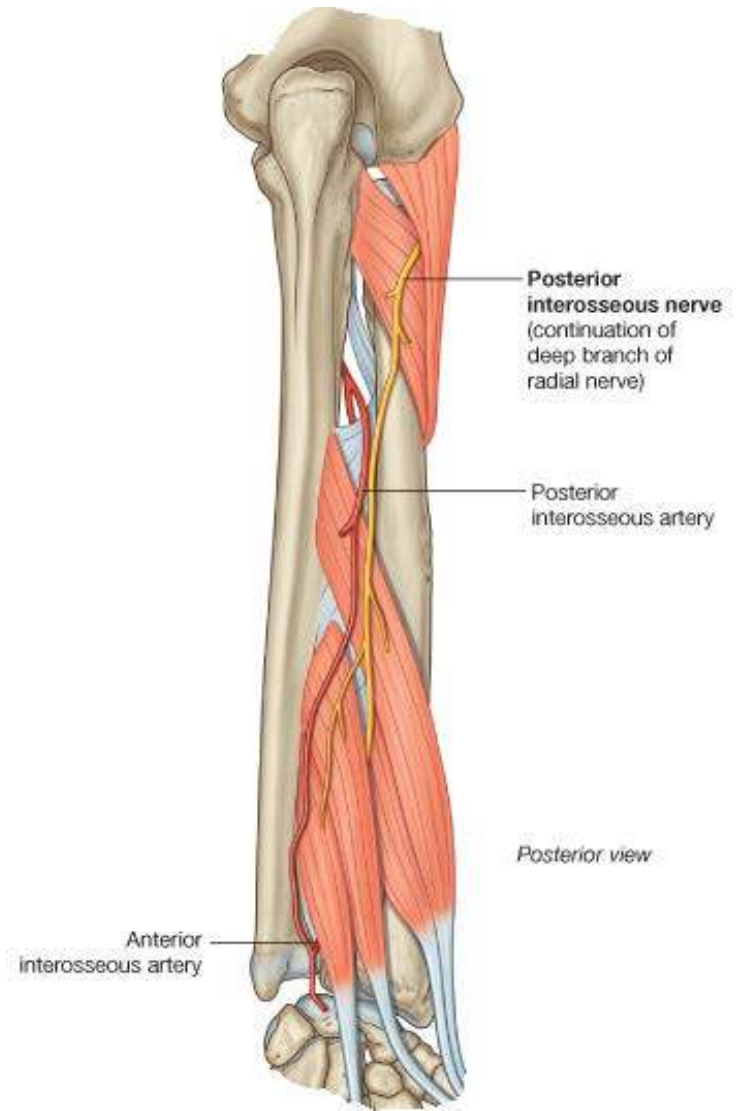
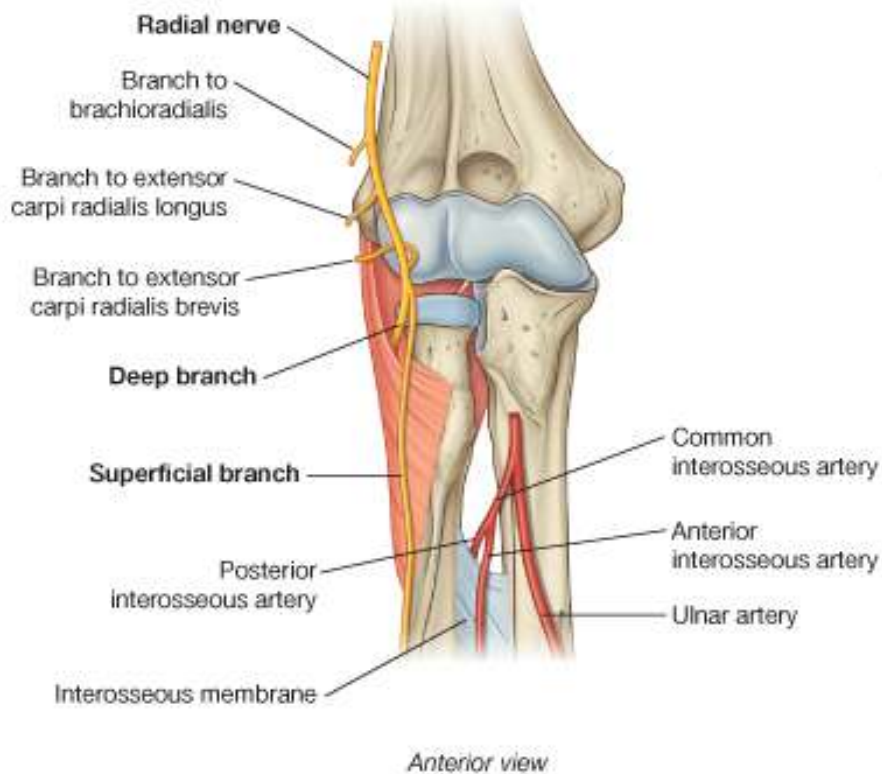


Muscles of the posterior compartment: Deep Layer: Extensor Indicis

- **O**: Posterior surfaces of ulna distal to the Extensor Policis Longus
- **I**: Extensor hood of index finger
- **A**: Extends the index finger
- **N**: Posterior interosseous nerve



Posterior Compartment Nerve and Blood supply



Any Question?

PLEASE JOIN THE FORUM AT WWW.OLUWADIYA.COM TO ASK QUESTIONS

