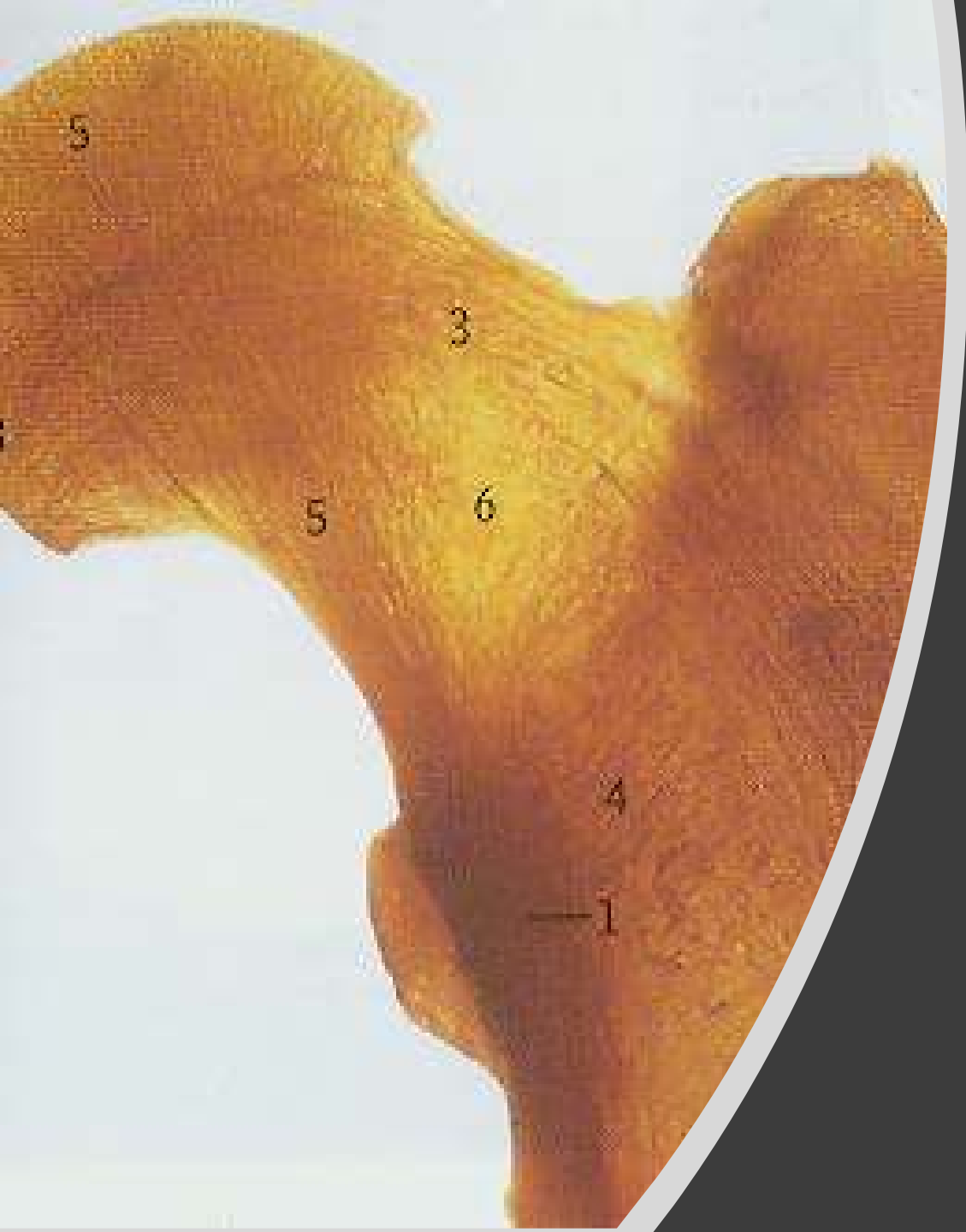

Bones of the lower limb

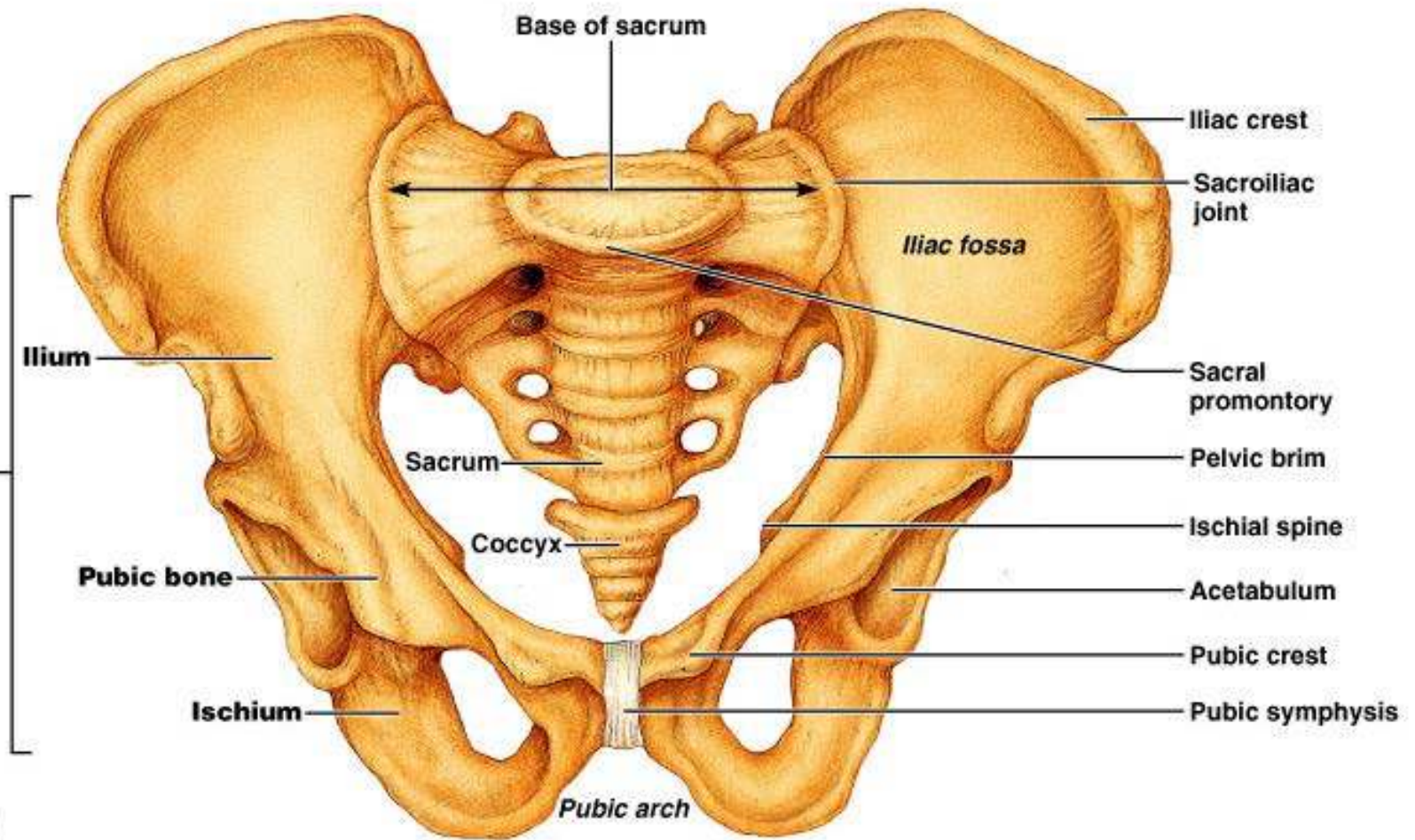
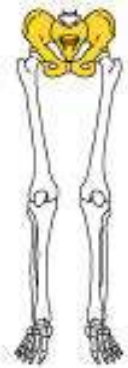
Prof. Oluwadiya Kehinde
www.oluwadiya.com

The pelvic girdle

Introduction

- Formed by the two os coxae (hipbones)
- United anteriorly by the symphysis pubis and posteriorly to the sacrum and coccyx
- Supports the weight of the body
- Attaches lower limbs to the spine
- Also supports and protects the lower viscera organs

The pelvic girdle

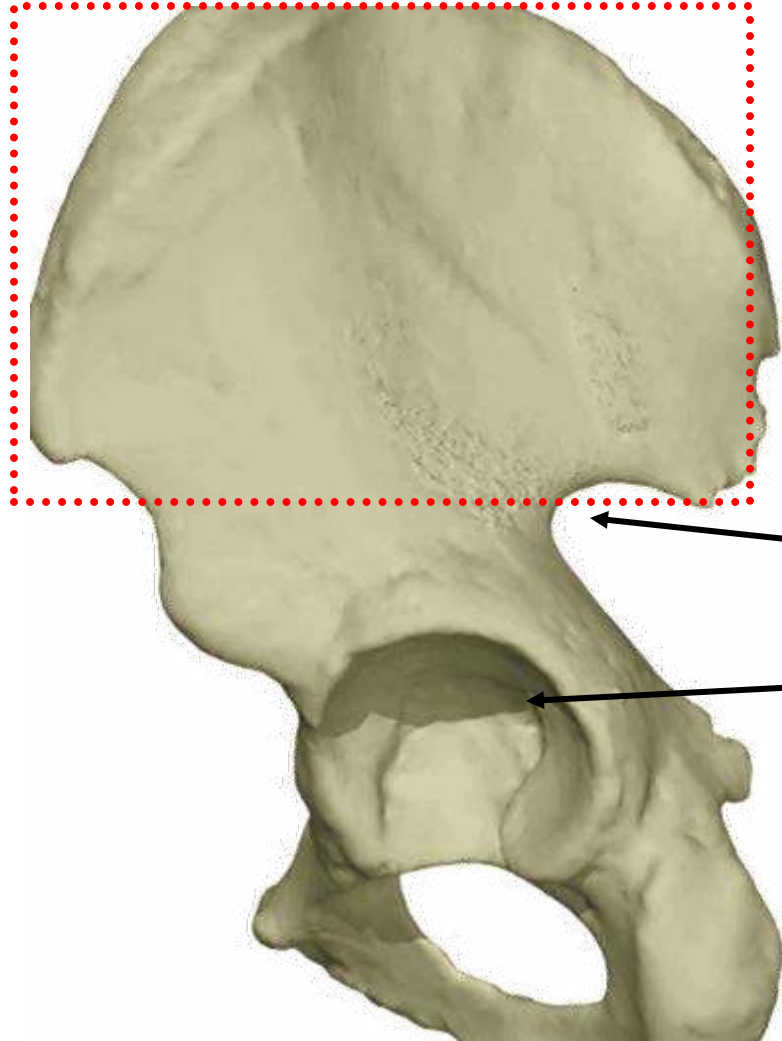


(a)

Each os coxa actually consists of three
separate bones:

- the ilium
- the ischium
- and the pubis

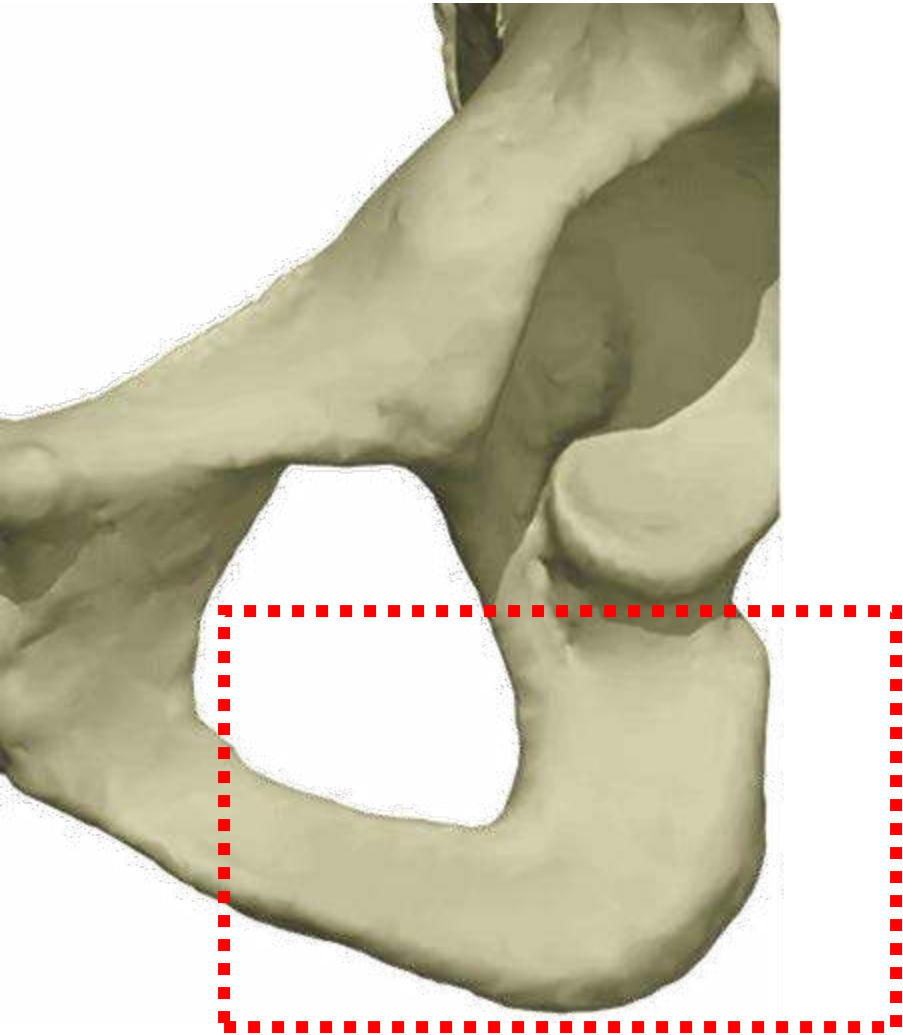
The ilium is the largest and uppermost of the three pelvic bones



Greater sciatic notch

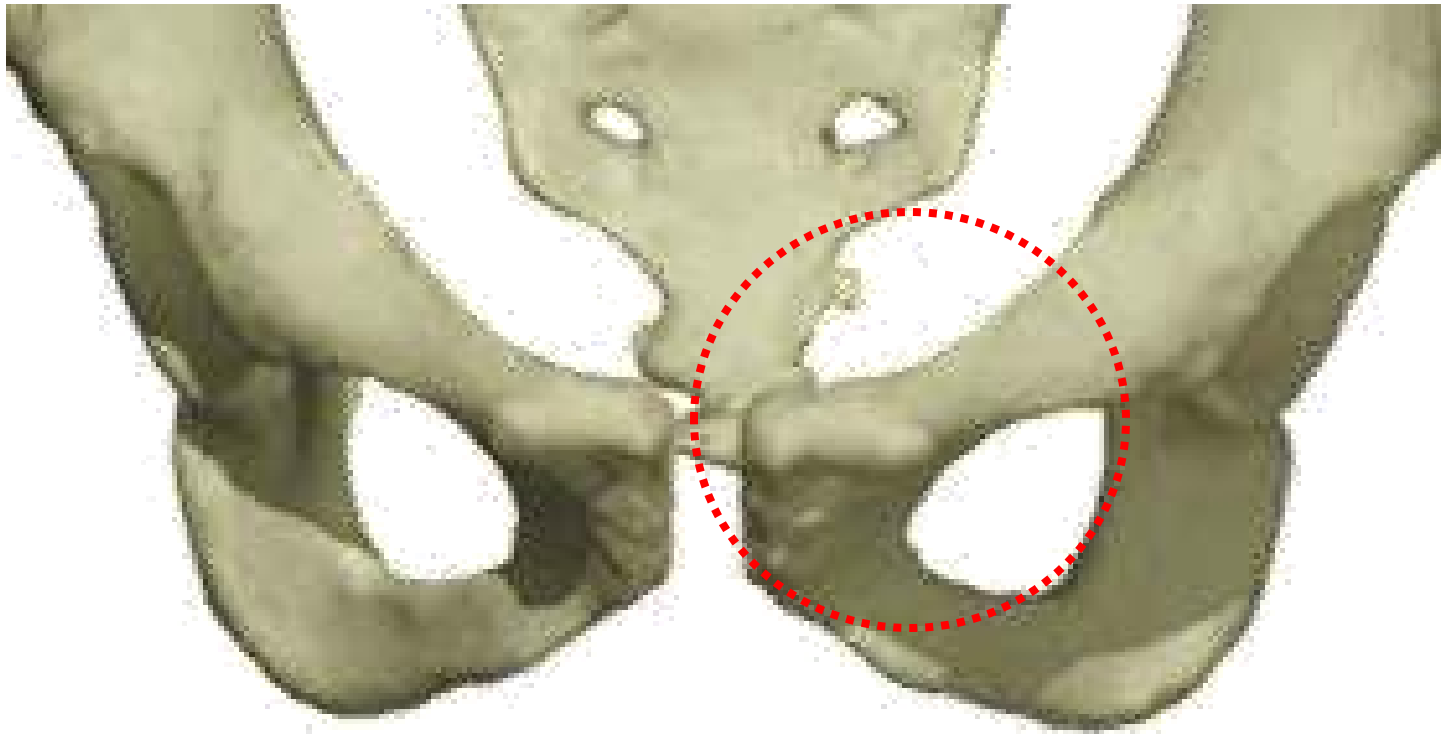
Acetabulum

The ischium is the posterior-inferior component of the os coax

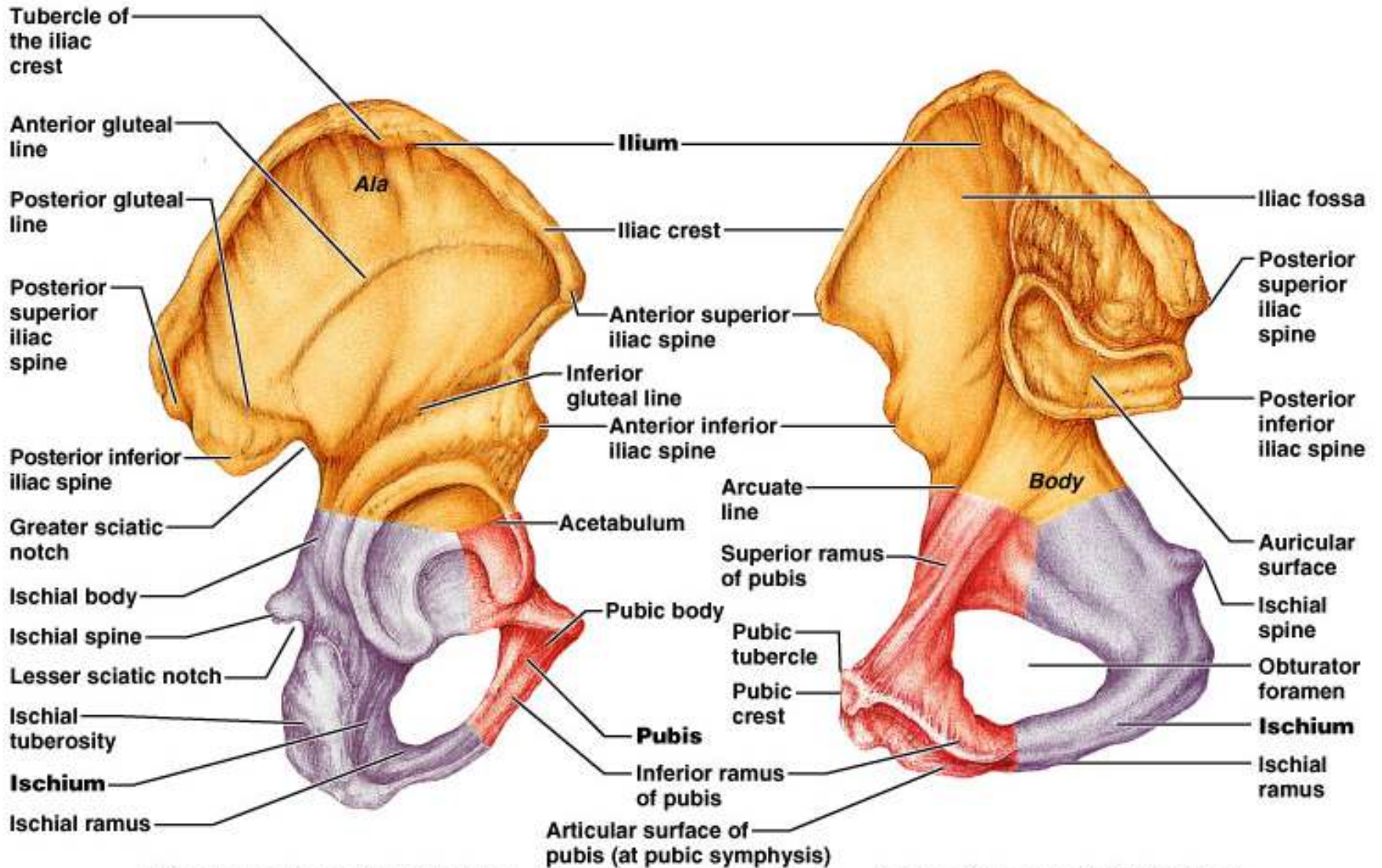


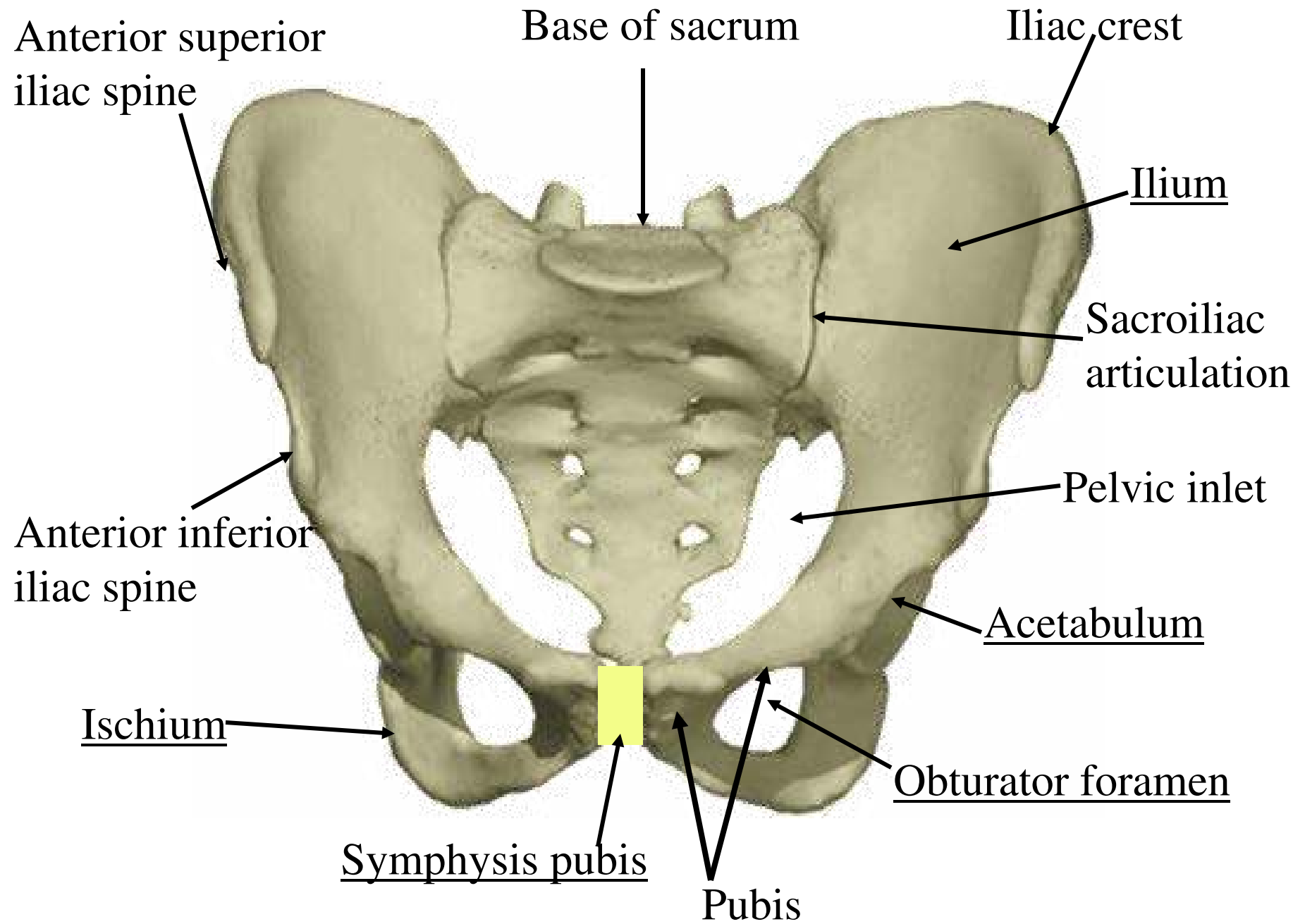
The ischial tuberosity is the bony projection that supports the weight of the body in the sitting position

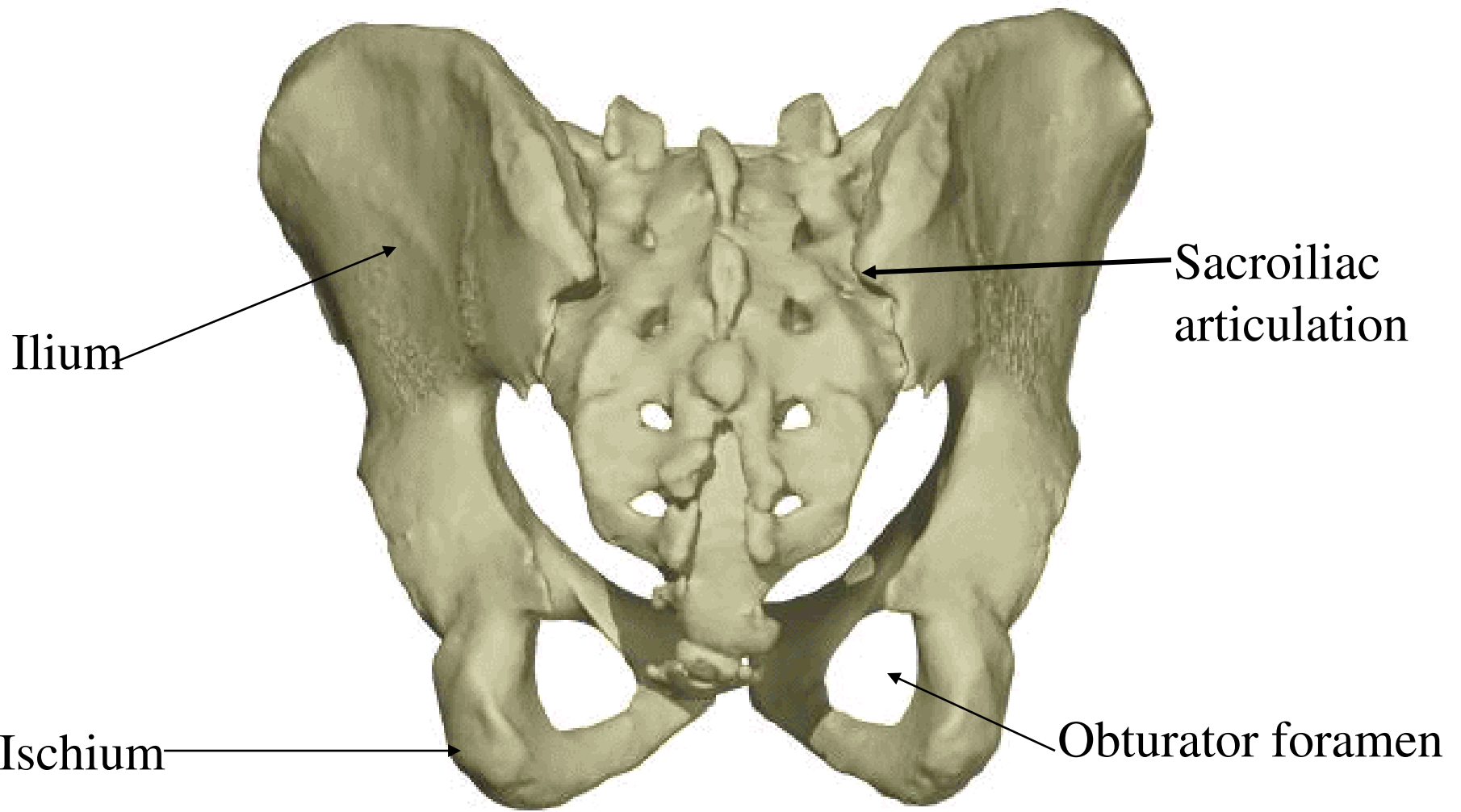
The pubis is the anterior component of the os coxa.



Parts of the pelvis



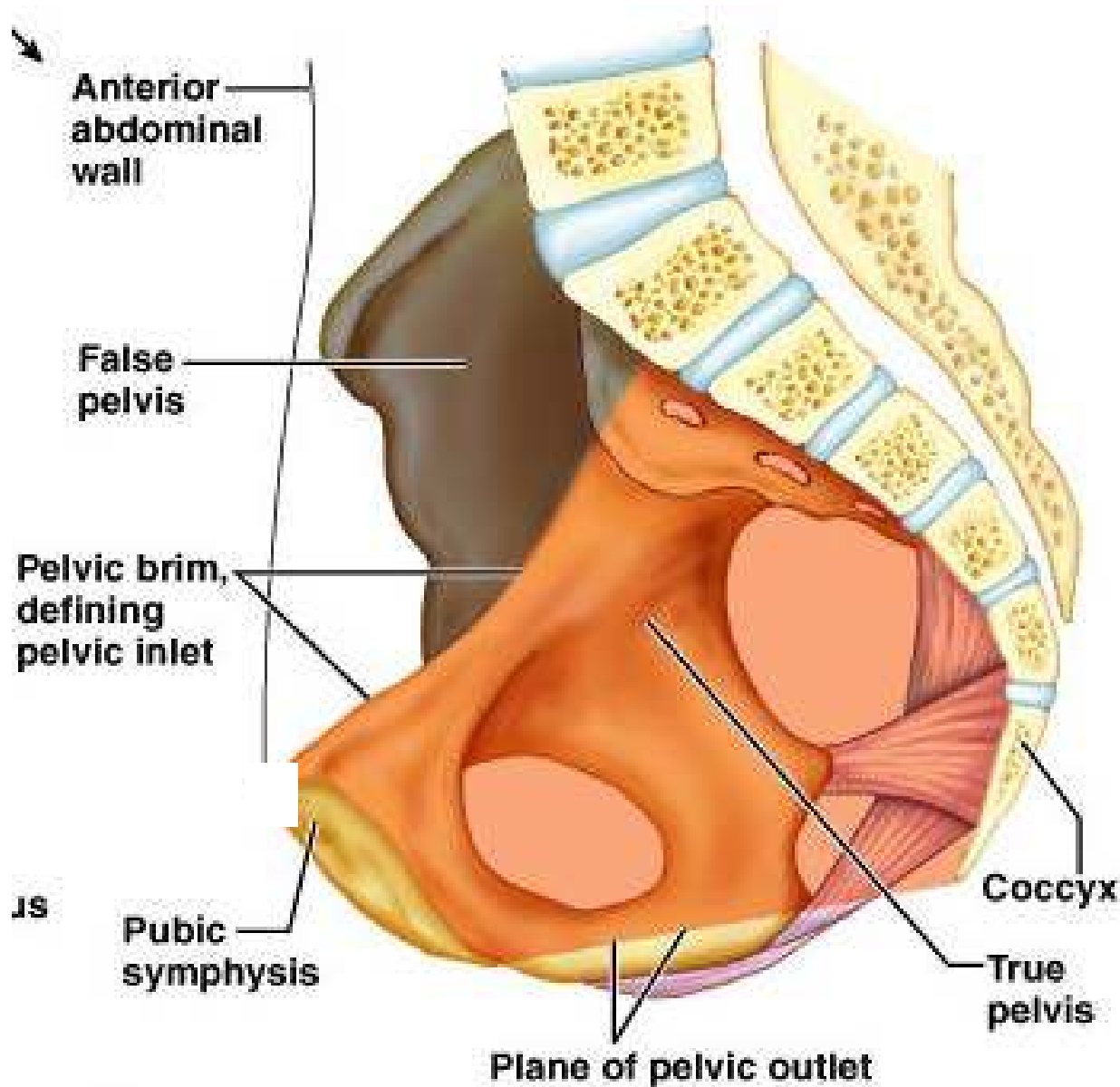




True and False Pelves

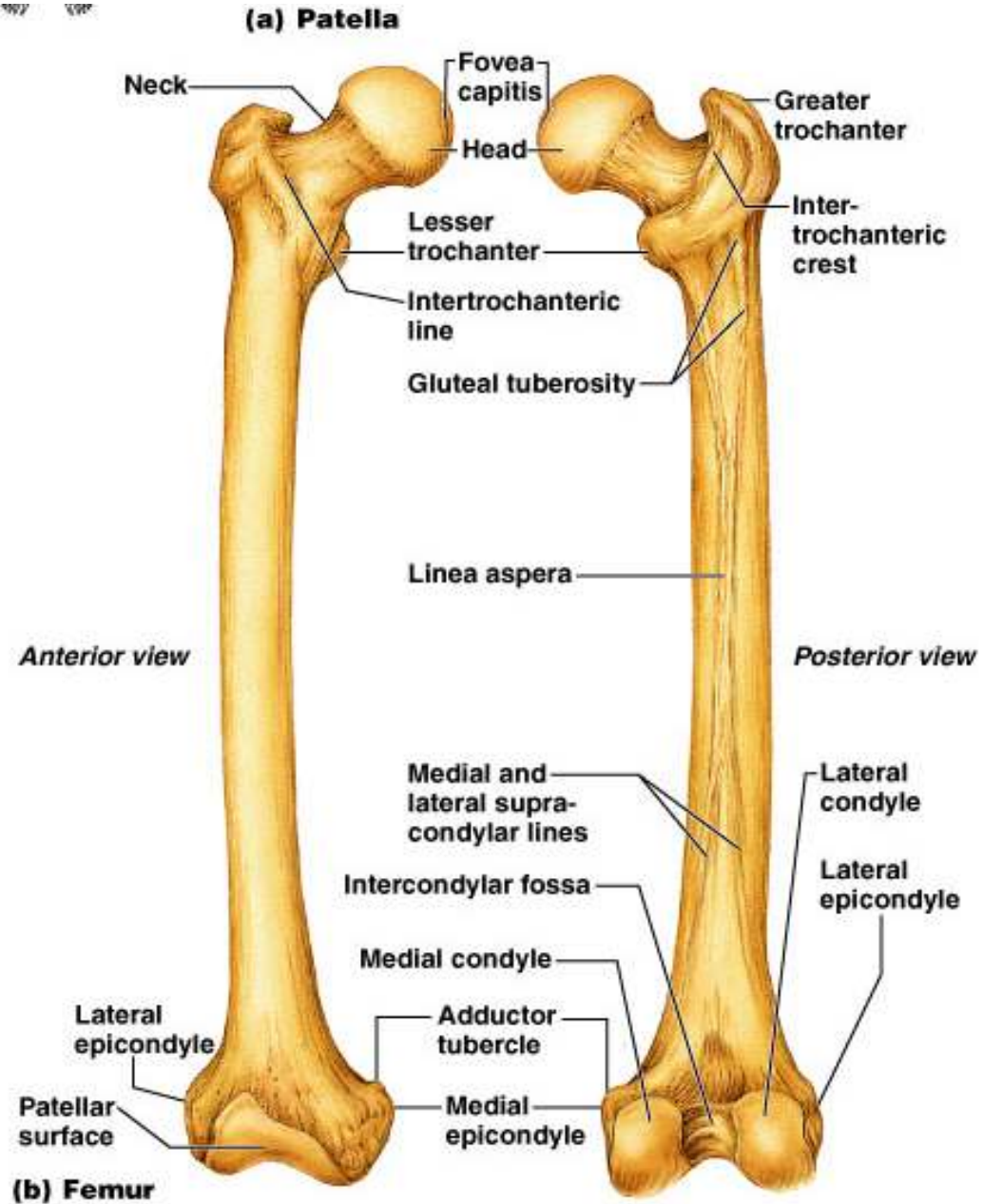
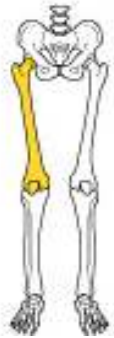- Bony pelvis is divided into two regions
 - False (greater) pelvis – bounded by the iliac bones
 - True (lesser) pelvis – inferior to pelvic brim
 - Forms a bowl containing the pelvic organs

True and False Pelvis



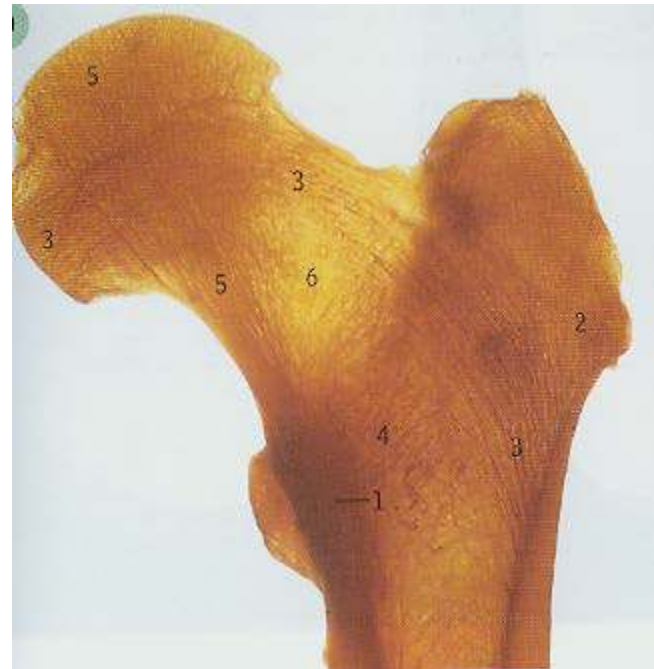(b)

Structures of the Femur

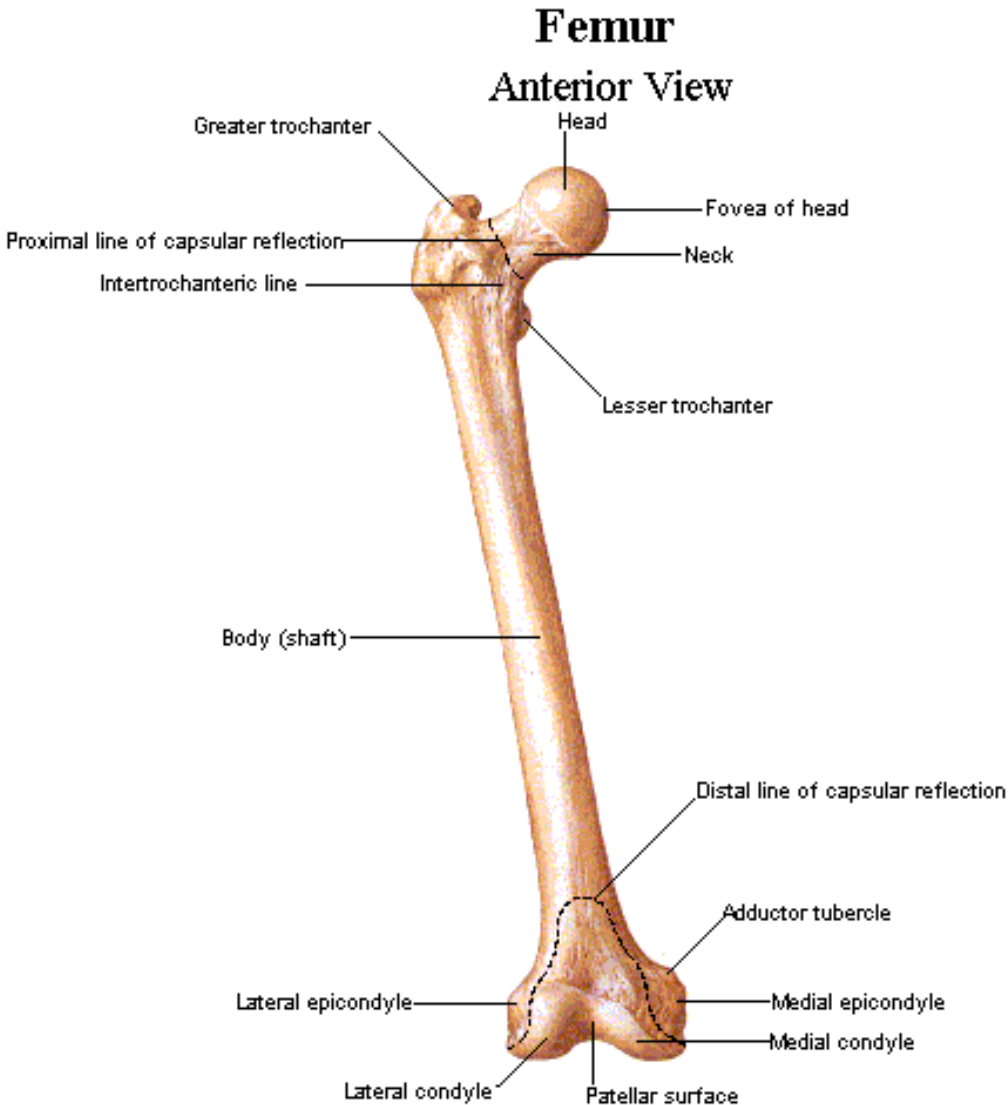


The femur

- Neck shaft angle 127 degrees
- Anteversion averages 14 degrees



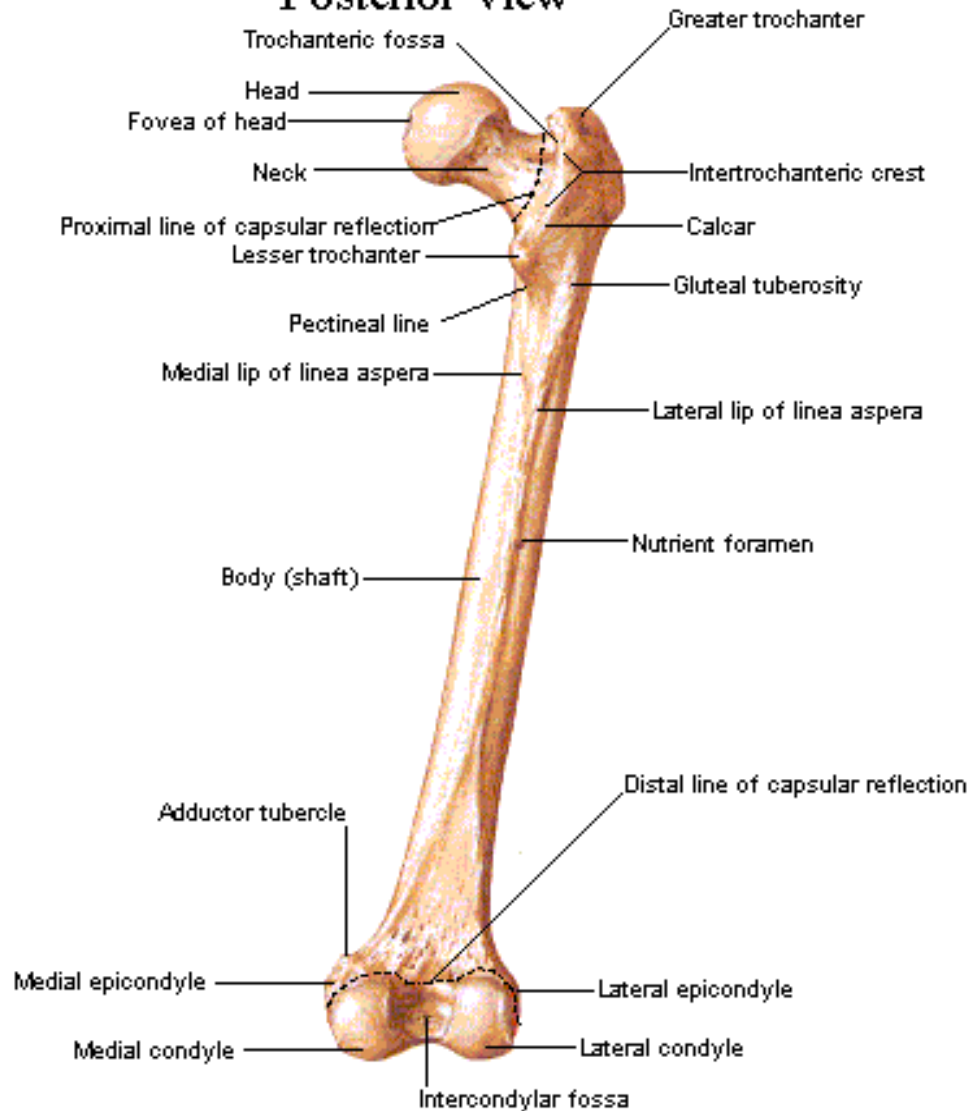
Structures of the Femur



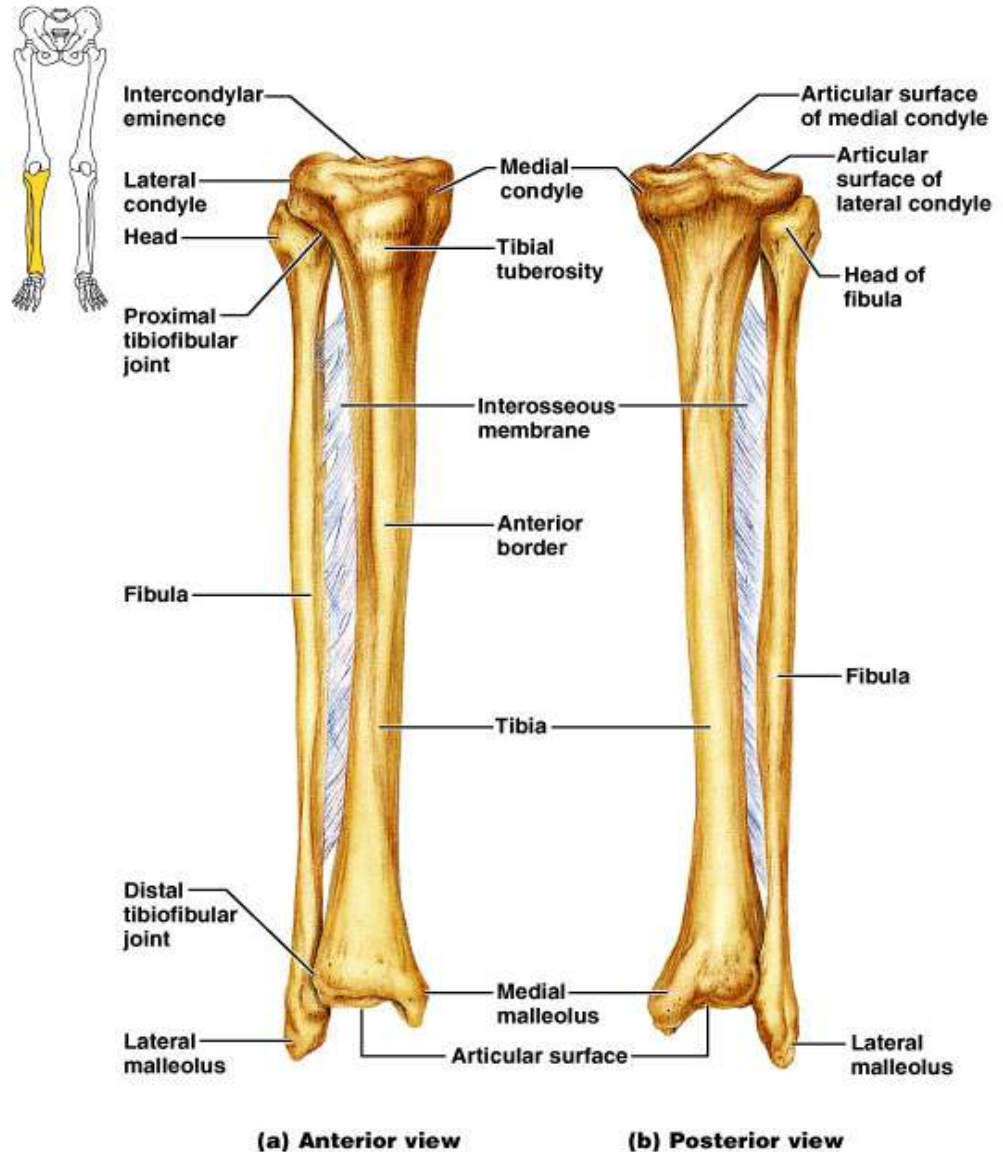
Structures of the Femur

Femur

Posterior View




Structures of the Tibia and Fibula



Patella

- sesamoid bone in quadriceps tendon
- 2 facets separated by a ridge
- Acts as a fulcrum, which aids in late extension of quads
- Protects knee joint
- Often multiple ossification centers
- Bipartite patella is a variant



Borders of the Tibia

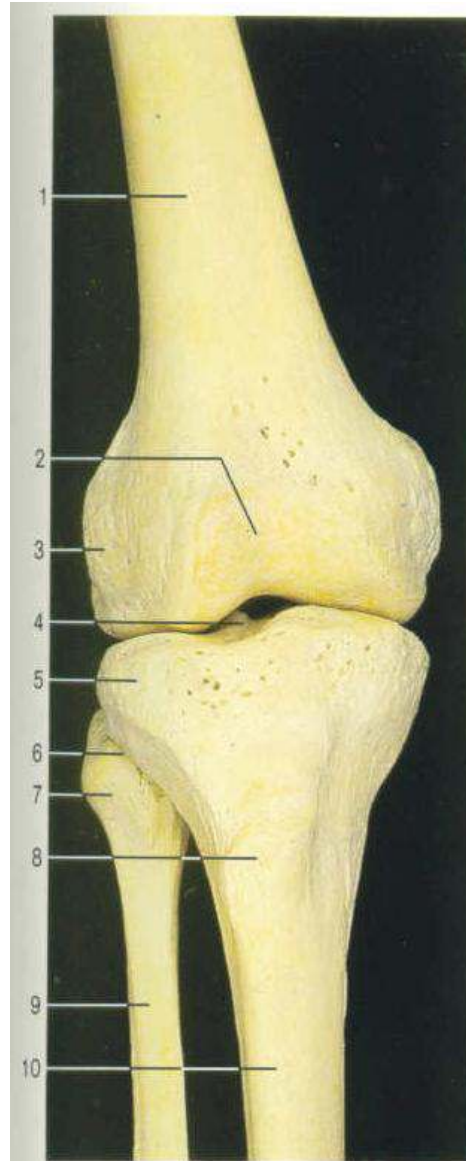
- the **anterior border** is sharp
- the **interosseous border** is a faint vertical ridge that descends along the lateral aspect of the tibia
- The **medial border** is indistinct superiorly, but is sharp in mid-shaft.

Borders of the Fibula

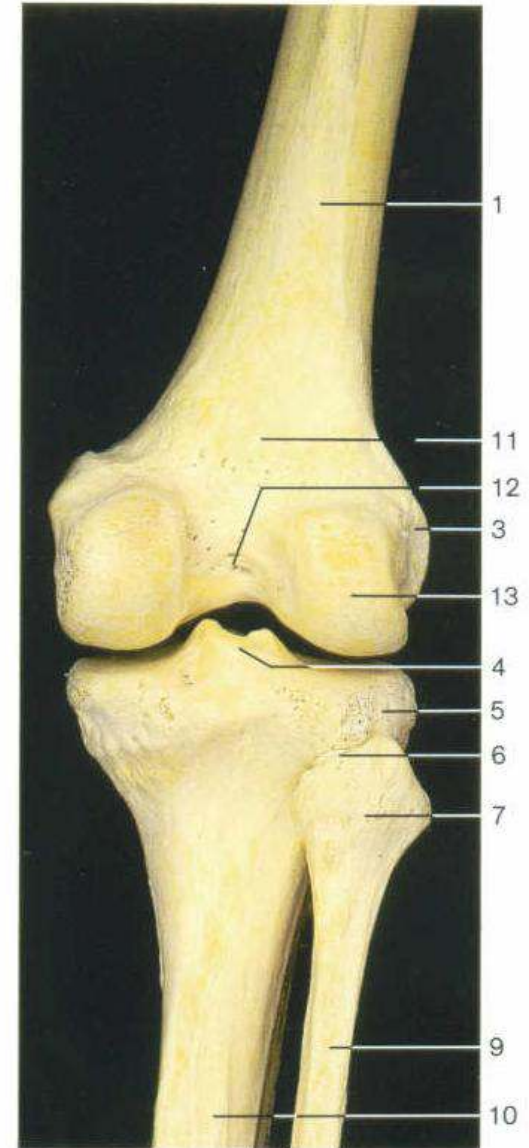
- the **anterior border** is sharp mid-shaft and begins superiorly from the anterior aspect of the head;
- the **posterior border** is rounded and descends from the region of the styloid process of the head;
- the **interosseous border** is medial in position.

Tibia & Fibula

- Tibia= 2nd largest bone in skeleton
- Medial & lateral plateaus
- Intercondylar tubercles
- Tibial condyles
- Tibial tuberosity
- Fibula is slightly posterior to tibia



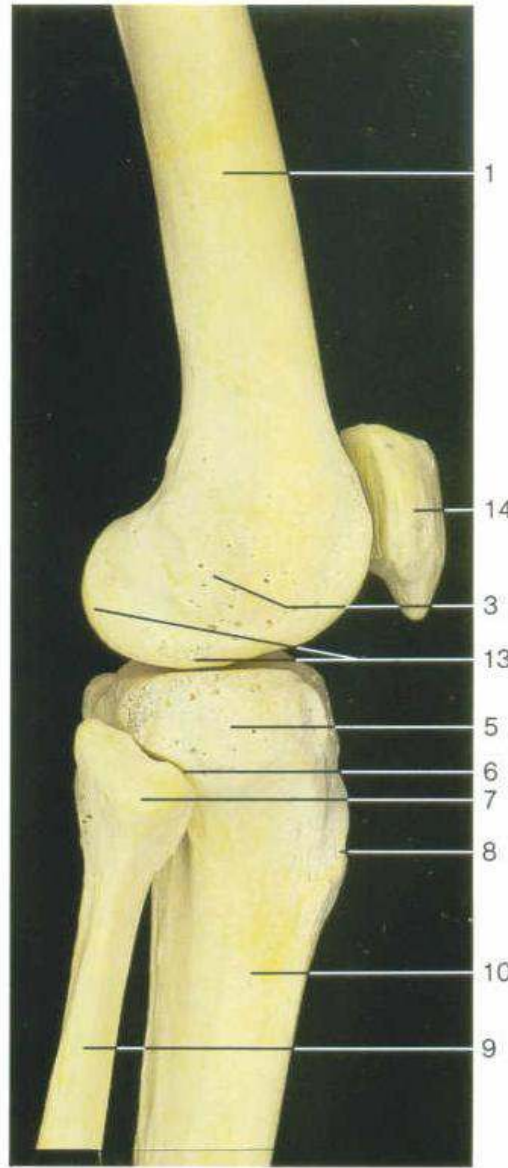
Bones of right knee joint
(anterior aspect).



Bones of right knee joint
(posterior aspect).

Tibia & Fibula

- Fibula is lateral and slightly posterior to tibia

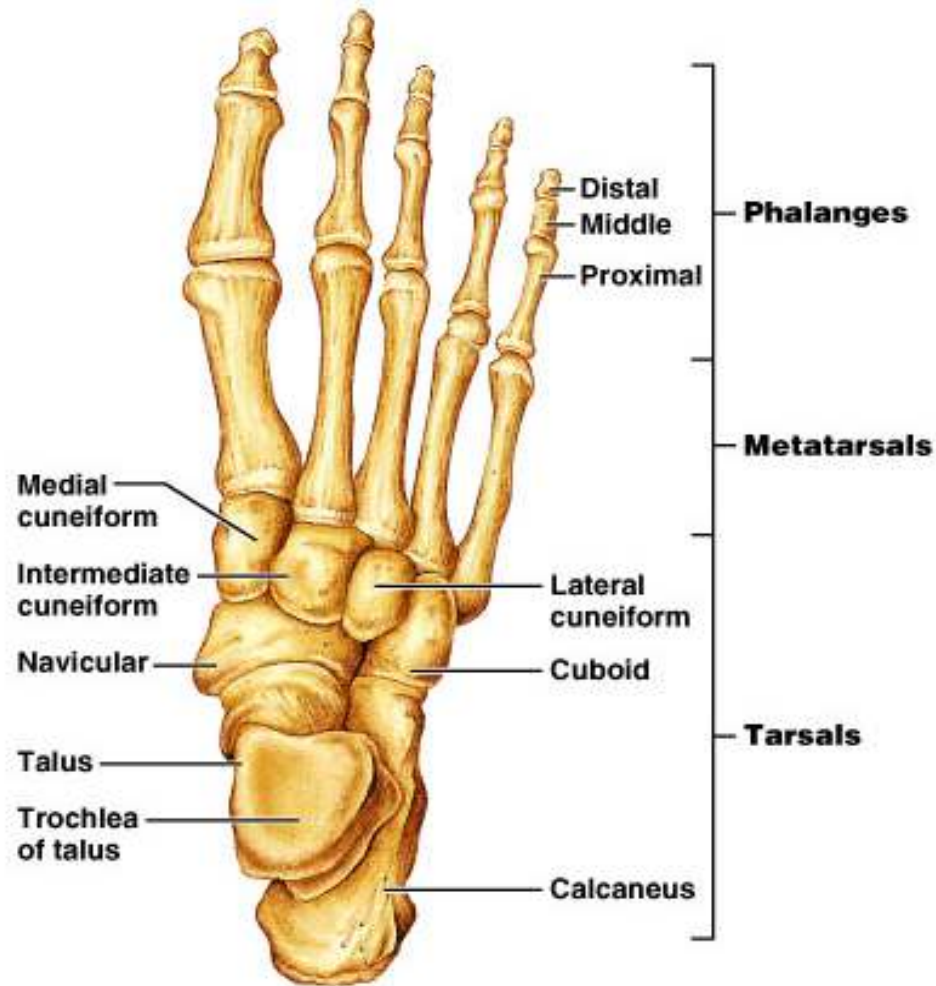


Bones of right knee joint
(lateral aspect).

The Foot

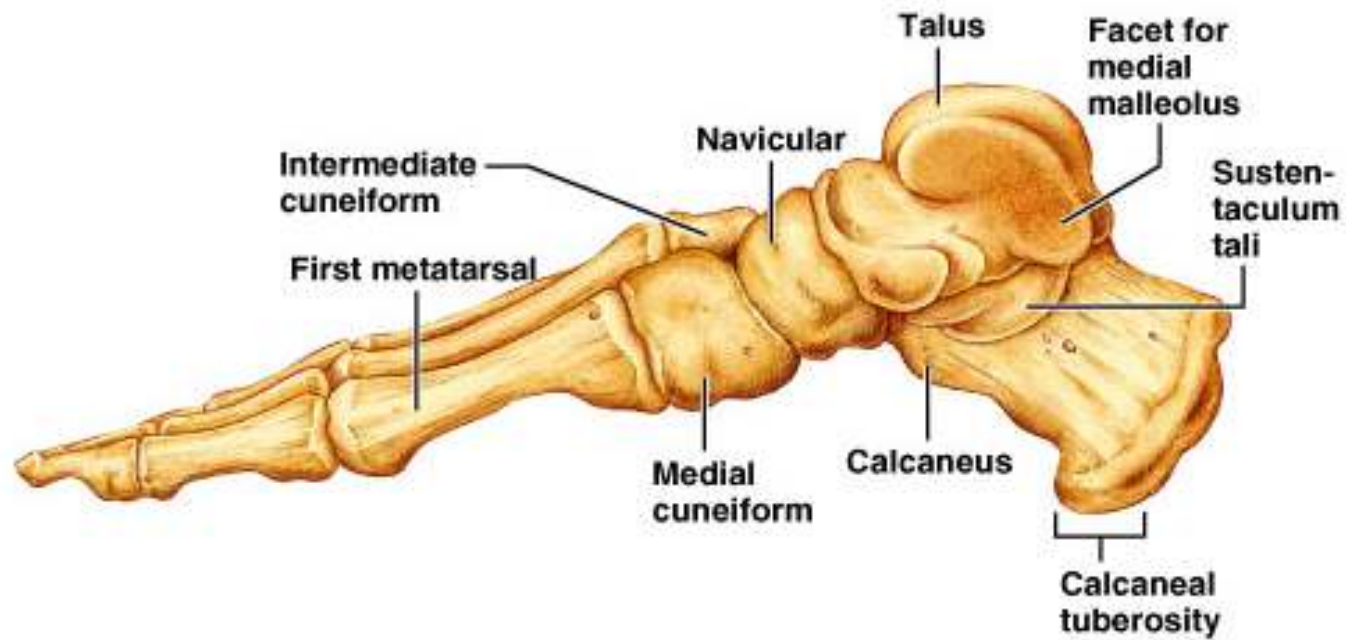
- Foot is composed of:
 - Tarsus, metatarsus, and the phalanges
- Important functions
 - Supports body weight
 - Acts as a lever to propel body forward when walking
 - Segmentation makes foot pliable and adapted to uneven ground

Bones of the Foot



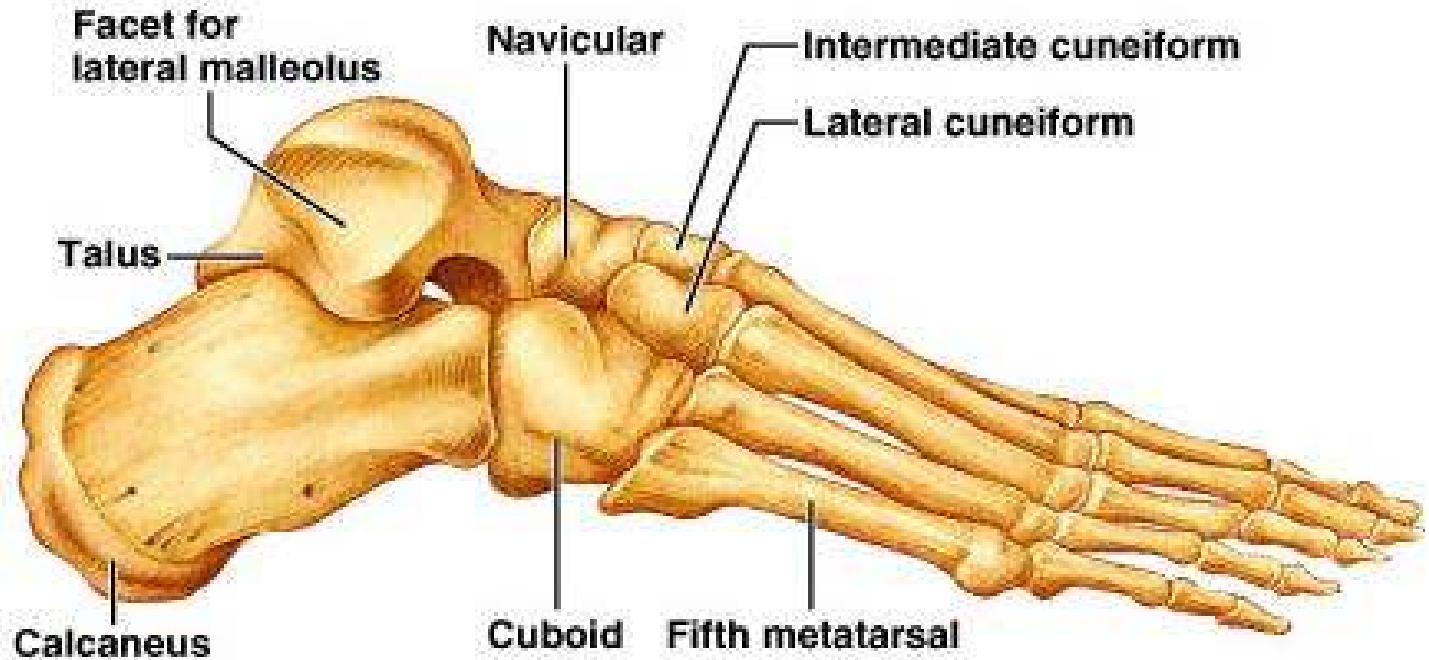
(a) Superior view

Bones of the Foot



(b) Medial view

Bones of the Foot

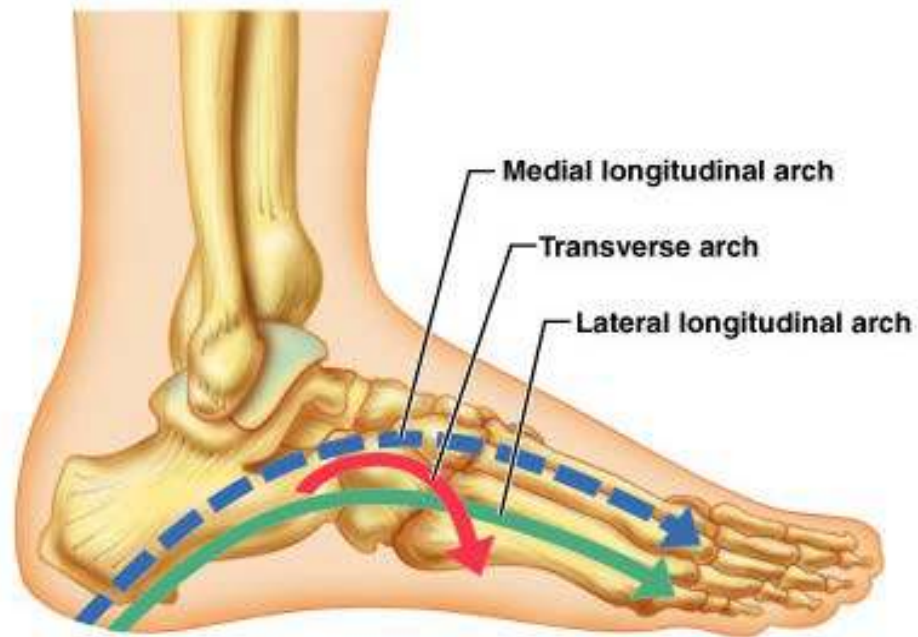


(c) Lateral view

Arches of the Foot

- Foot has three important arches
 - Medial and lateral longitudinal arch
 - Transverse arch
- Arches are maintained by:
 - Interlocking shapes of tarsals
 - Ligaments and tendons

Arches of the Foot



The End

- Please join the forum at www.oluwadiya.com to ask questions