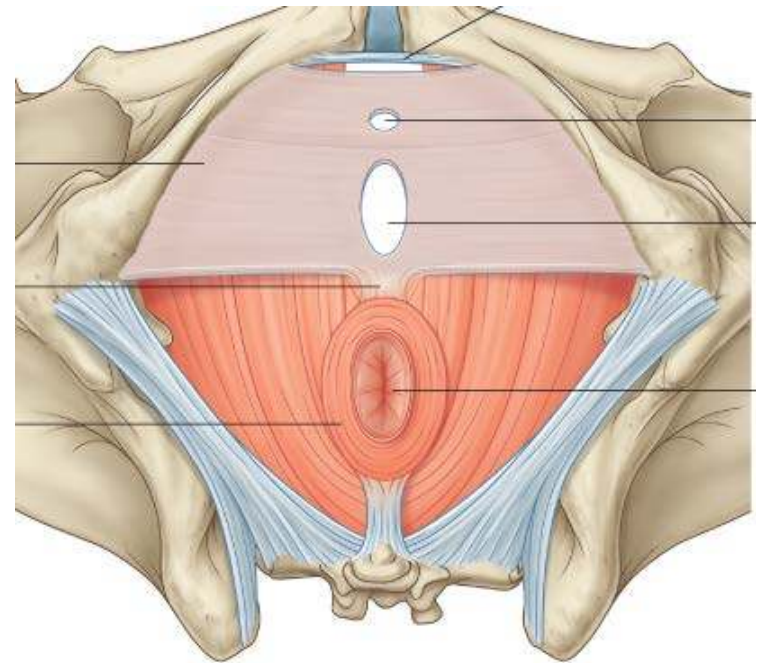


# THE PERINEUM

Dr Oluwadiya Kehinde  
[www.oluwadiya.com](http://www.oluwadiya.com)



Elsevier. Drake et al: Gray's Anatomy for Students - [www.studentconsult.cc](http://www.studentconsult.cc)

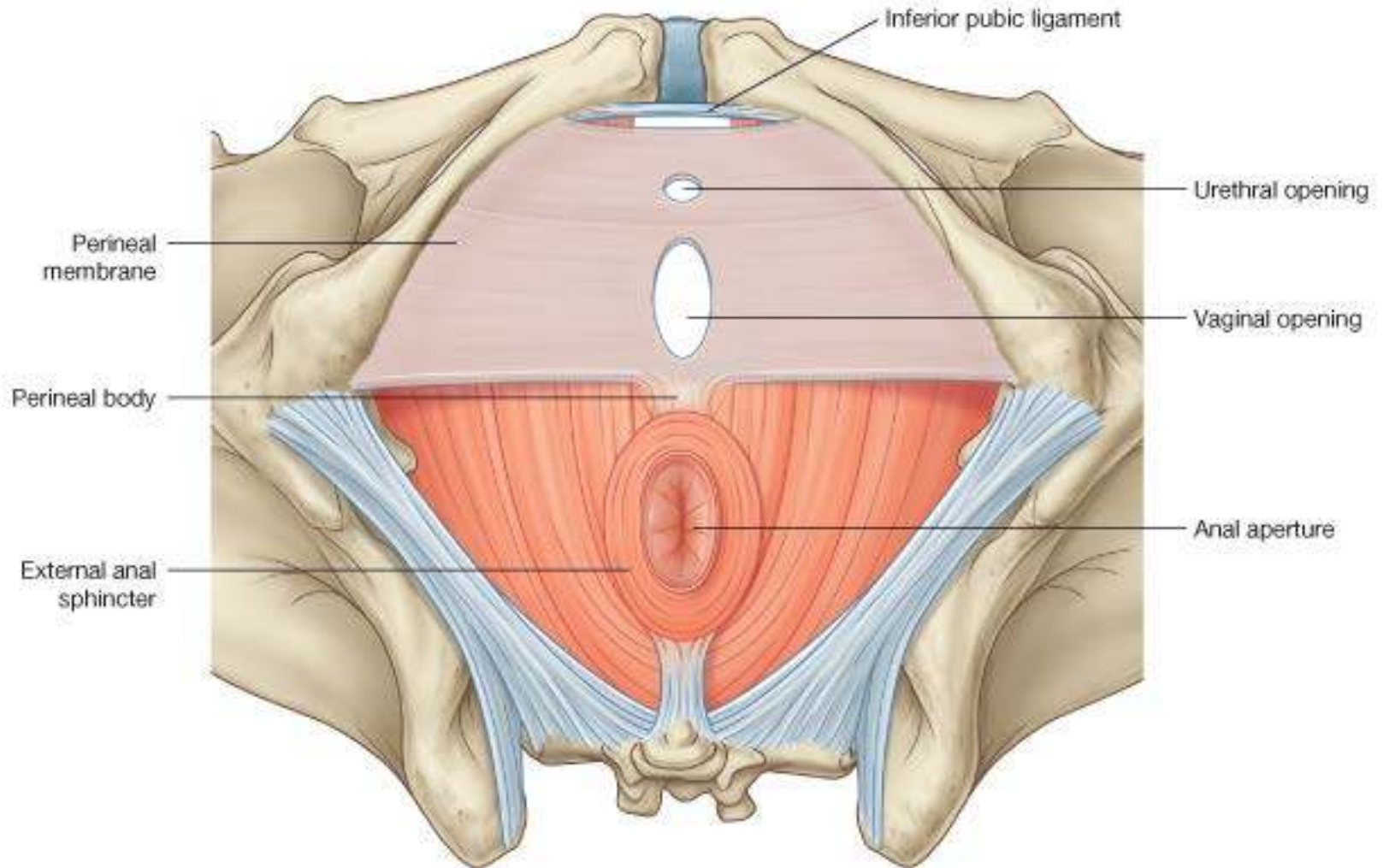
# Perineum

- Lies below the pelvic floor
- Refers to the surface of the trunk between the thighs and the buttocks, extending from the coccyx to the pubis
- Boundaries are:
  - Anteriorly: Pubic symphysis
  - Anterolaterally: Inferior pubic rami and ischial rami
  - Laterally: Ischial tuberosities
  - Posterolaterally: Sacrotuberous ligaments
  - Posteriorly: Inferior part of sacrum and coccyx

# Perineum

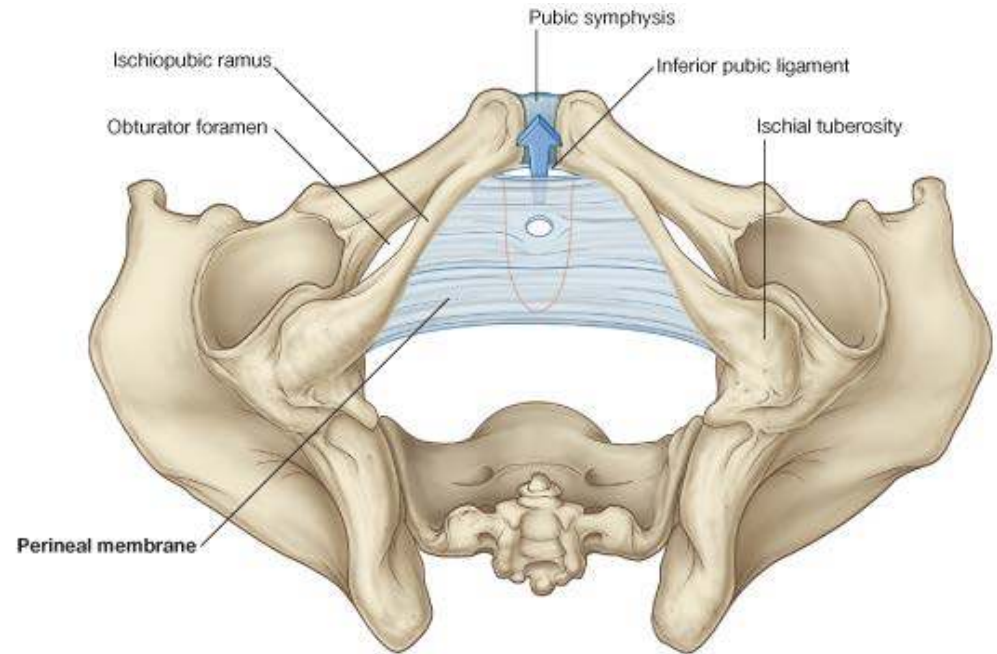
- Divided into two by an imaginary line between the ischial tuberosities into:
- **Urogenital triangle** contains the roots of the external genitalia and, in women, the openings of the urethra and the vagina. In men, the distal part of the urethra is enclosed by erectile tissues and opens at the end of the penis
- The **anal triangle** contains the anal aperture posteriorly.
- The midpoint of the line joining the ischial tuberosities is the central point of the perineum

# Perineum



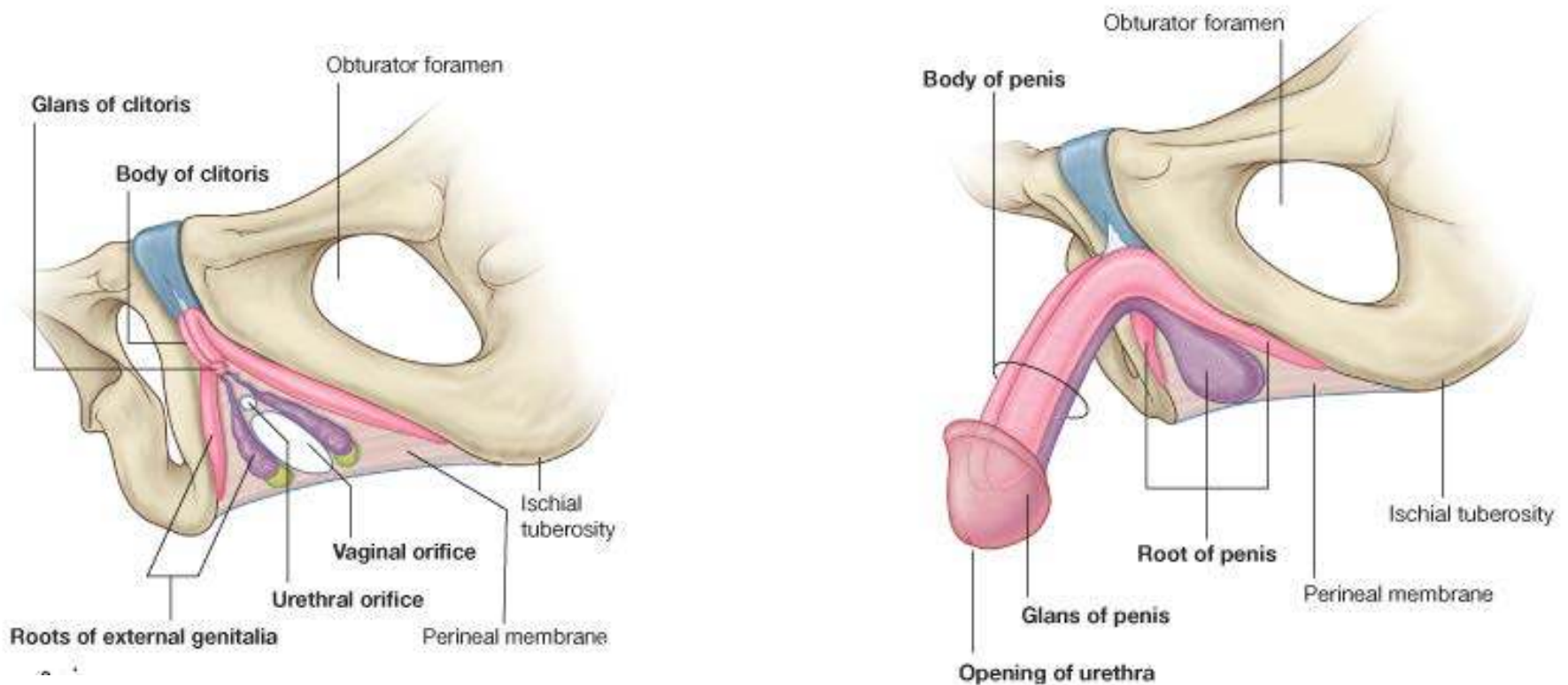
# Perineal membrane

- Thick fascia,
- Triangular
- Attached to the pubic arch
- Has a free posterior margin
- Perforated by the urethra in both sexes
- Perforated by the vagina in females



# Perineal membrane

The perineal membrane and adjacent pubic arch provide attachment for the roots of the external genitalia and their associated muscles



# Perineal body

- An irregular mass, of variable in size and consistency
- Contains connective tissues, skeletal and smooth muscle fibres.
- Located in the central point of the perineum
- Lies just deep to the skin
- Posterior to the vestibule of the penis
- Anterior to the anus and anal canal.

# Perineal body

- The following muscles blend with it:
- Bulbospongiosus.
- External anal sphincter.
- Superficial and deep transverse perineal muscles.
- Smooth and voluntary slips of muscle from the external urethral sphincter, levator ani, and muscular coats of the rectum.



# Fascia of the perineum

- Subcutaneous tissue:
  - Superficial fatty layer: thick in the females over the pubis to form the Mons pubis
  - Membranous layer: which is deeper and fused with the deep fascia at the posterior border of the urogenital triangle
- The deep fascia of the perineum:
  - Is continuous with the fascia over the external oblique muscle
  - Attaches laterally to the ischiopubic rami
  - Invests the muscles in the superficial perineal pouch

# Superficial Perineal Pouch

- Potential space between the membranous layer of subcutaneous tissue and the perineal membrane
- Bounded laterally by the ischiopubic

# Superficial Perineal Pouch

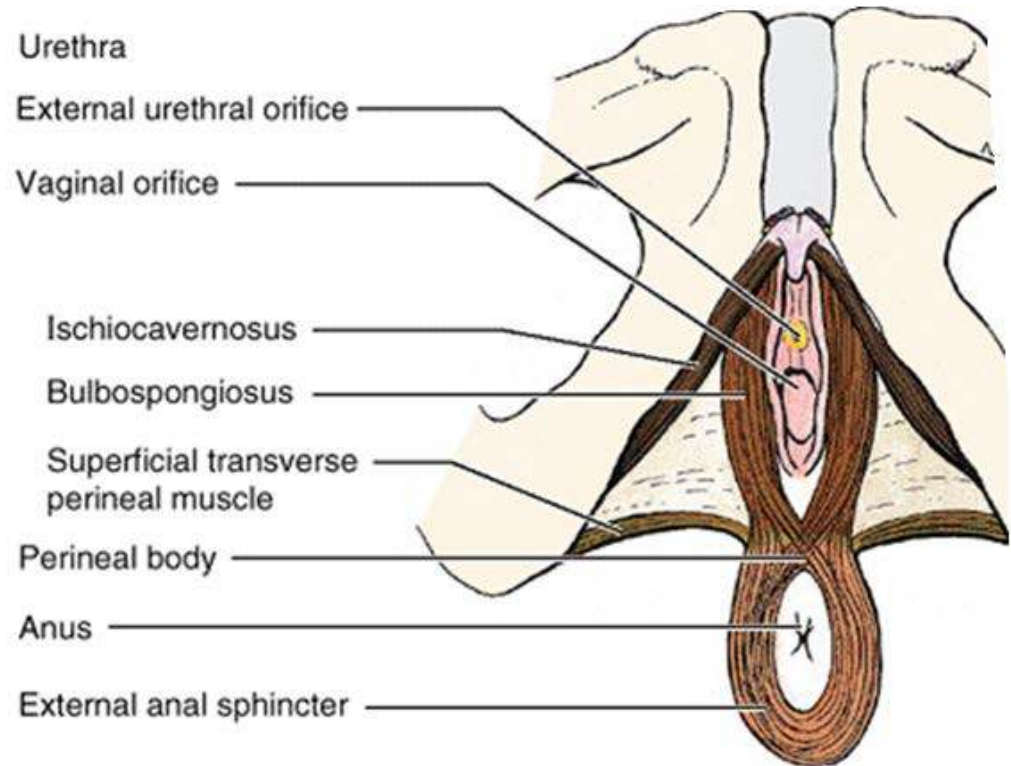
- Contents in the male:
  - i. Root of the penis and associated muscles (ischiocavernosus and bulbospongiosus).
  - ii. Proximal (bulbous) part of the spongy urethra.
  - iii. Superficial transverse perineal muscles.
  - iv. Deep perineal branches of the internal pudendal vessels and pudendal nerves

# Superficial Perineal Pouch

- Contents in the female:
  - i. Clitoris and associated muscles (ischiocavernosus).
  - ii. Bulbs of the vestibule and surrounding muscle (bulbospongiosus).
  - iii. Greater vestibular glands.
  - iv. Superficial transverse perineal muscles.
  - v. Related vessels and nerves (deep perineal branches of the internal pudendal vessels and pudendal nerves).

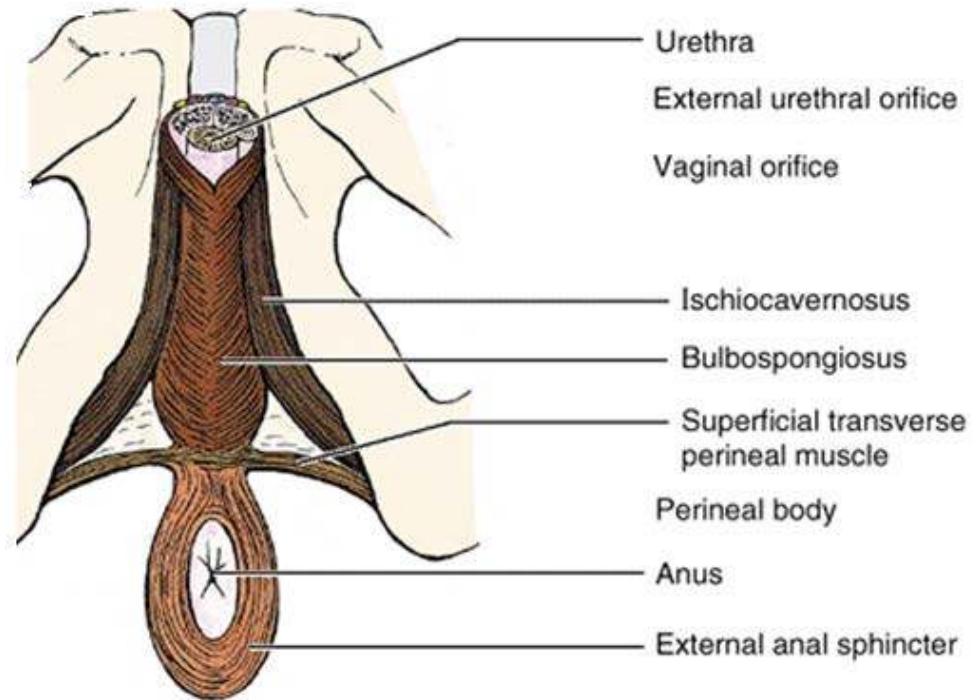
# Muscles of the superficial perineal pouch: External anal sphincter

- **O**: Skin and fascia surrounding anus and the coccyx via the anococcygeal ligament
- **I**: Perineal body
- **A**: Constricts anal canal during peristalsis aiding continence. Also supports the perineal body and pelvic floor
- **N**: Inferior rectal artery (branch of pudendal nerve)



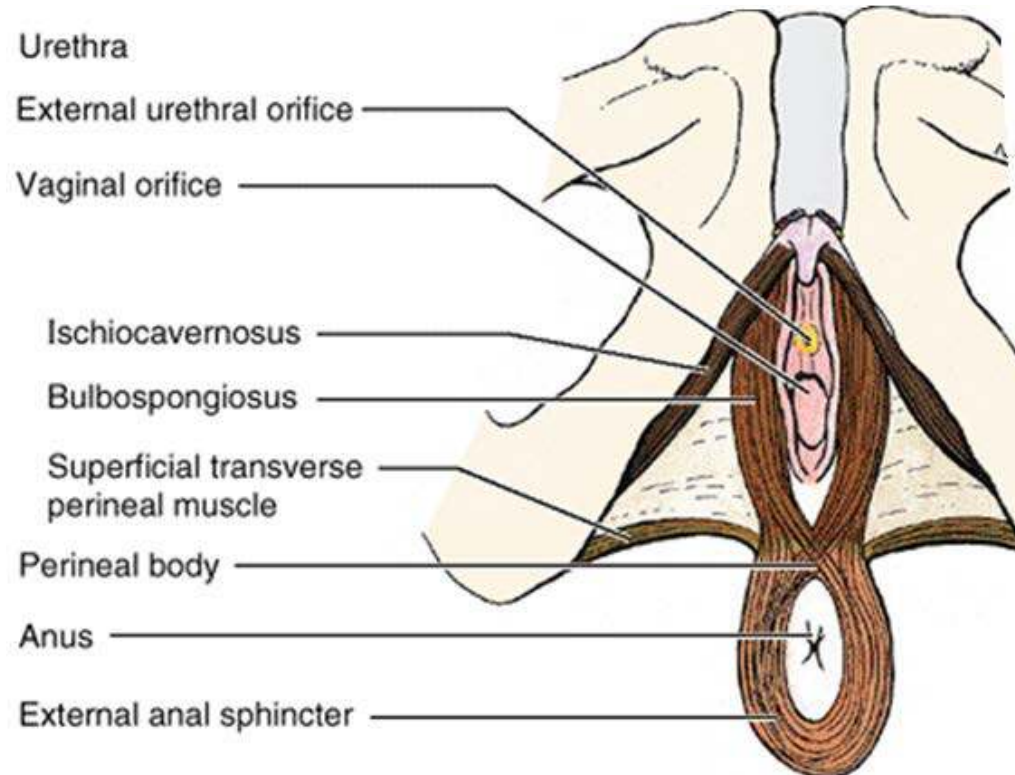
# Muscles of the superficial perineal pouch: Bulbospongiosus (Male)

- **O**: Median raphe on ventral surface of bulb of penis; perineal body
- **I**: Perineal membrane, the dorsal aspect of corpora spongiosum and cavernosa, and fascia of bulb of penis
- **A**: Compresses bulb of penis to expel last drops of urine/semen. Assists erection by compressing outflow via deep perineal vein and by pushing blood from bulb into body of penis
- **N**: Muscular (deep) branch of perineal nerve



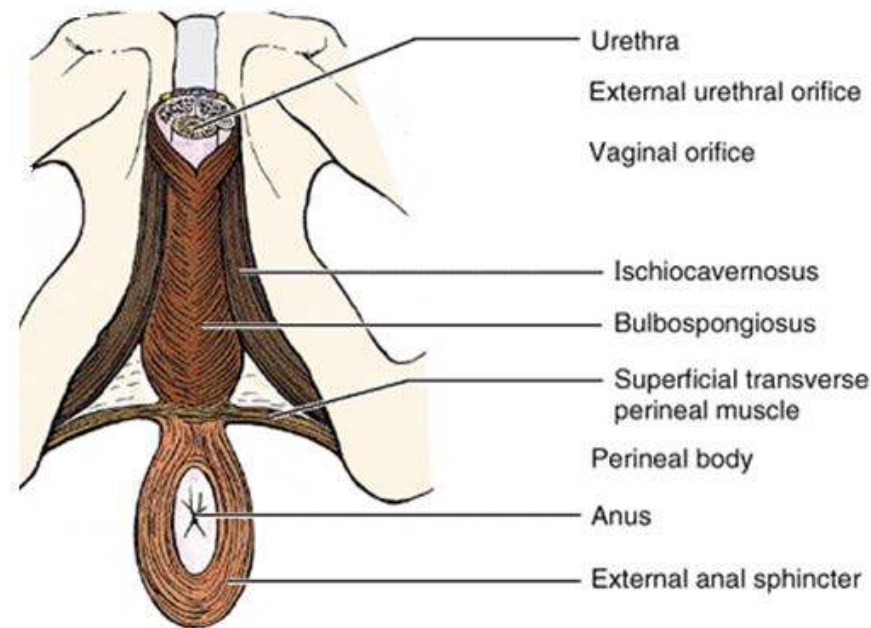
# Muscles of the superficial perineal pouch: Bulbospongiosus (Female)

- **O**: Perineal body
- **I**: Pubic arch and fascia of corpora cavernosa of clitoris
- **A**: Assists in erection of clitoris, compresses greater vestibular gland. Also supports the pelvic floor
- **N**: Muscular (deep) branch of perineal nerve



# Muscles of the superficial perineal pouch: Ischiocavernosus

- **O**: Internal surface of ischiopubic ramus and ischial tuberosity
- **I**: Inferior and medial aspects of crus and the perineal membrane
- **A**: Maintains erection of penis or clitoris by compressing outflow veins and pushing blood from the root of penis or clitoris into the body of penis or clitoris
- **N**: Muscular (deep) branch of perineal nerve

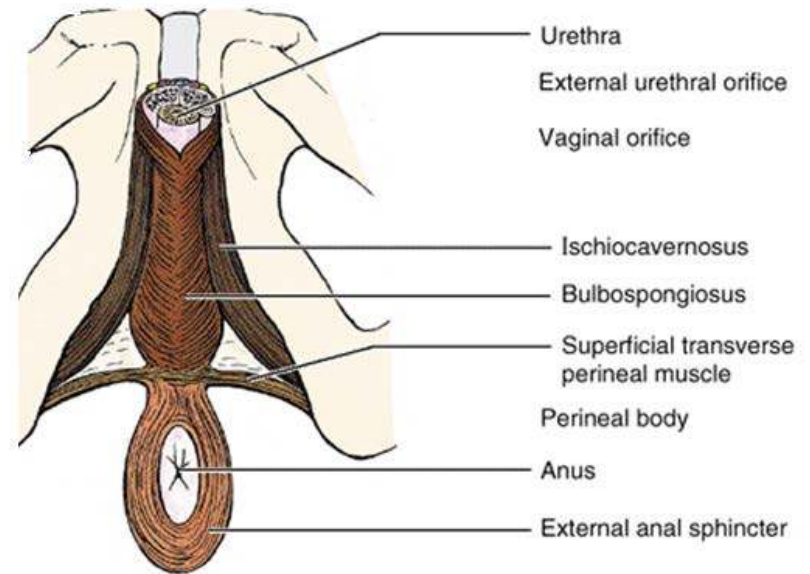




# Muscles of the superficial perineal pouch:

## Superficial transverse perineal muscle

- **O**: Internal surface of ischiopubic ramus and ischial tuberosity
- **I**: Perineal body
- **A**: Supports and fixes perineal body and pelvic floor to support abdominopelvic viscera and resist increased intra-abdominal pressure
- **N**: Muscular (deep) branch of perineal nerve

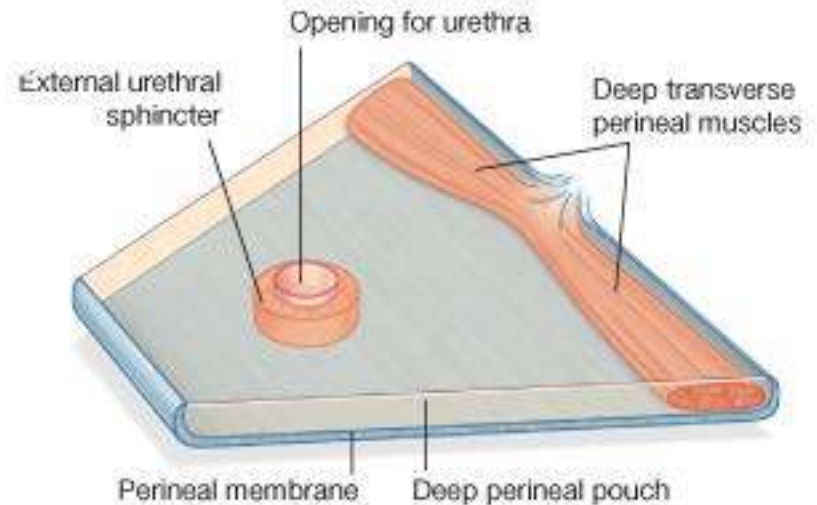


# Deep Perineal Pouch

- Bounded:
  - Inferiorly: perineal membrane
  - Superiorly: pelvic diaphragm
  - Laterally: fascia covering the obturator internus muscle
- It includes the anterior recesses of the ischioanal fossa.

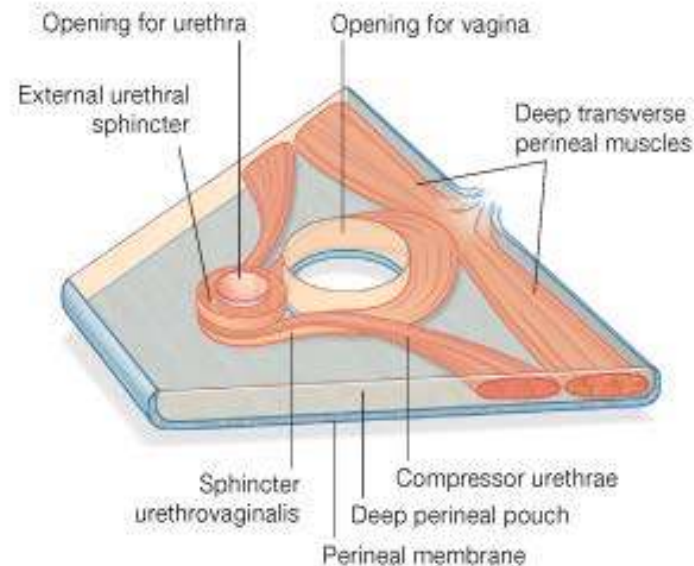
# Deep Perineal Pouch

- In males, the deep perineal pouch contains the:
  - i. Membranous urethra, the narrowest part of the male urethra.
  - ii. Deep transverse perineal muscles, running transversely along the posterior aspect of the perineal membrane.
  - iii. Bulbourethral glands
  - iv. Dorsal neurovascular structures of the penis.

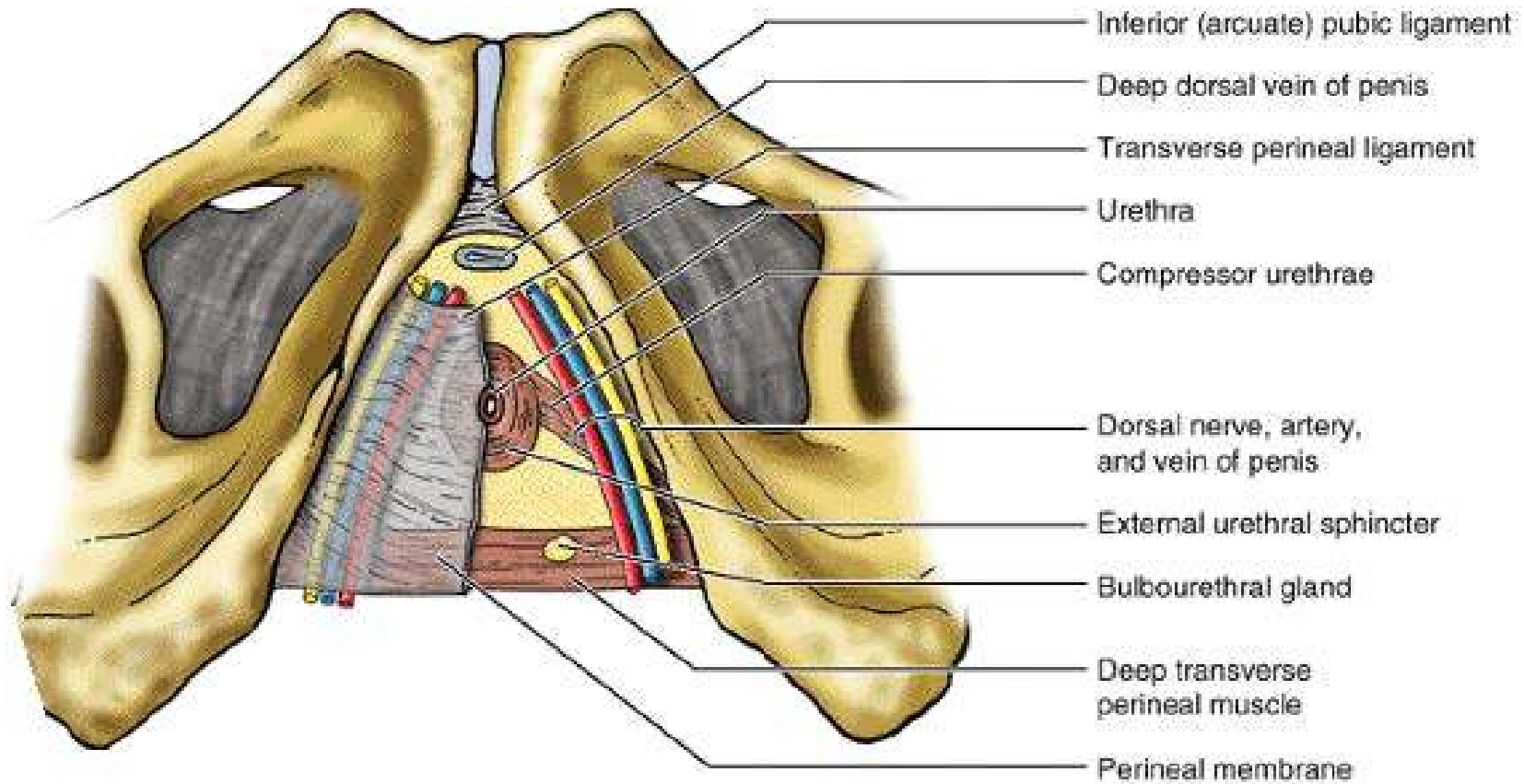


# Deep Perineal Pouch

- In females, the deep perineal pouch contains the:
  - i. Proximal part of the urethra.
  - ii. External urethral sphincter
  - iii. Two accessory muscles for urethra closure: the sphincter urethrovaginalis and which surrounds the urethra and vagina as a unit, and the compressor urethrae
  - iv. Deep transverse perineal muscle
  - v. Dorsal neurovasculature of the clitoris.



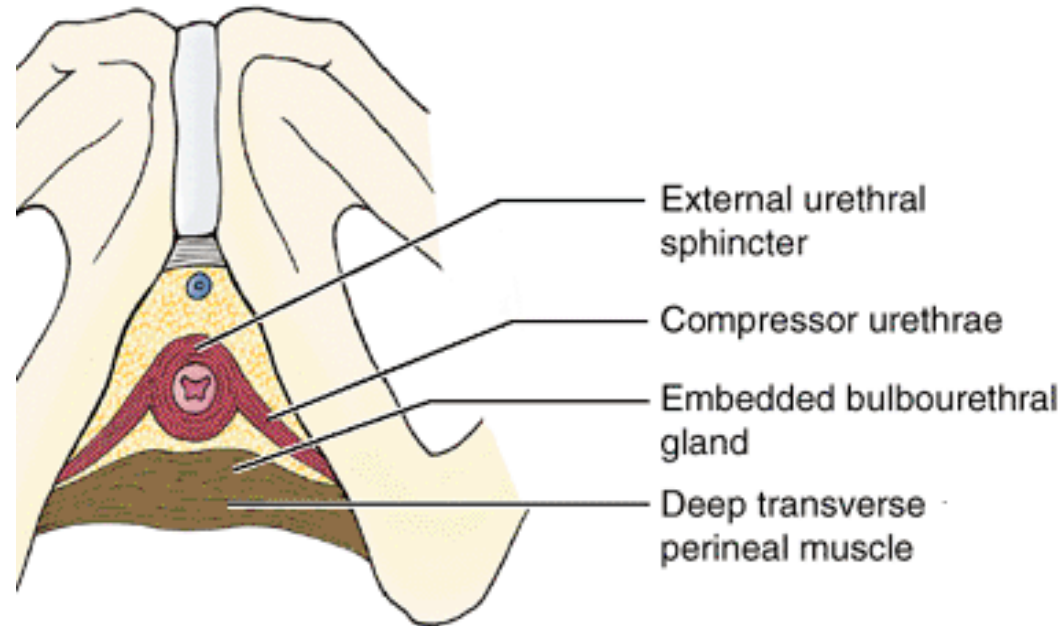
# Deep Perineal Pouch: contents



# Muscles of the deep perineal pouch:

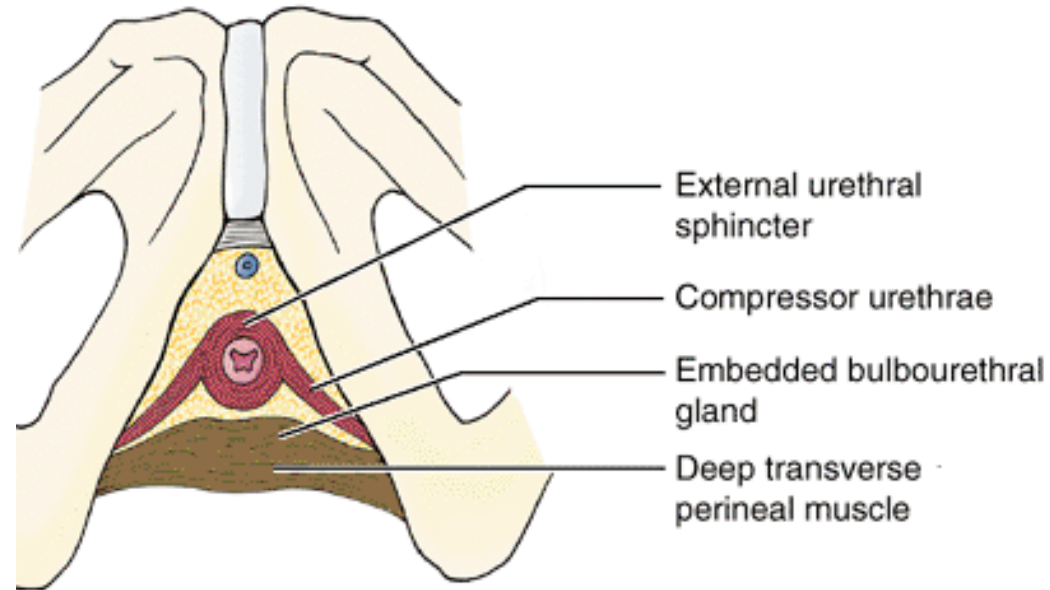
## Deep transverse perineal muscle

- **O**: Internal surface of ischiopubic ramus and ischial tuberosity
- **I**: Perineal body and external anal sphincter
- **A**: Supports and fixes perineal body and pelvic floor to support abdominopelvic viscera and resist increased intra-abdominal pressure
- **N**: Muscular (deep) branch of perineal nerve



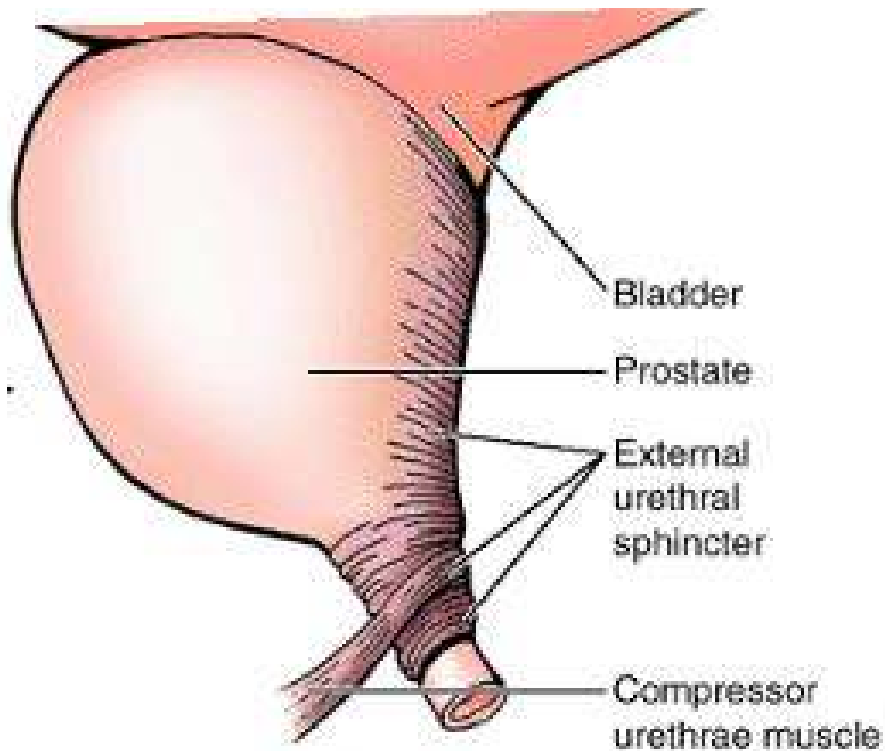
# Muscles of the deep perineal pouch: External urethra sphincter

- **O**: Internal surface of ischiopubic ramus and ischial tuberosity
- **I**: surrounds the urethra
- **A**: Compresses urethra to maintain urinary continence
- **N**: Dorsal nerve of penis or clitoris

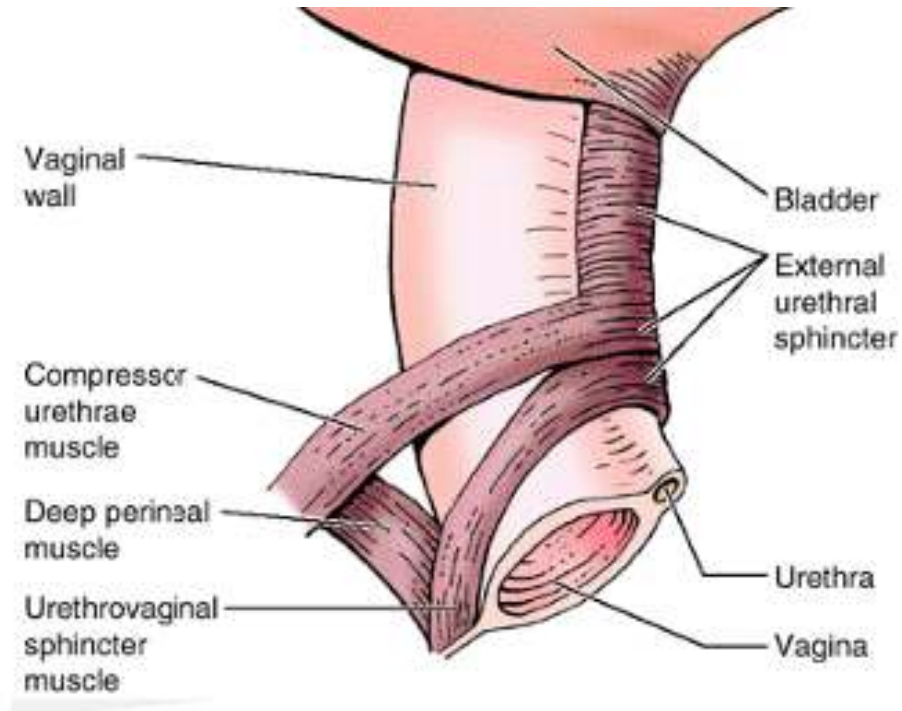


# Deep Perineal Pouch: Sphincters around the urethra

Male



Female



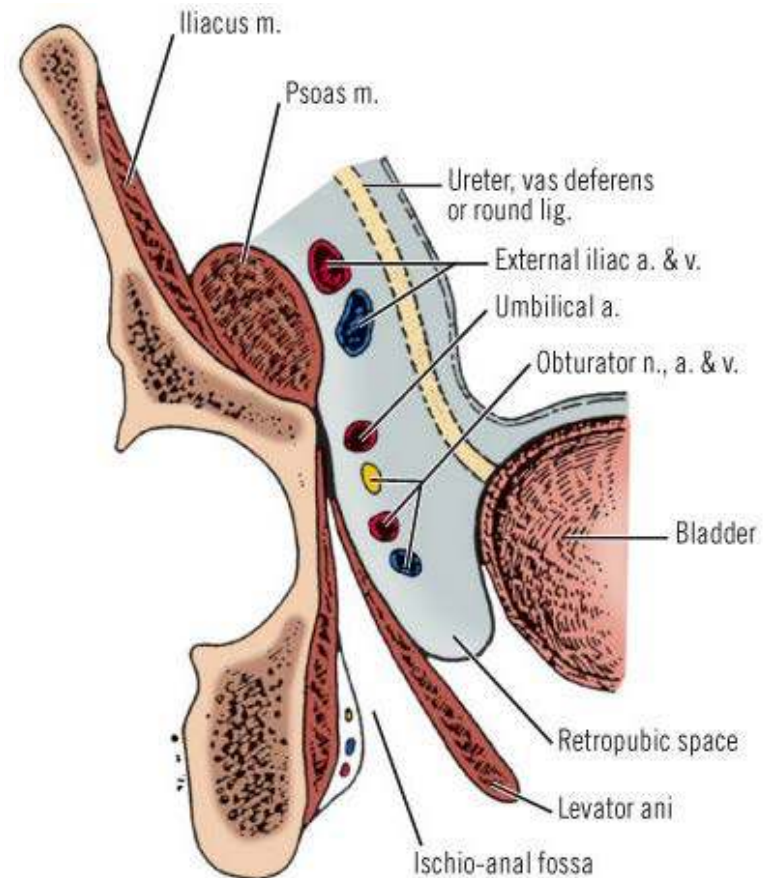


# The Anal Triangle

- This is the part of the perineum posterior to the urogenital triangle
- Major constituent :
  - i. Anus
  - ii. Anal canal and the
  - iii. Paired ischioanal fossae which contains fat

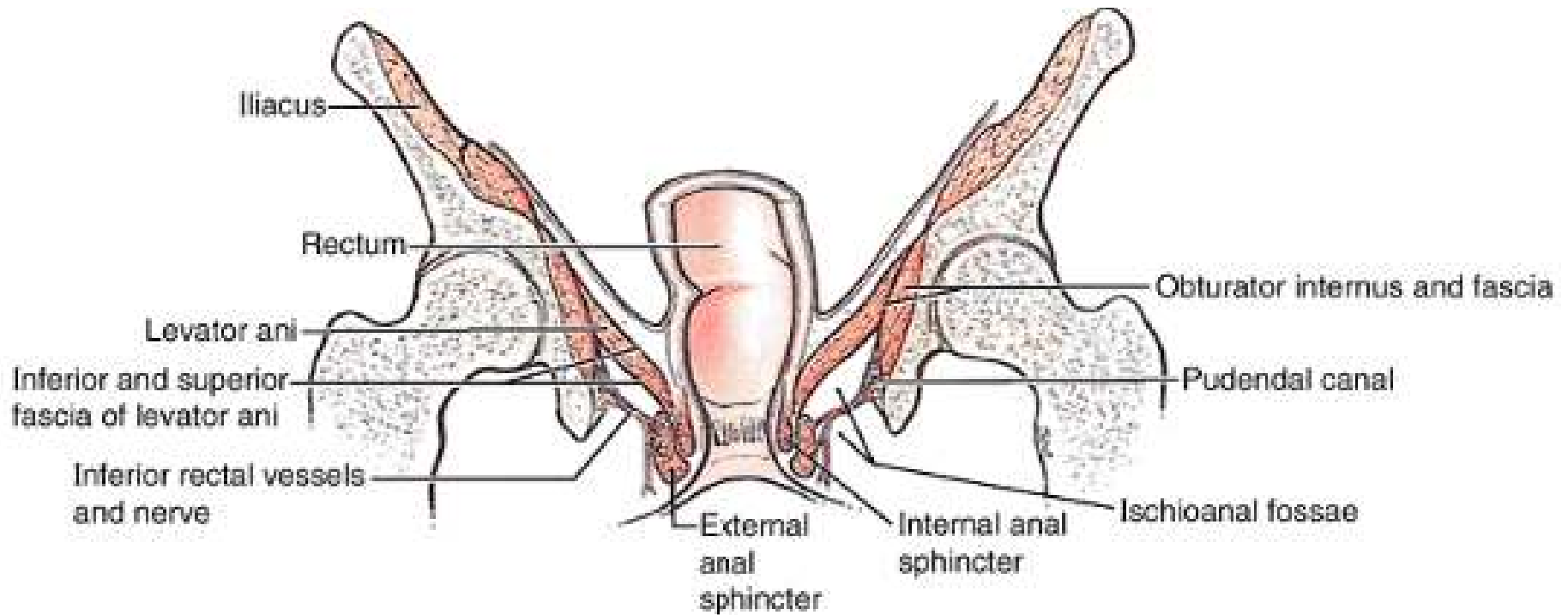
# Ischioanal fossa

- Pyramid shaped
- The apex points superiorly between the levator ani and obturator internus muscles
- The base of the pyramid faces inferiorly and is formed by the skin of the perineum
- Medial wall: Levator ani
- Lateral wall: obturator internus
- The two on either side are separated by the midline raphe and anus



Copyright ©2006 by The McGraw-Hill Companies, Inc.  
All rights reserved.

# Ischioanal fossa



# Ischioanal fossa

- There are two recesses
  - i. Anterior recess which extends into the deep perineal pouch
  - ii. A posterior recess which extends posterolaterally beneath the sacrotuberous and the anococcygeal ligament
- The two spaces communicate posteriorly through the retrosphincteric space

# Ischioanal fossa

- Filled fat which supports the anal canal but are readily displaced to permit descent and expansion of the anal canal during the passage of feces.
- Traversed the inferior anal/rectal vessels and nerves, the perforating branch of S2 and S3; and the perineal branch of S4 nerve.

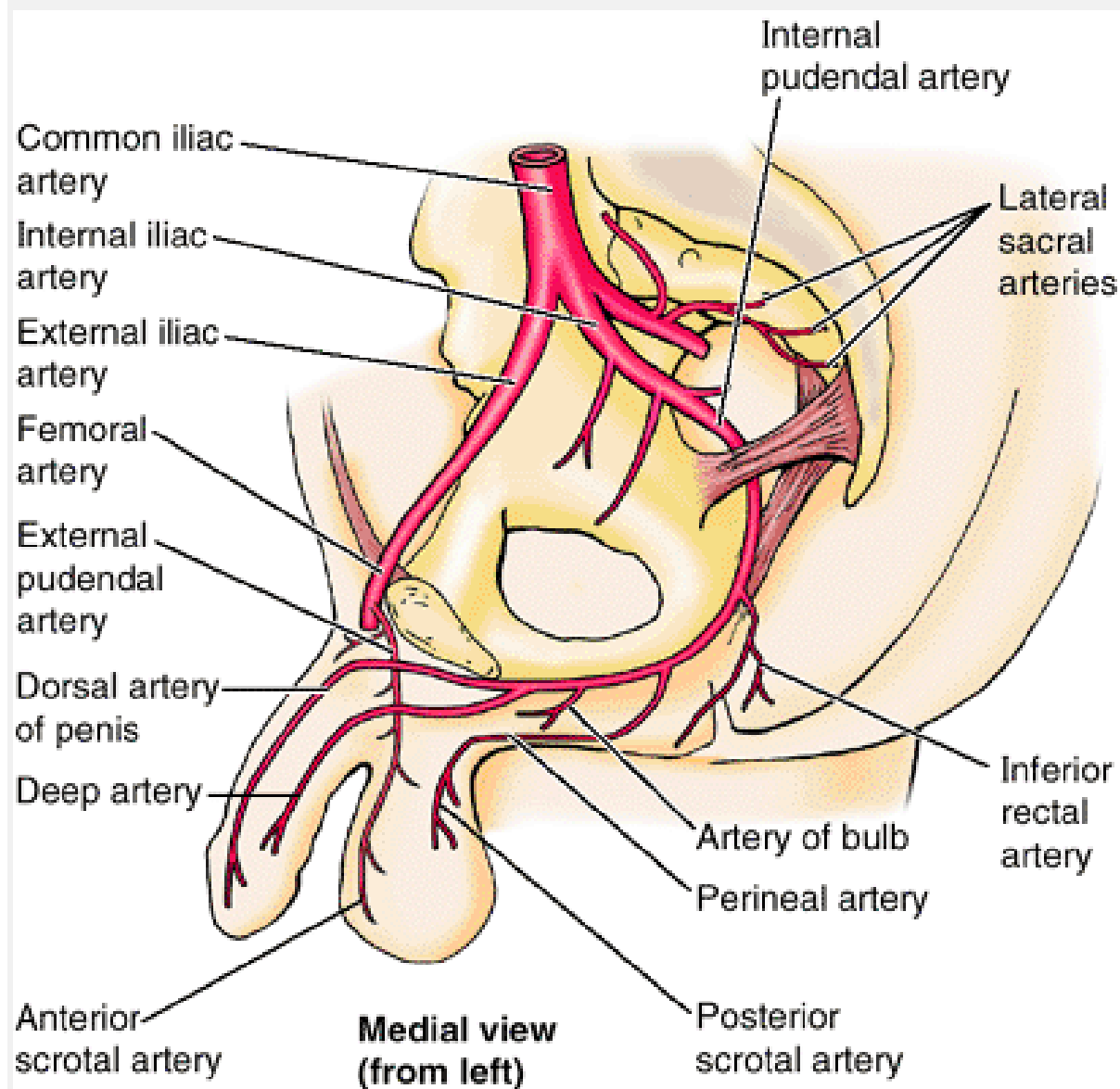
# Pudendal Canal

- Synonym: Alcock canal
- On the lateral wall of the ischioanal fossa within the obturator fascia that covers the obturator internus.
- Contains four structures which enter it at the lesser sciatic notch:
  - i. Internal pudendal artery
  - ii. Internal pudendal vein
  - iii. Pudendal nerve
  - iv. Nerve to the obturator internus

# Pudendal Canal: Vessels and nerves

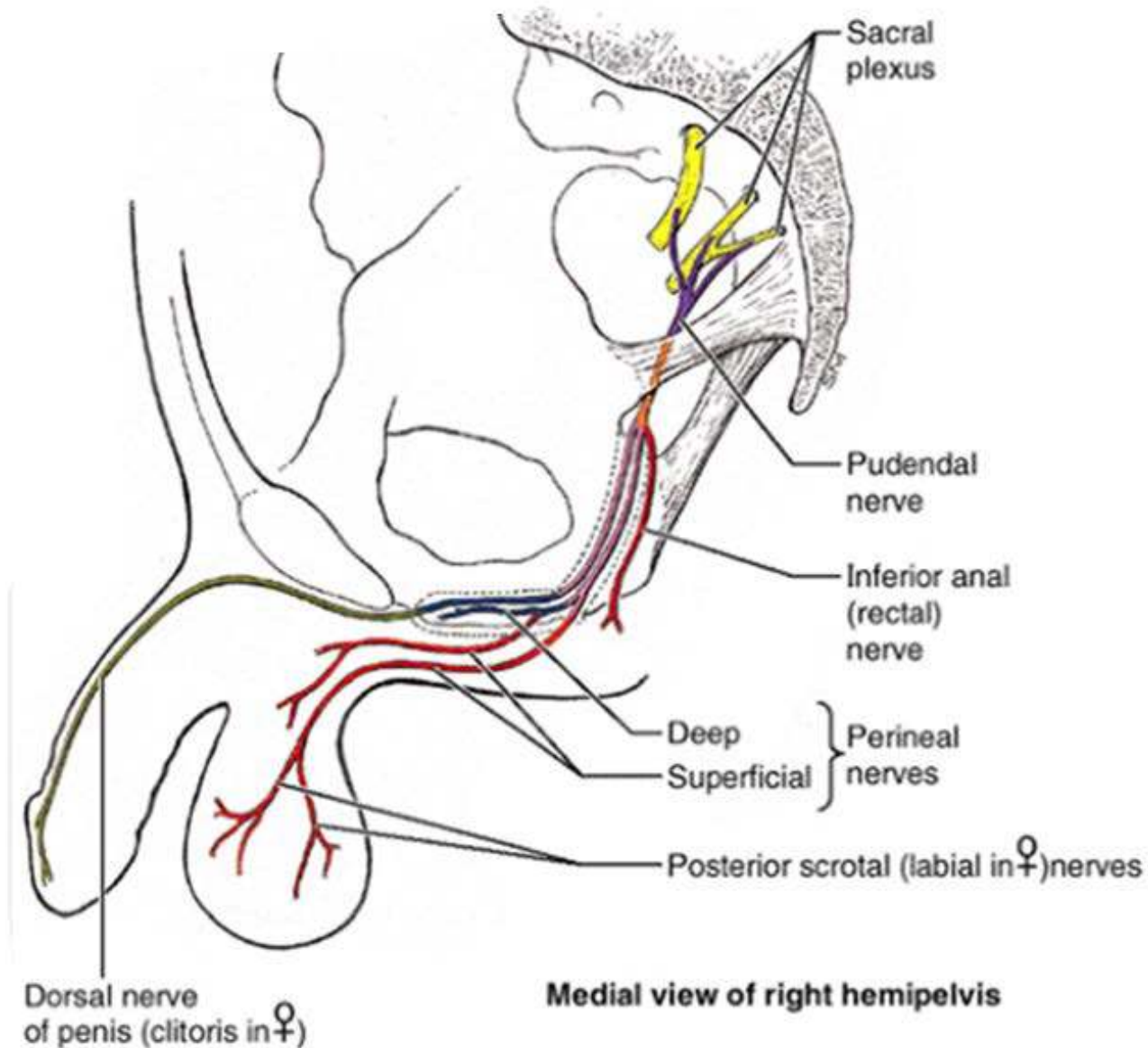
- The internal pudendal vessels and the pudendal nerve serves most of the perineum.
- Branches in the canal:
  - Proximal part of the canal: Inferior rectal artery and nerve, which pass medially to supply the external anal sphincter and the perianal skin
  - Distal (anterior) end of the pudendal canal: Bifurcates into:
    - Perineal nerve and artery, which are distributed mostly to the superficial pouch
    - Dorsal artery and nerve of the penis or clitoris, which run in (but does not supply) the deep perineal pouch. They are the primary sensory nerve serving the penis and the clitoris, especially the sensitive glans

# Pudendal Canal: Vessels and nerves





# Pudendal Canal: Vessels and nerves



# The perineal nerve

- Has two branches:
  - Superficial perineal nerves give rise to posterior scrotal or labial (cutaneous) branches
  - Deep perineal nerve which supplies the muscles of the deep and superficial perineal pouches, the skin of the vestibule, and the mucosa of the distal part of the vagina.



PLEASE JOIN THE FORUM AT  
[WWW.OLUWADIYA.COM](http://WWW.OLUWADIYA.COM) TO ASK  
QUESTIONS

**THE END**