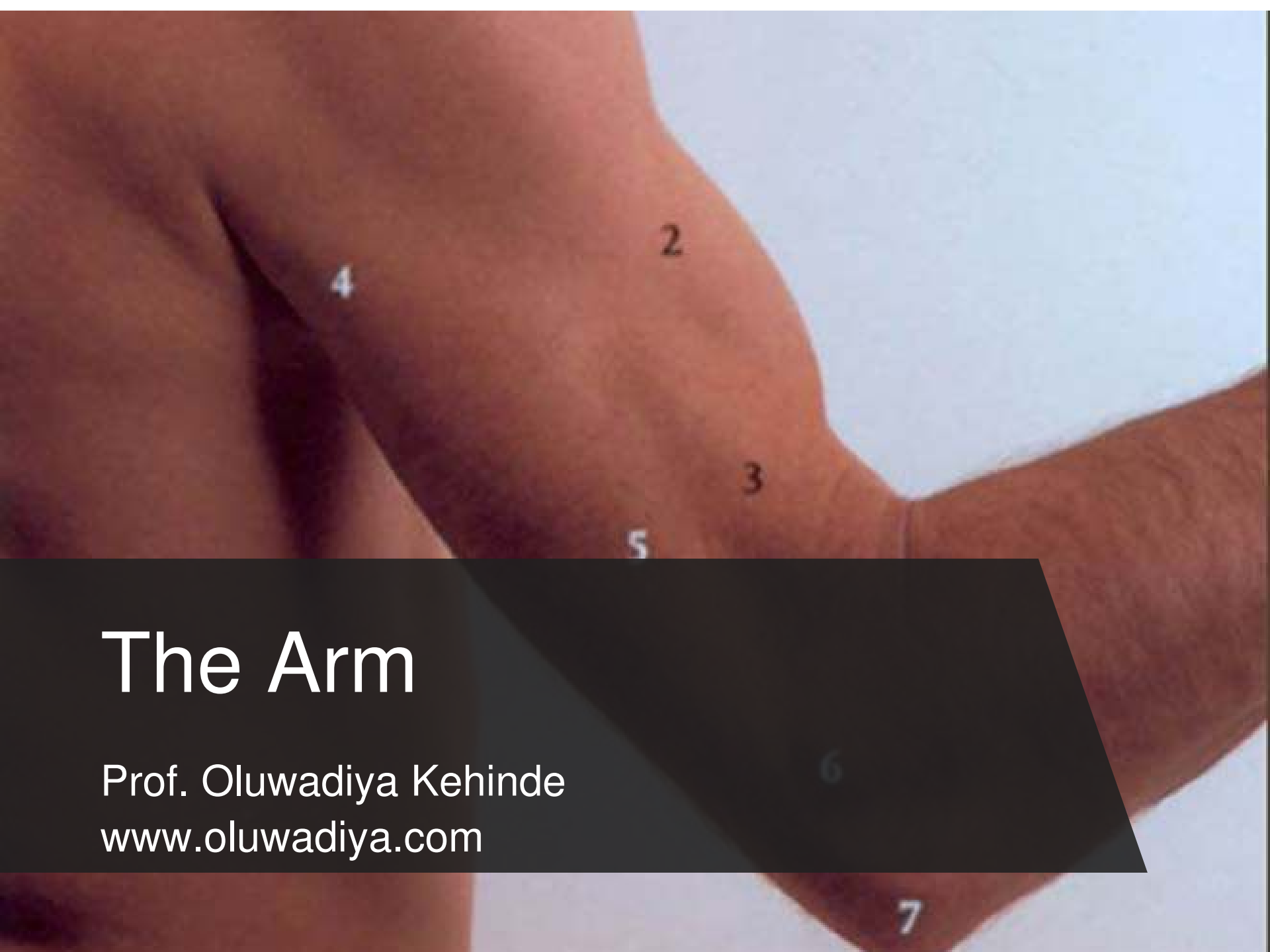

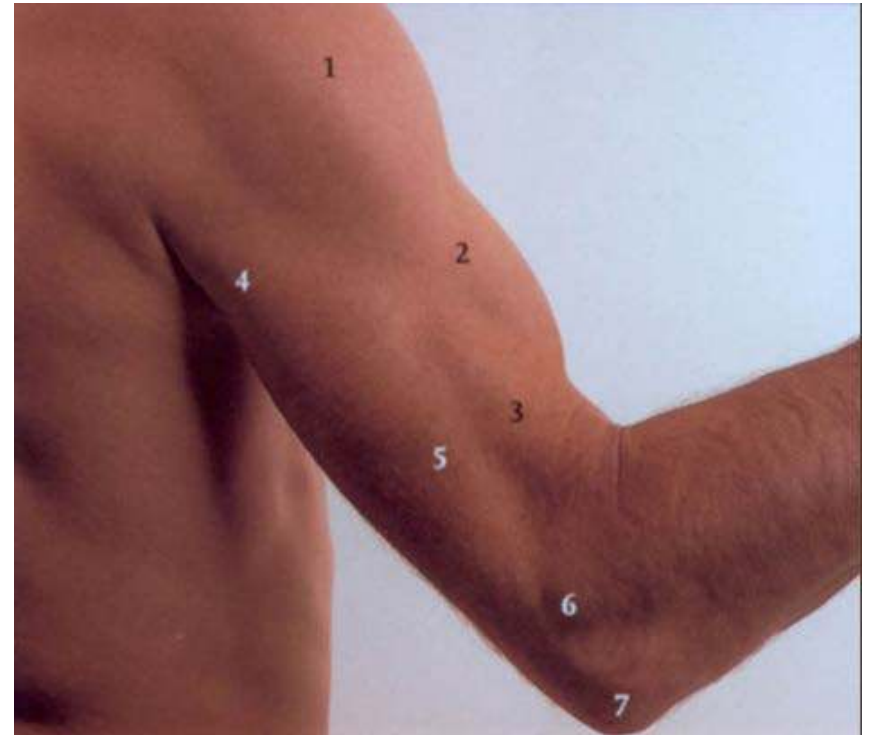


# The Arm

Prof. Oluwadiya Kehinde  
[www.oluwadiya.com](http://www.oluwadiya.com)

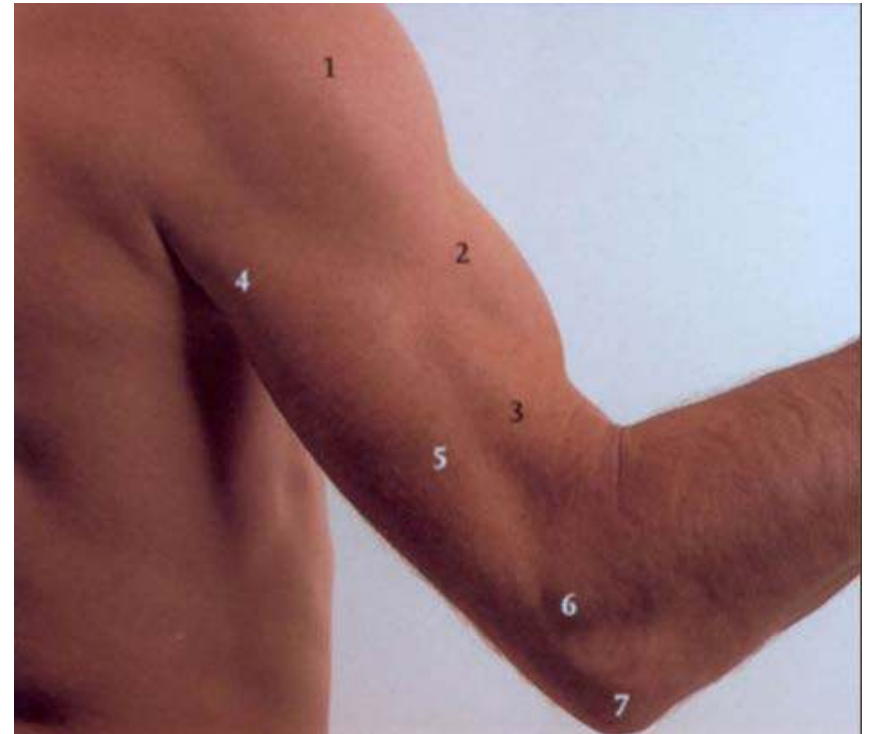
# Where is the arm?

- Region of the upper limb between the shoulder and the elbow

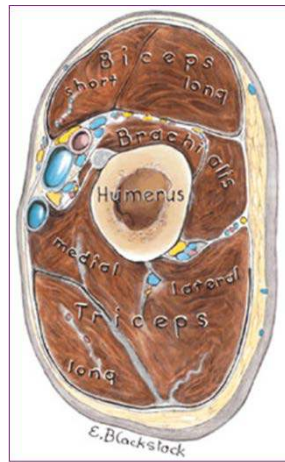


# Surface Anatomy

1. Deltoid
2. Biceps
3. Brachialis
4. Triceps: Lateral and Long Head
5. Triceps: Medial Head
6. Epicondyle of the humerus
7. Olecranium



# Layout

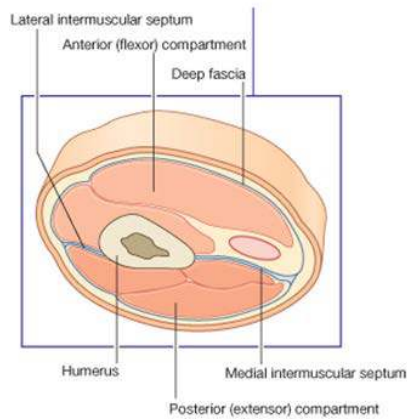


## 2 Septa:

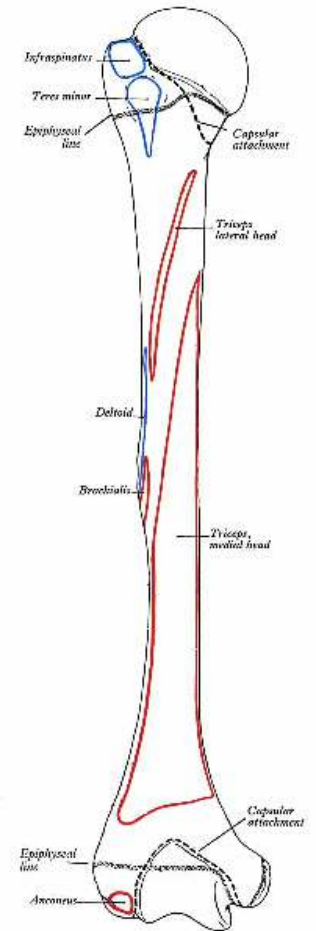
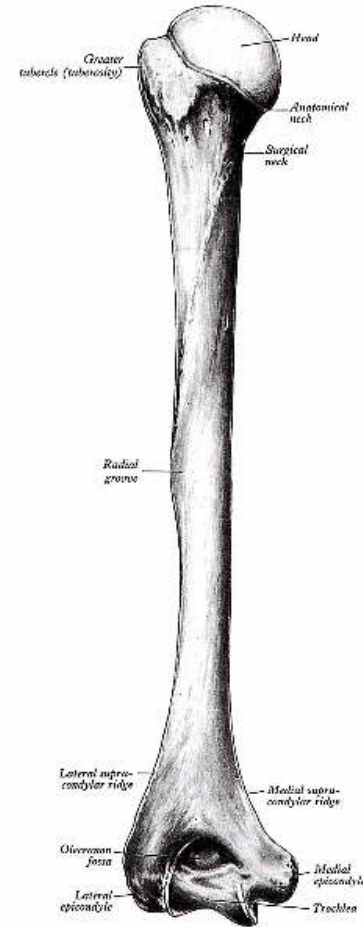
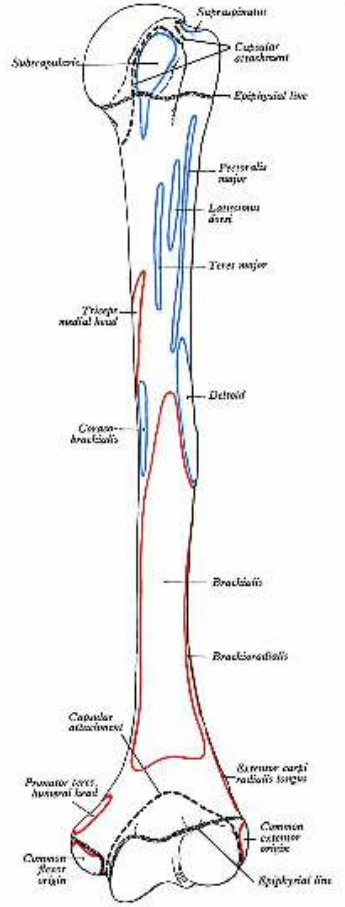
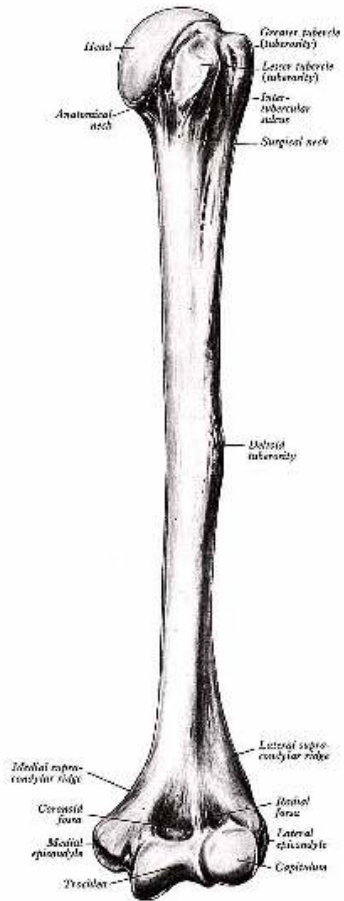
- Medial
- Lateral

## 2 Compartments:

- Anterior
- Posterior



# Humerus



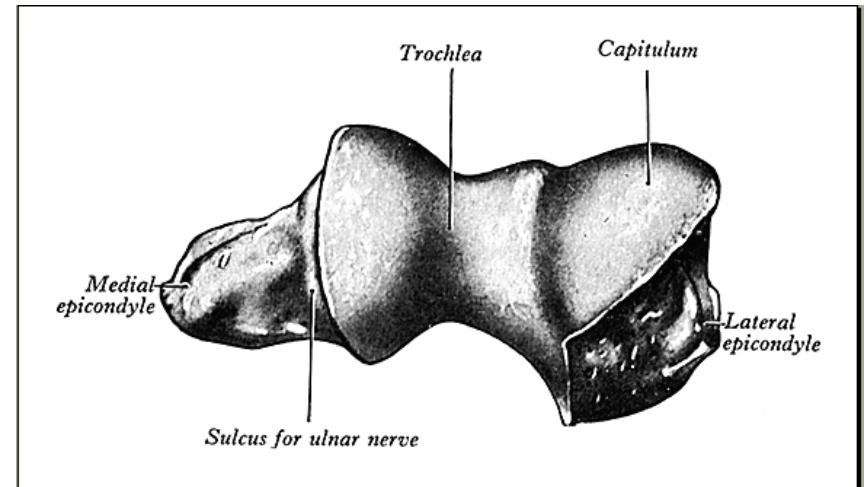
**ANTERIOR**

**POSTERIOR**

# Humerus: Lower end

## Note:

- The Trochlear
- The Capitulum
- The medial epicondyle
- The lateral epicondyle



# Muscles

## Four muscles

- 3 in the anterior compartment:
  - i. Coracobrachialis
  - ii. Biceps Brachii
  - iii. Brachialis
- 1 in the posterior compartment
  - i. Triceps brachii

# Triceps

**O:** **Long head:** infraglenoid tubercle of scapula

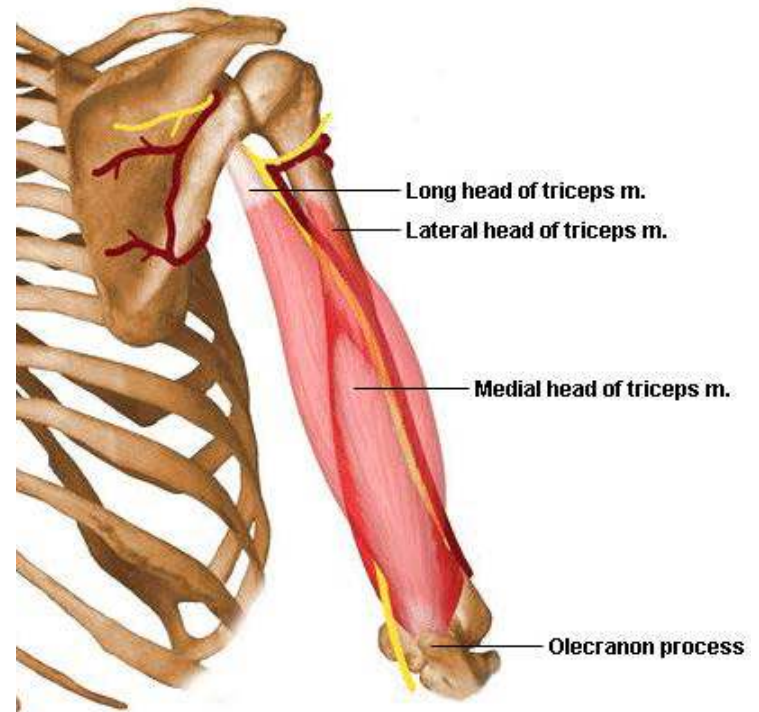
**Lateral head:** posterior surface of humerus, superior to radial groove

**Medial head:** posterior surface of humerus, inferior to radial groove

**I:** Proximal end of olecranon process of ulna and fascia of forearm

**A:** Chief extensor of forearm; long head steadies head of abducted humerus

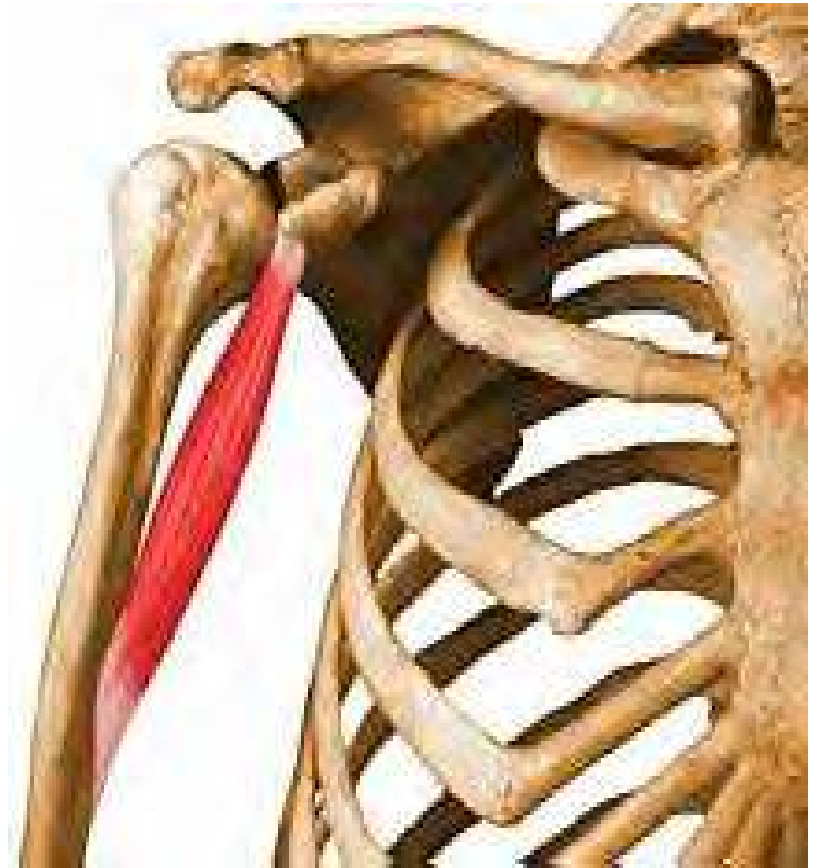**N:** Radial Nerve





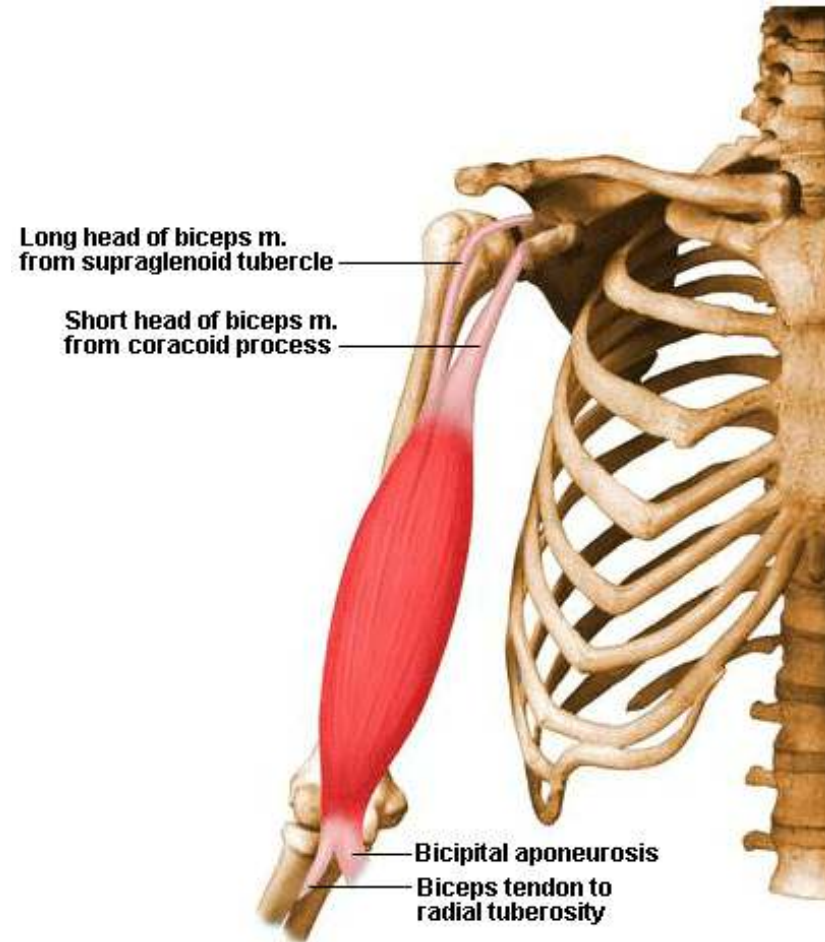
# Coracobrachialis

- O:** Tip of coracoid process of scapula
- I:** Middle third of medial surface of humerus
- A:** Helps to flex and adduct arm
- N:** Musculocutaneous nerve



# Biceps Brachii

- O:** **Short head:** tip of coracoid process of scapula  
**Long head:** supraglenoid tubercle of scapula
- I:** Tuberosity of radius and fascia of forearm via bicipital aponeurosis
- A:** Supinates forearm and, when it is supine, flexes forearm
- N:** Musculocutaneous nerve



# Brachialis

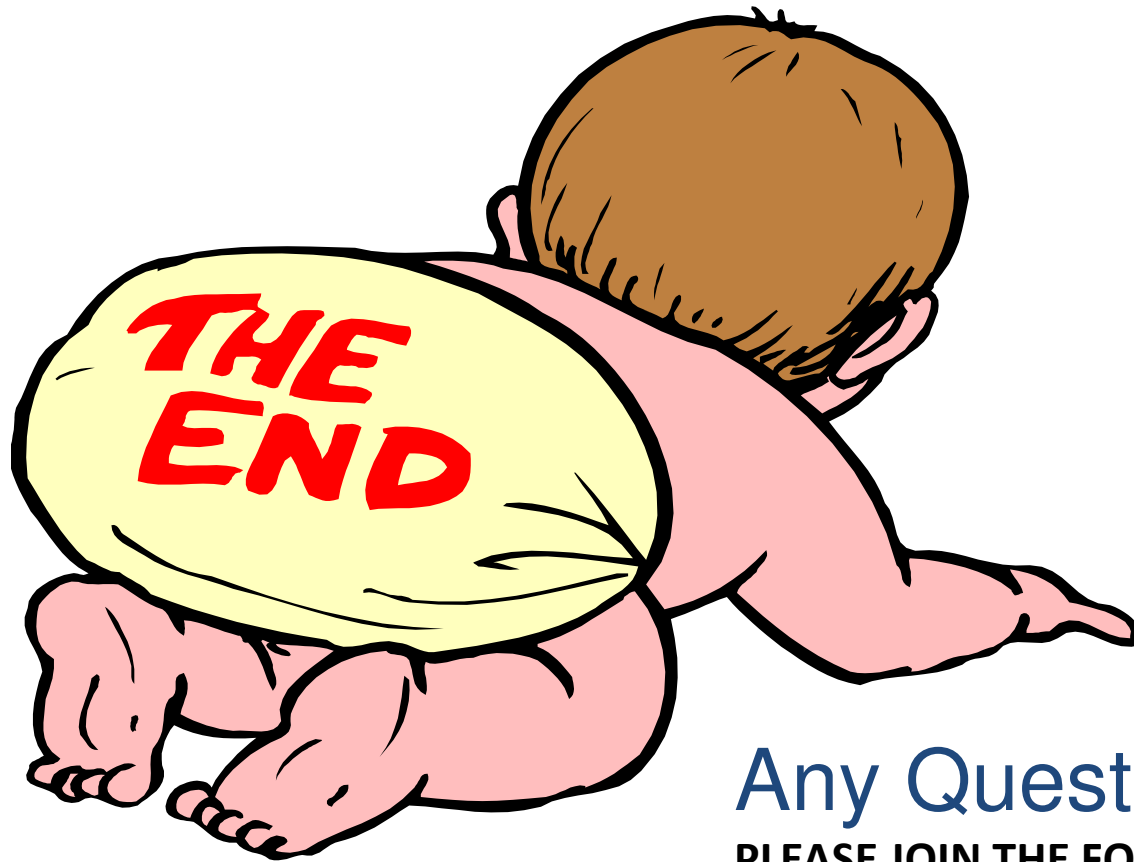- O**: Anterior surface of the humerus
- I**: Ulna tuberosity
- A**: Flexes the forearm
- N**: Musculocutaneous nerve



# Nerves

The nerves passing through the arms are:

- Radial nerve
- Musculocutaneous
- Ulna Nerve
- Median Nerve



Any Question?

PLEASE JOIN THE FORUM AT

[WWW.OLUWADIYA.COM](http://WWW.OLUWADIYA.COM) TO

ASK QUESTIONS